


*Prof. M. Kaposi*

*Handatlas*  
*der*  
**HAUTKRANKHEITEN**  
*für Studierende und Aerzte*

*II. Abtheilung. I-M*  
*(Ichthyosis-Myomata cutis)*





22500913633









HANDATLAS  
DER  
HAUTKRANKHEITEN.

II. ABTHEILUNG.

---





Digitized by the Internet Archive  
in 2015

[https://archive.org/details/b20413221\\_002](https://archive.org/details/b20413221_002)



HANDATLAS  
DER  
HAUTKRANKHEITEN

FÜR  
STUDIRENDE UND ÄRZTE

VON  
PROFESSOR M. KAPOSI

---

II. ABTHEILUNG. I—M.  
(ICHTHYOSIS — MYOMATA CUTIS.)

ENTHALTEND 126 CHROMOTAFELN.



WIEN UND LEIPZIG  
WILHELM BRAUMÜLLER

K. U. K. HOF- UND UNIVERSITÄTS-BUCHHÄNDLER.

1899.



M19974

WELLCOME INSTITUTE	
MEDICAL	
Coll	W. 1000 m.c
Call	
No.	WR 11
	1898
	KITH

II. ABTHEILUNG.

ICHTHYOSIS — MYOMATA CUTIS.

---

(DAS GENAUE TAFEL-VERZEICHNIS BEFINDET SICH AM SCHLUSSE DER  
III. ABTHEILUNG.)



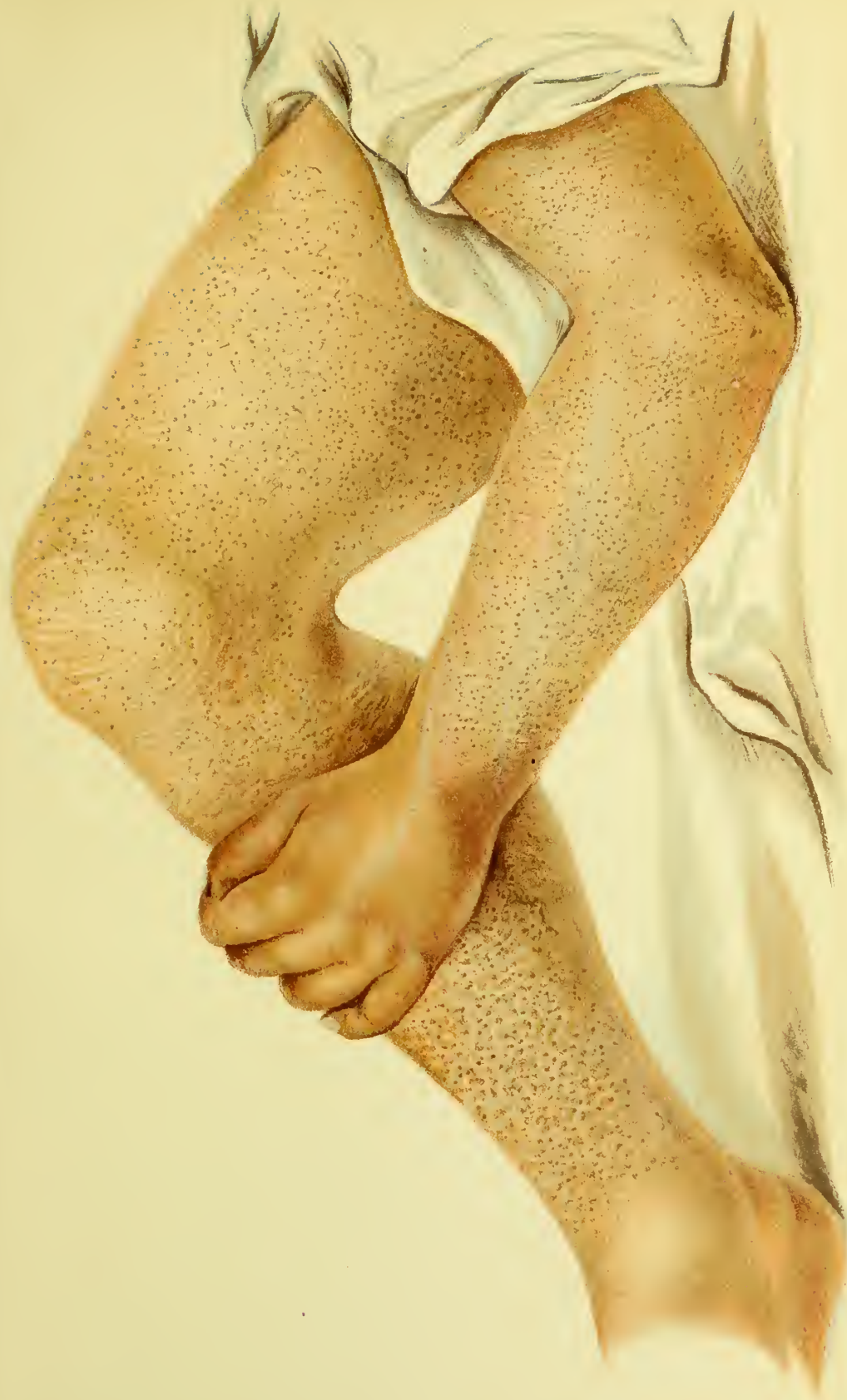

TAFEL 115.

Ichthyosis serpentina et pilaris (Lichen pilaris).







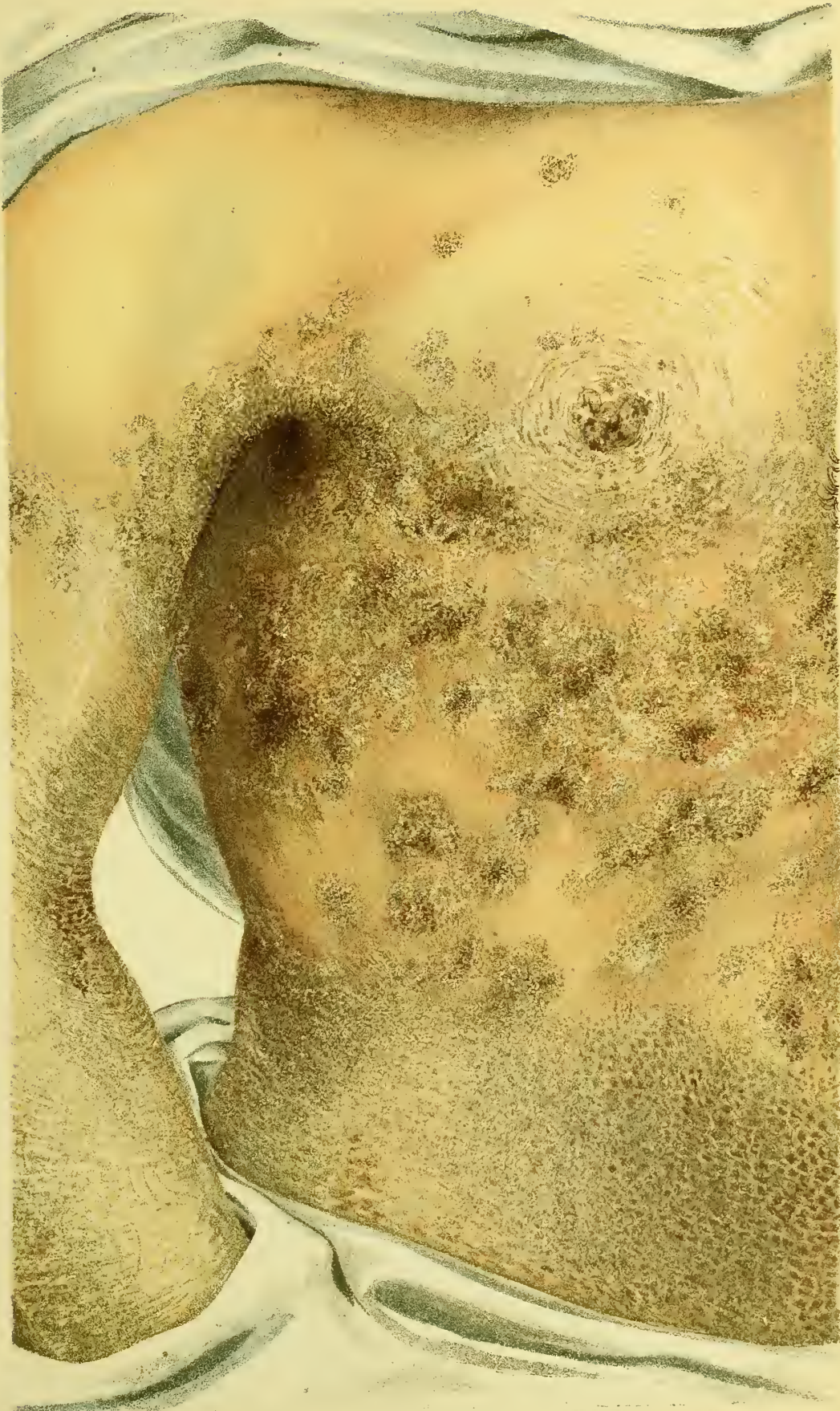



TAFEL 116.

*Ichthyosis serpentina s. nitida.*



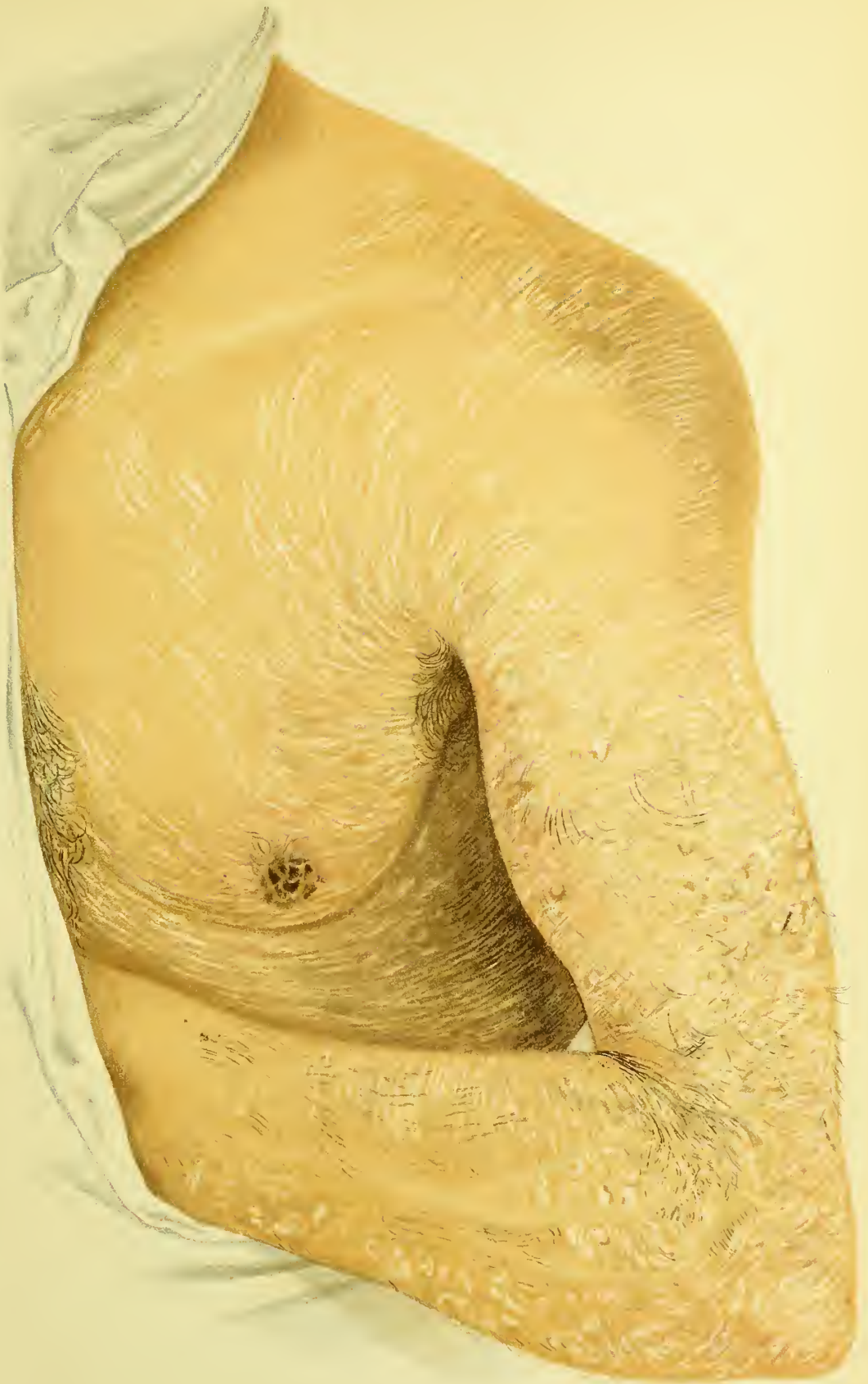






TAFEL 117.  
Ichthyosis serpentina.





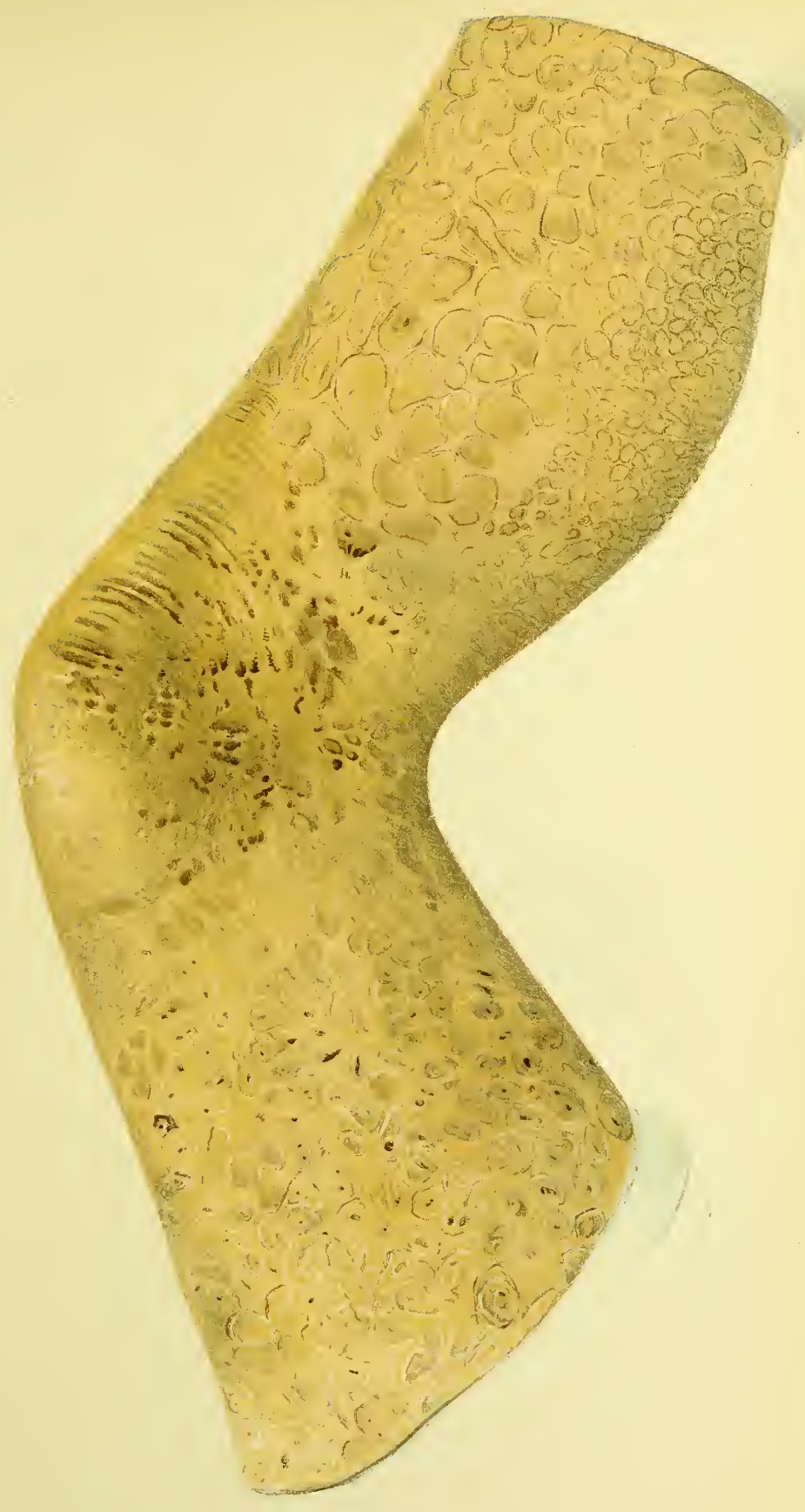



TAFEL 118.

**Ichthyosis.**









TAFEL 119.

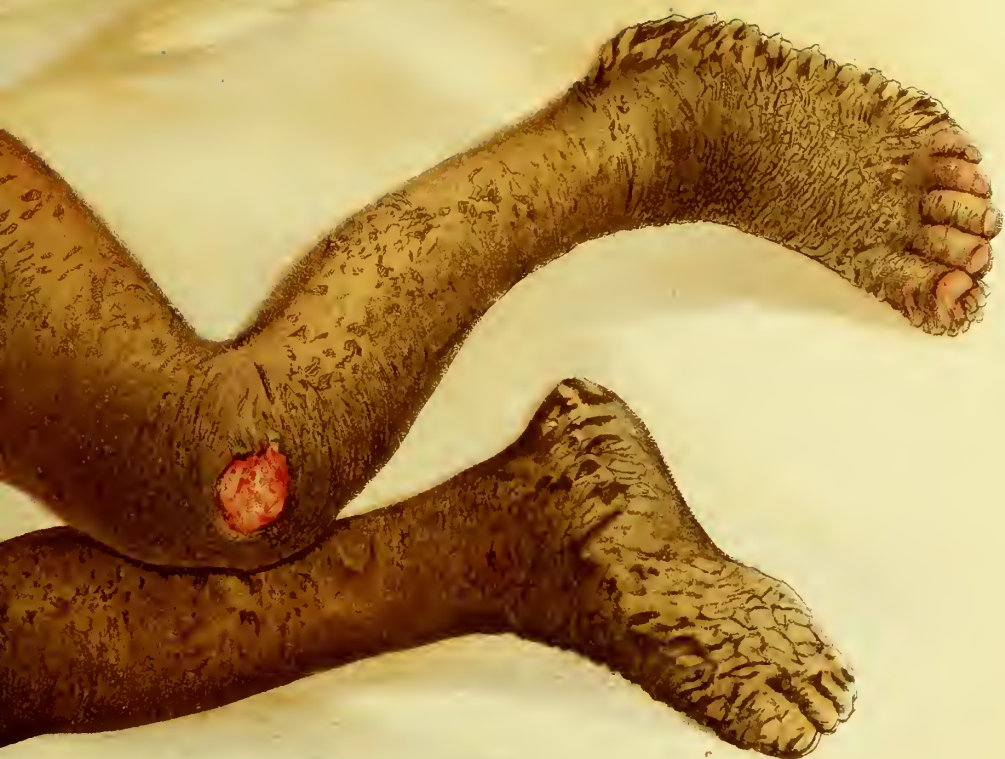Ichthyosis serpentina, verrucosa et tyloica.













TAFEL 120.

Ichthyosis hystrix — porcupine man. — Stachelschwein-  
mensch.







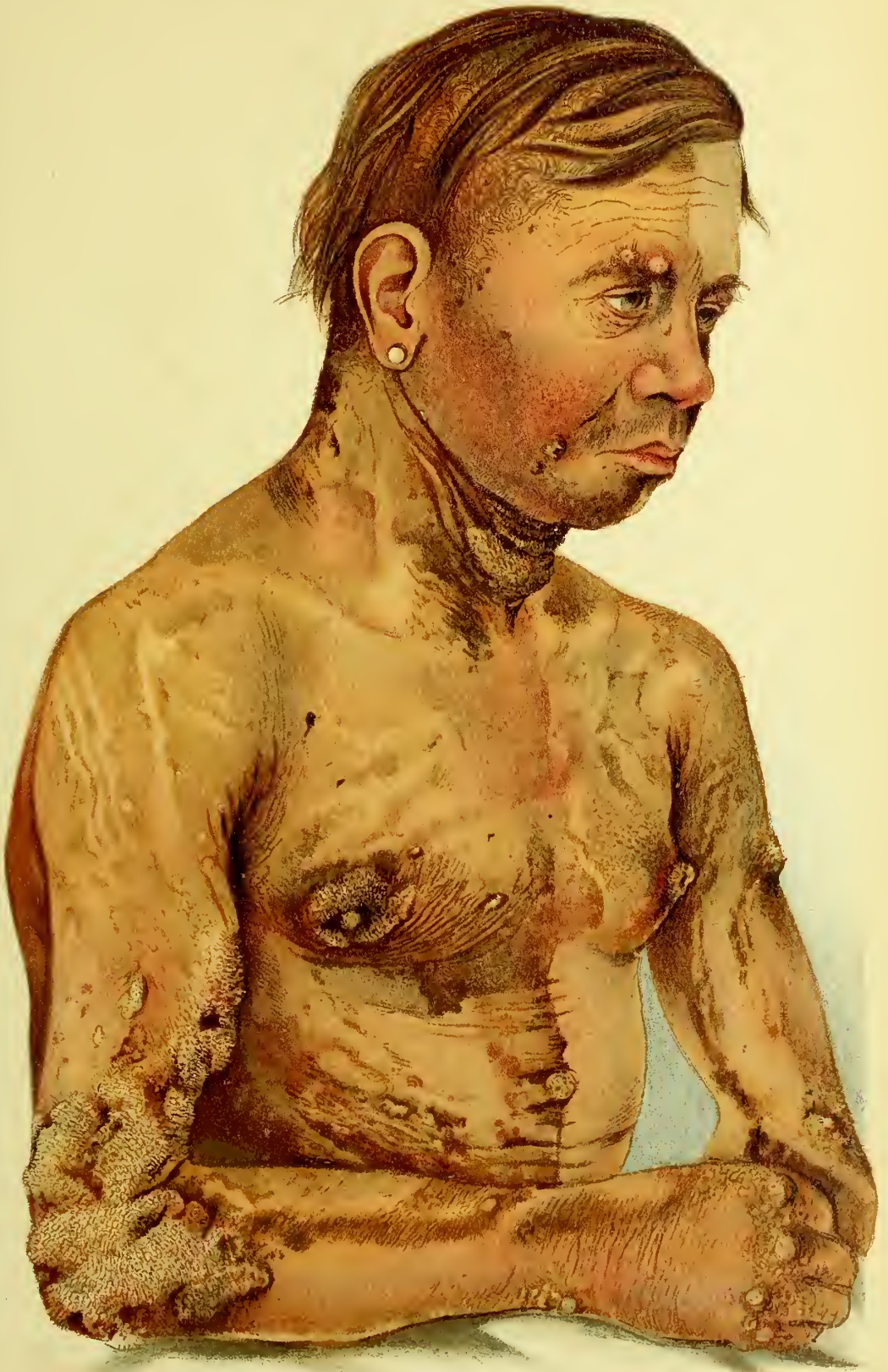



TAFEL 121.

Ichthyosis papillaris, hystrix et pigmentosa.







TAFEL 122.  
**Ichthyosis hystrix.**





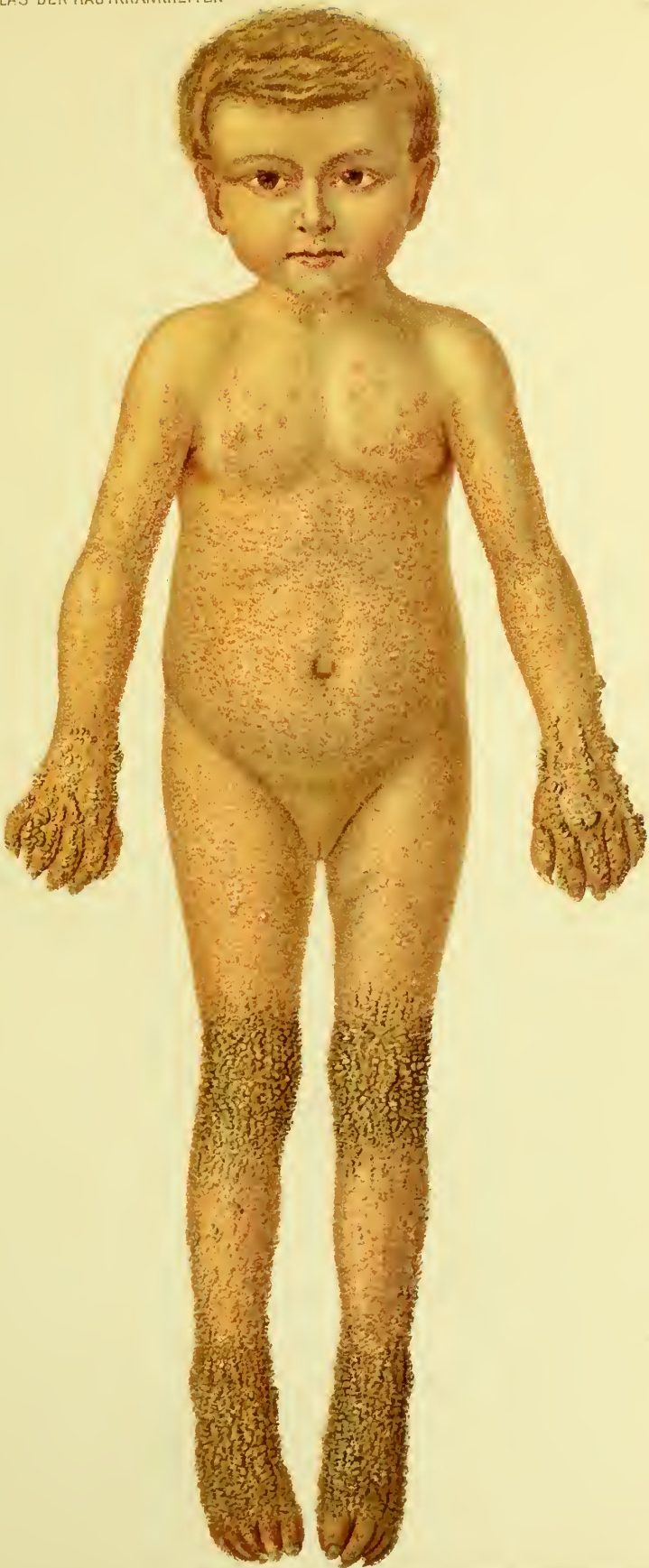



TAFEL 123.

*Ichthyosis pterygoides, plumiformis (mihi).*





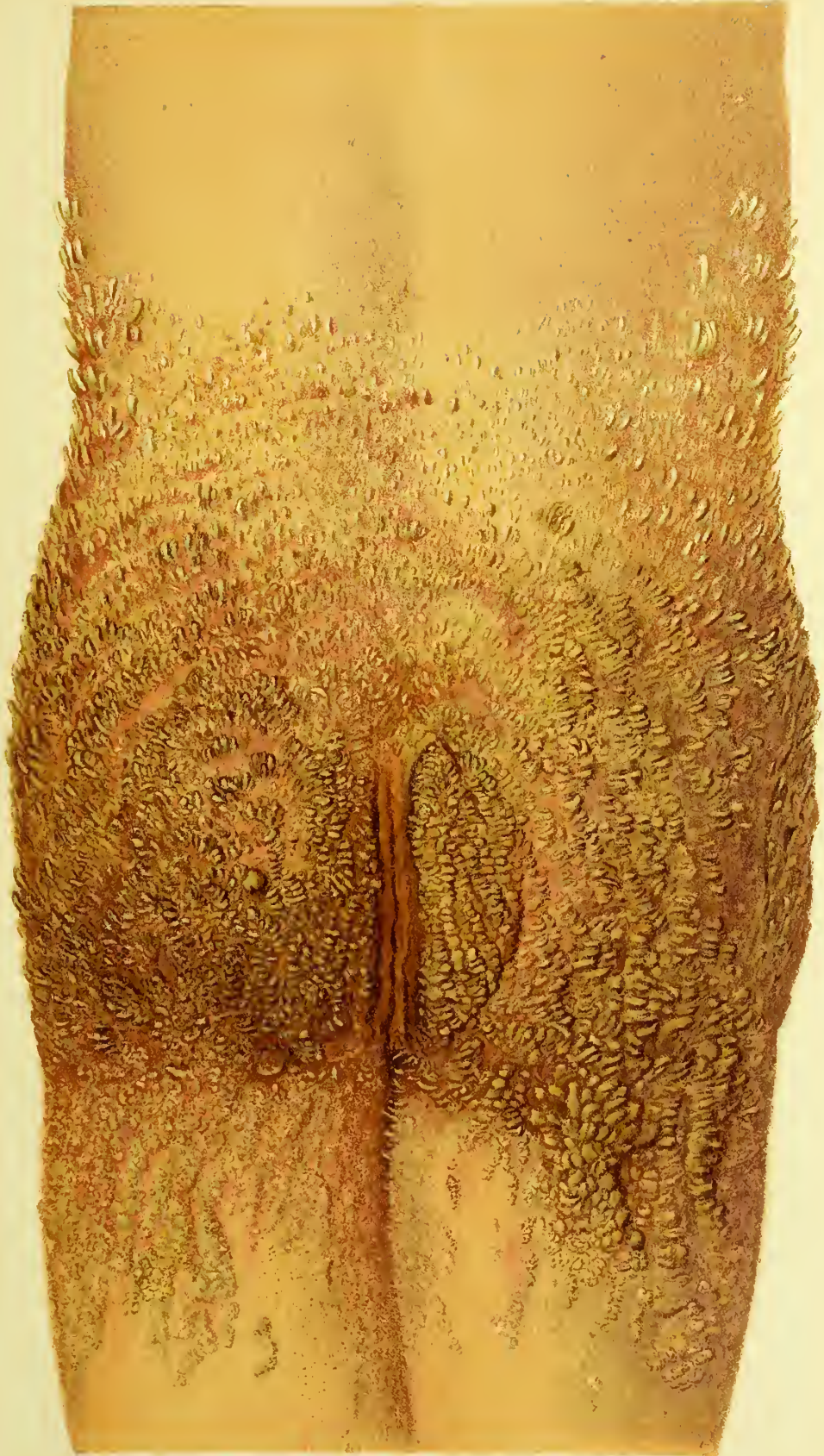




TAFEL 124.

**Ichthyosis pterygoides, plumiformis — mihi**  
(dem Kinde Taf. 123 zugehörig).







TAFEL 125.

**Ichthyosis.**





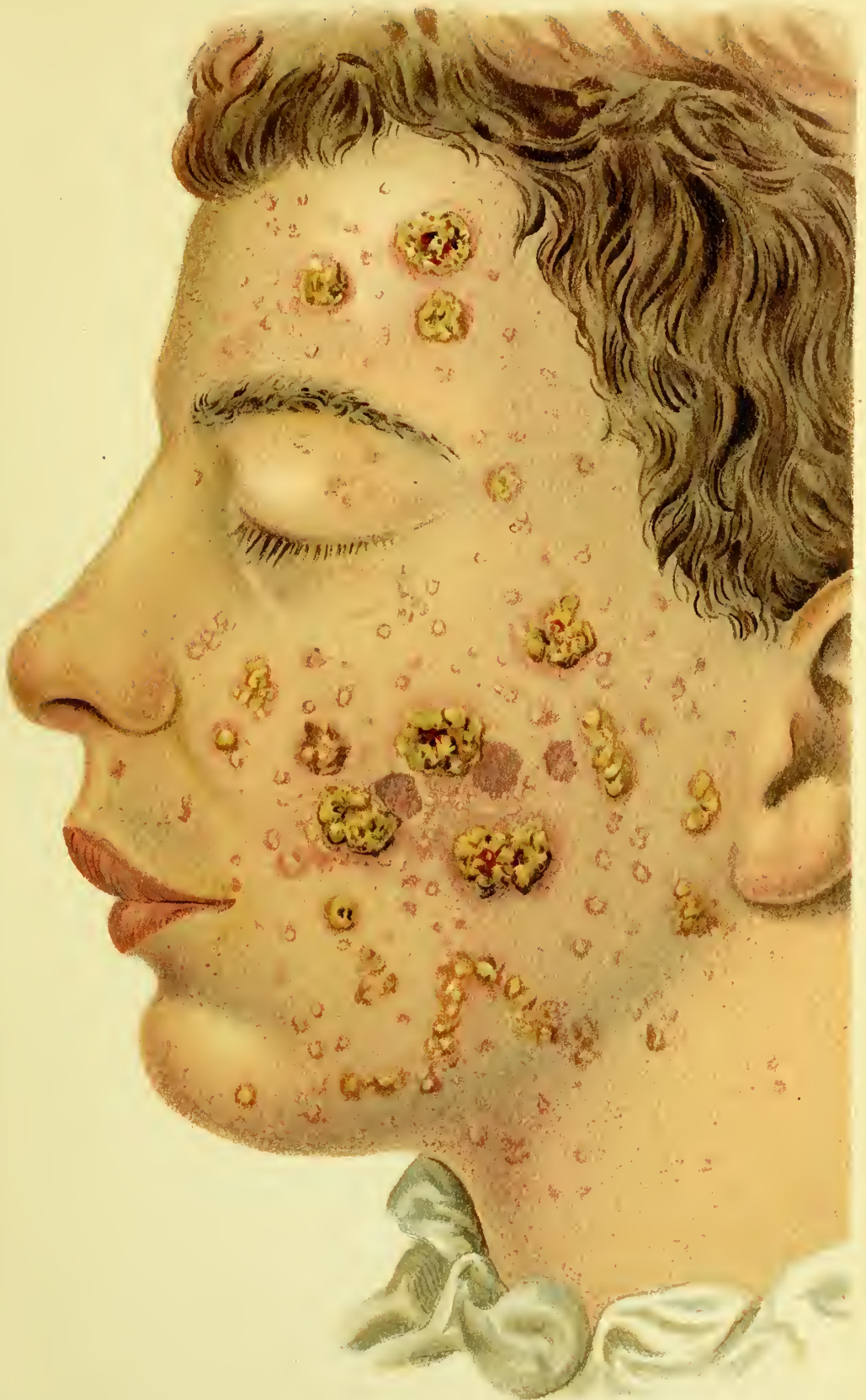




TAFEL 126.  
Impetigo contagiosa.







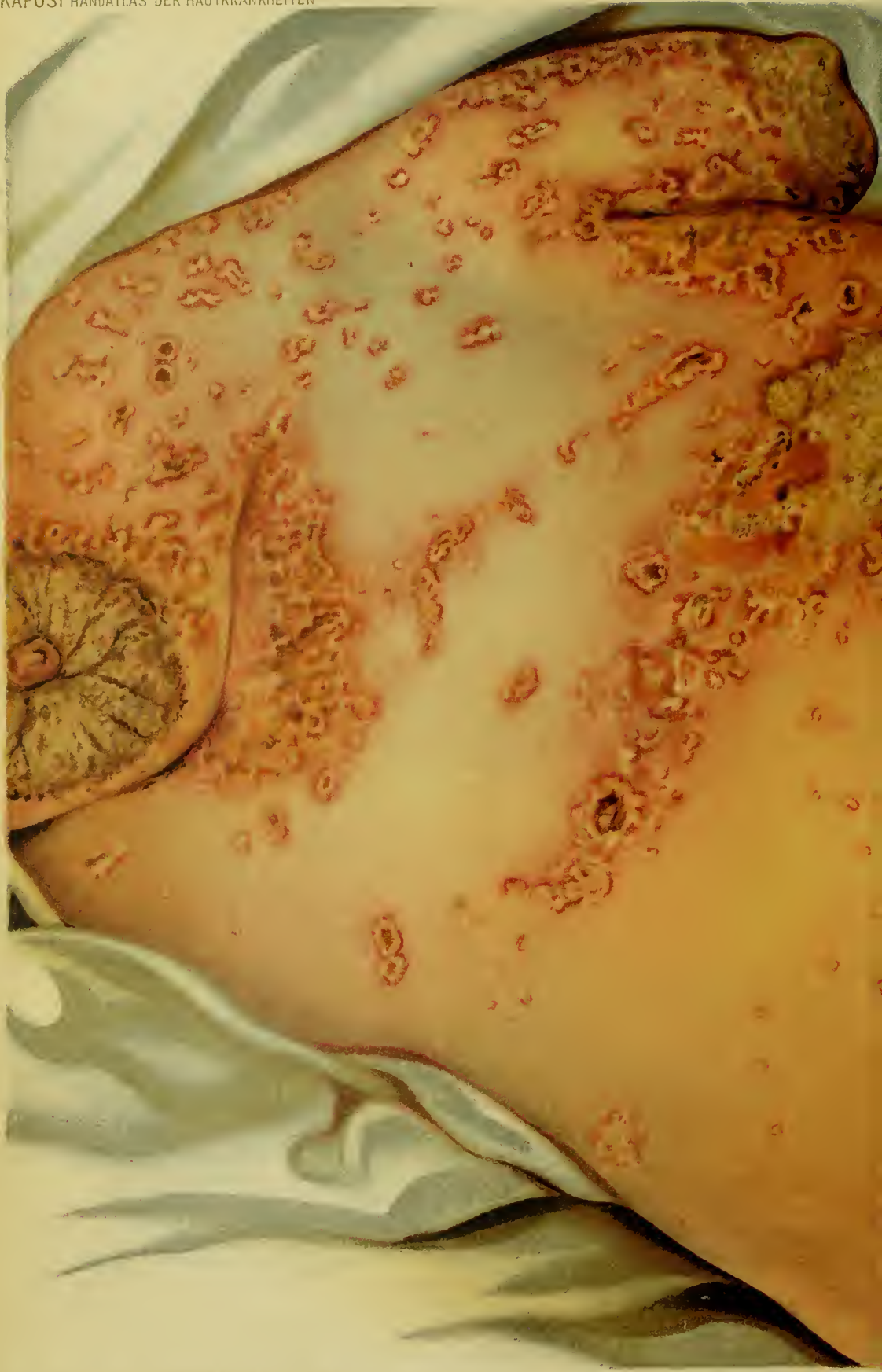


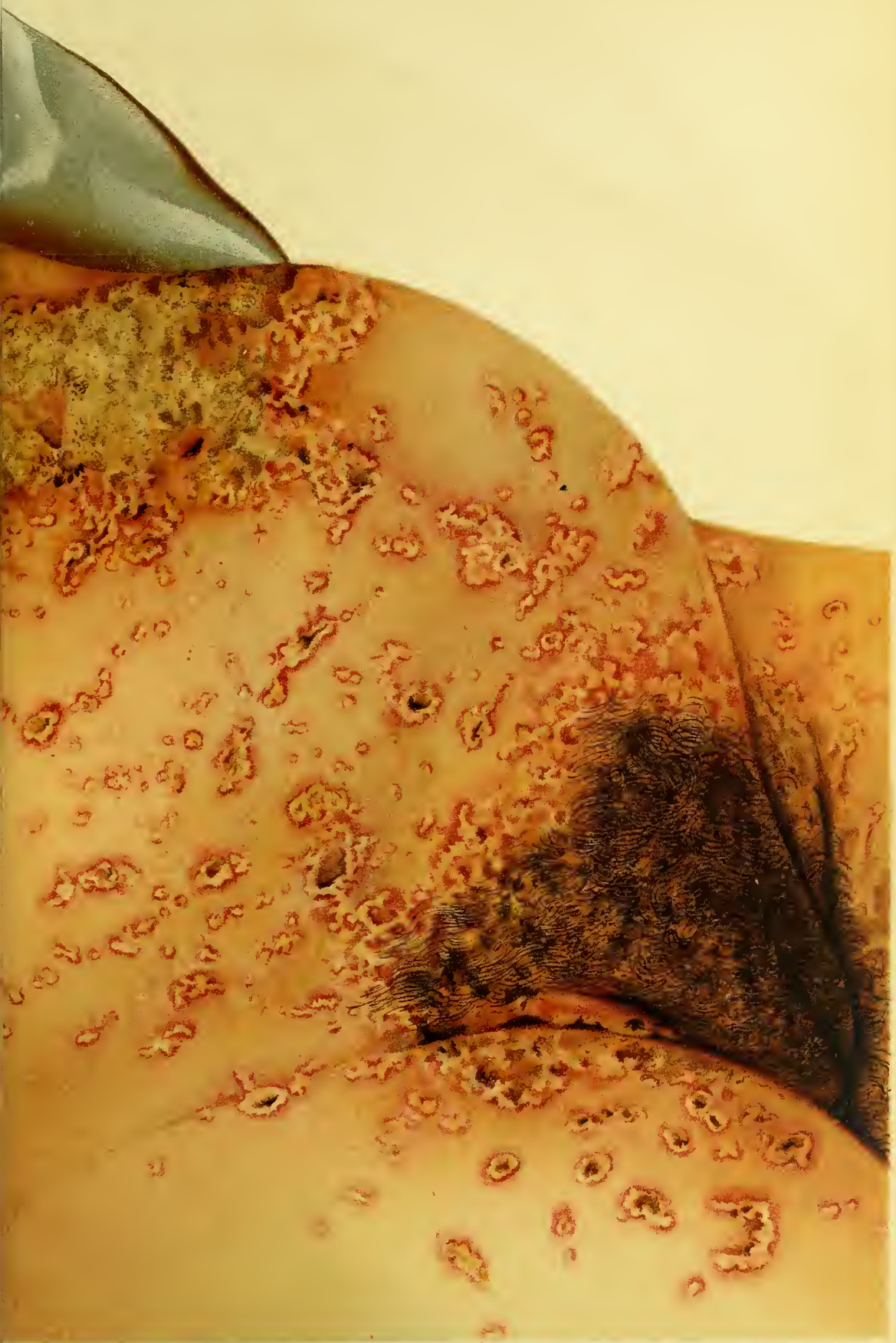
TAFEL 127.  
Impetigo herpetiformis.







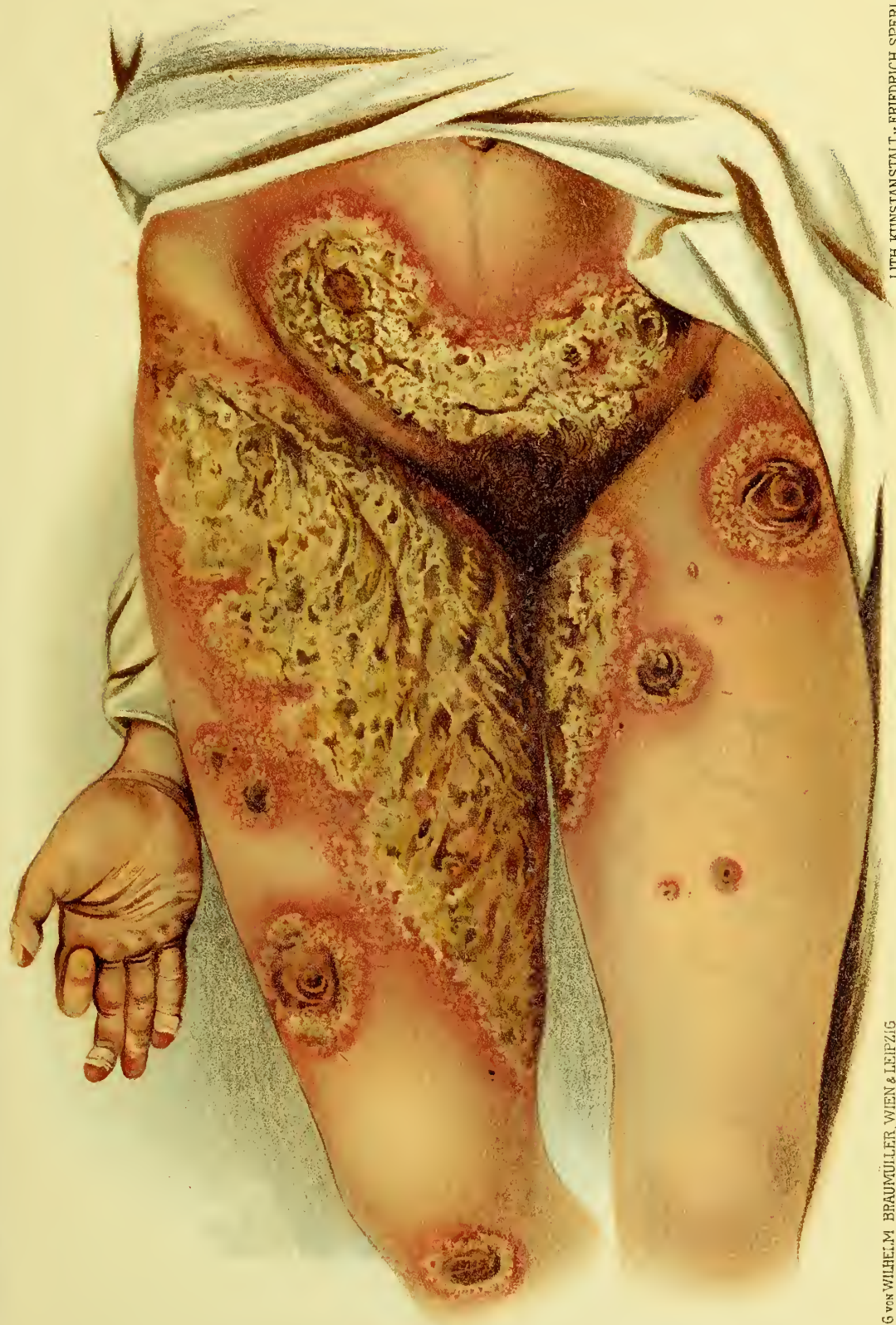





TAFEL 128.  
**Impetigo herpetiformis.**





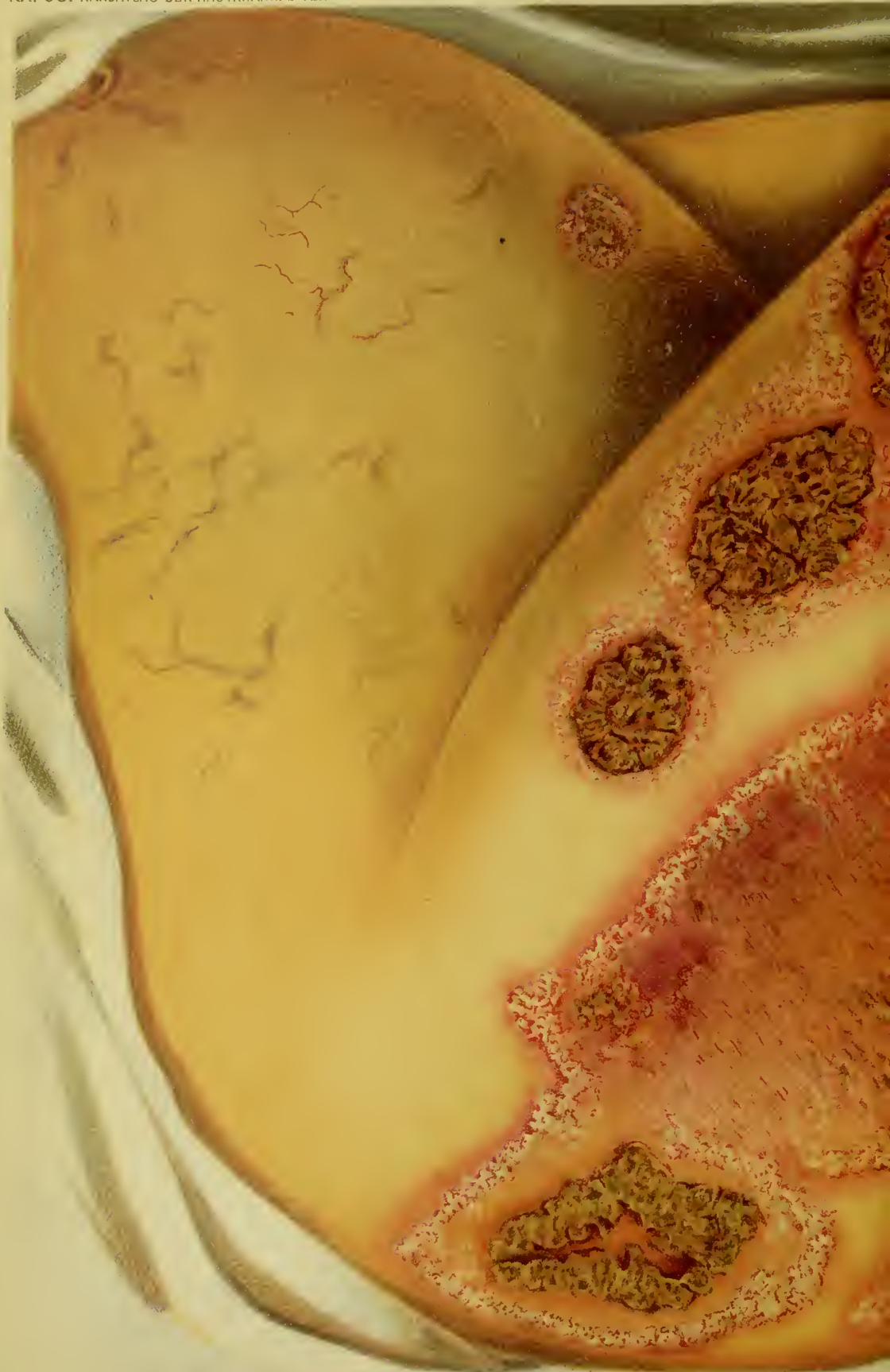


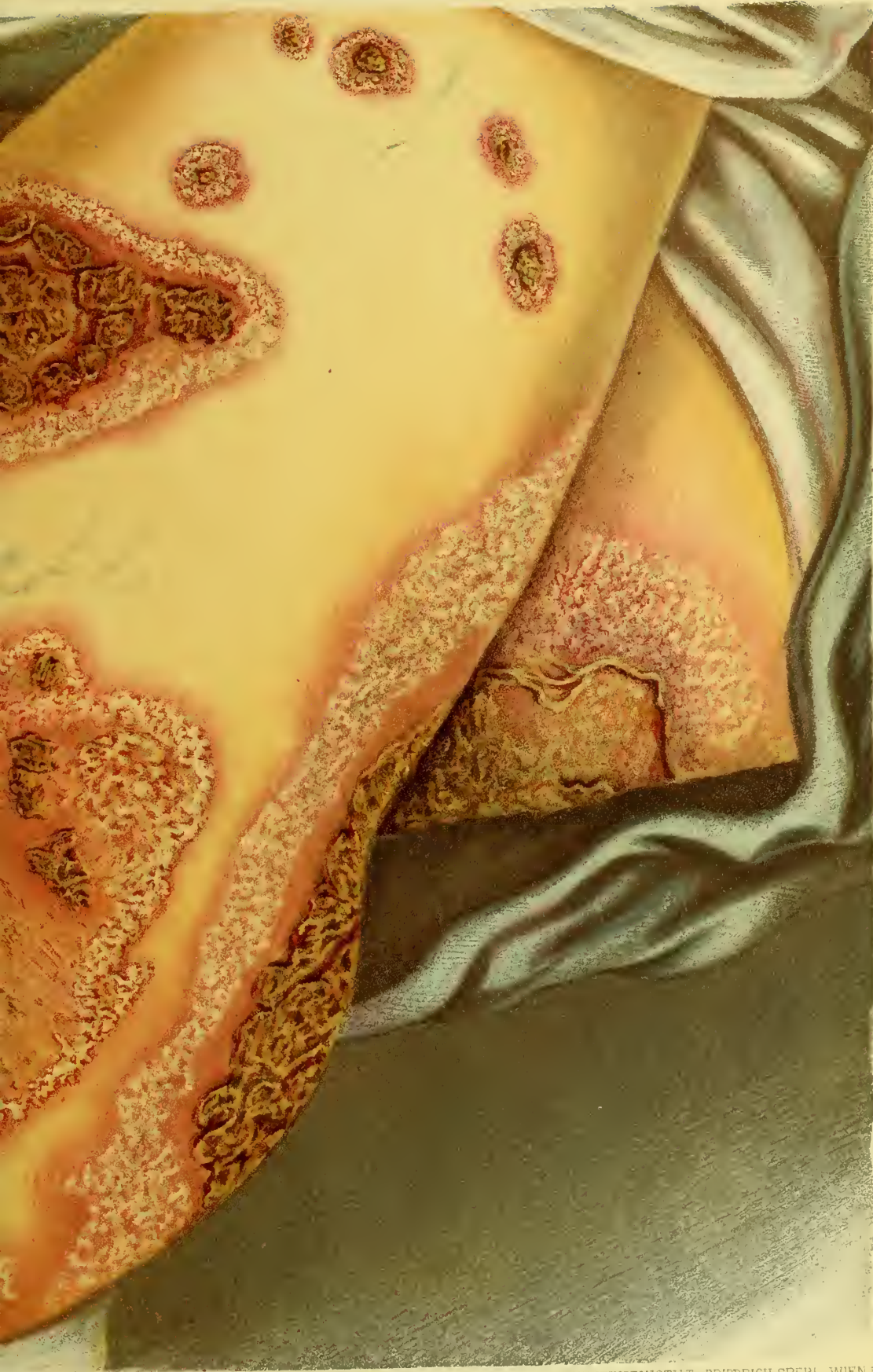TAFEL 129.  
**Impetigo herpetiformis.**











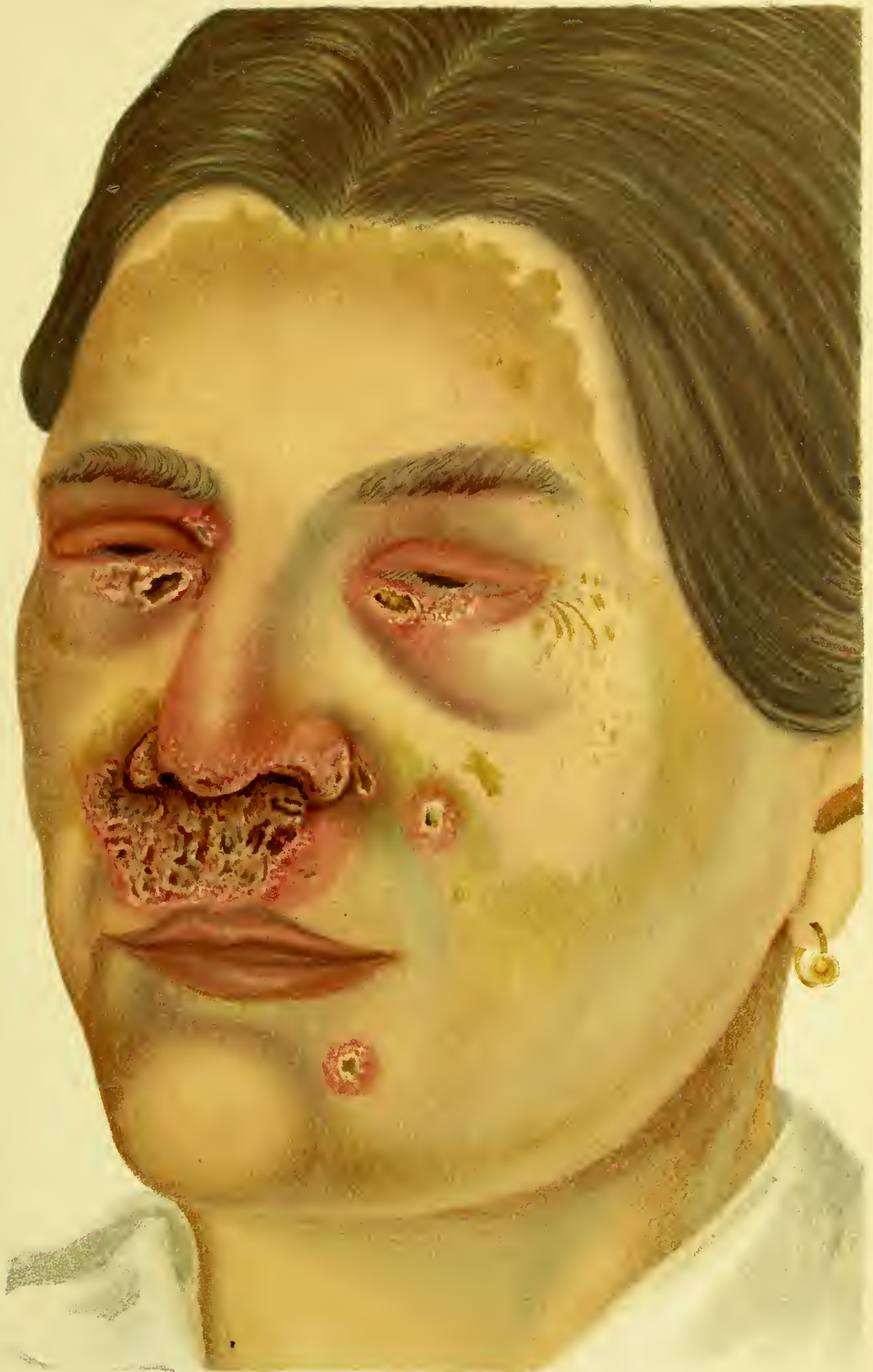

TAFEL 130.

**Impetigo herpetiformis.**



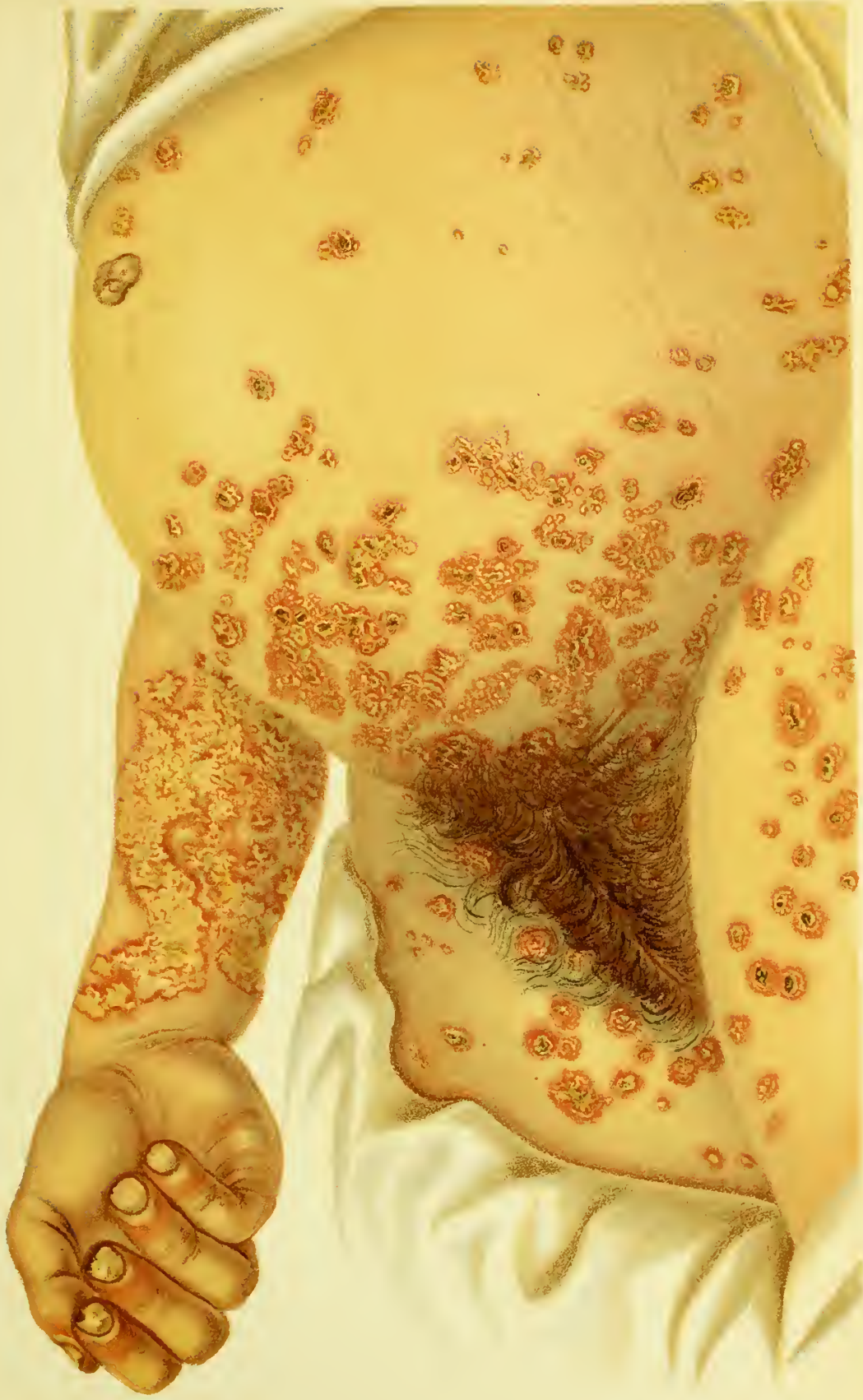





TAFEL 131.  
Impetigo herpetiformis.



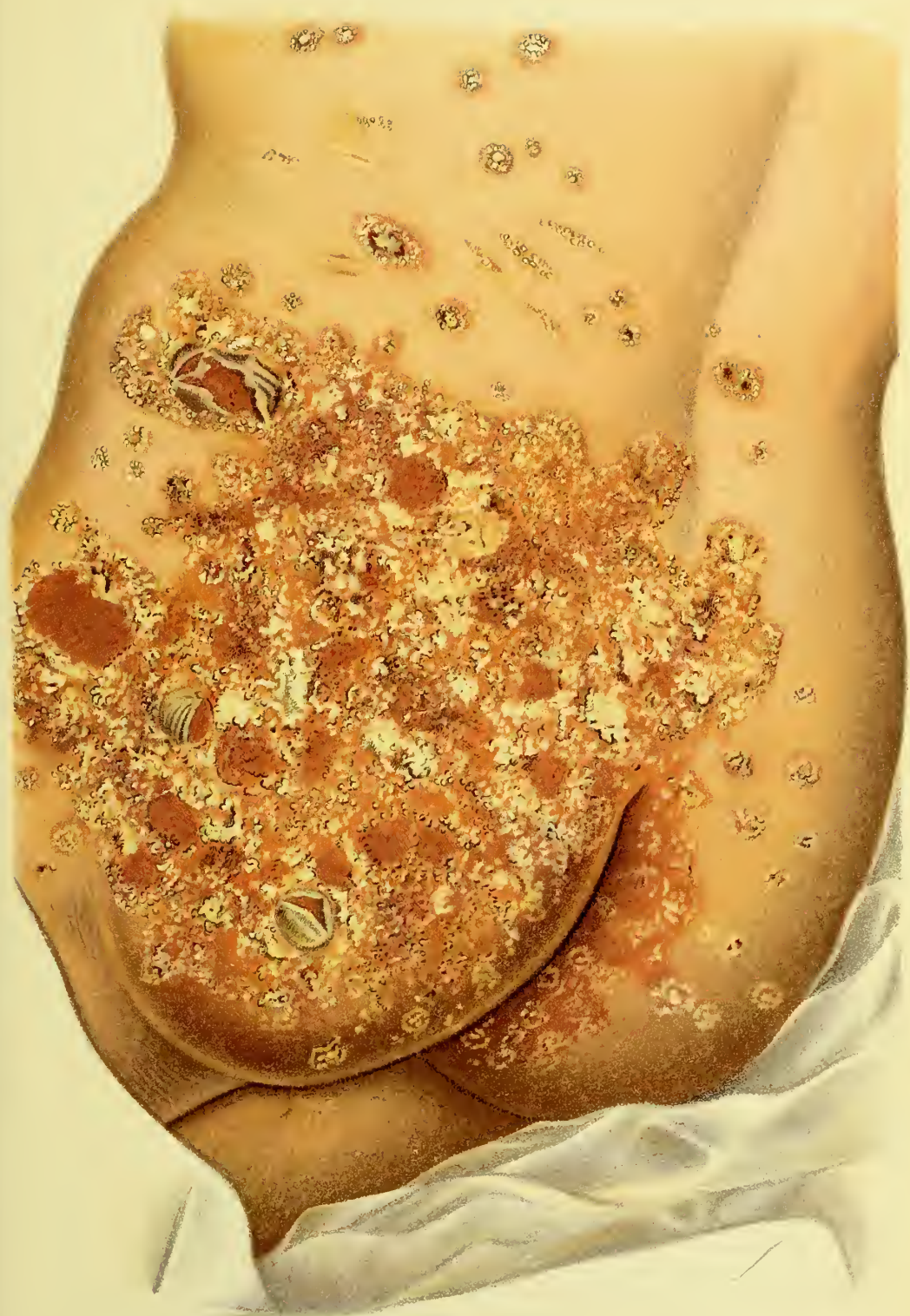






TAFEL 132.  
Impetigo herpetiformis in mare.







TAFEL 133.

Impetigo herpetiformis in oesophago.





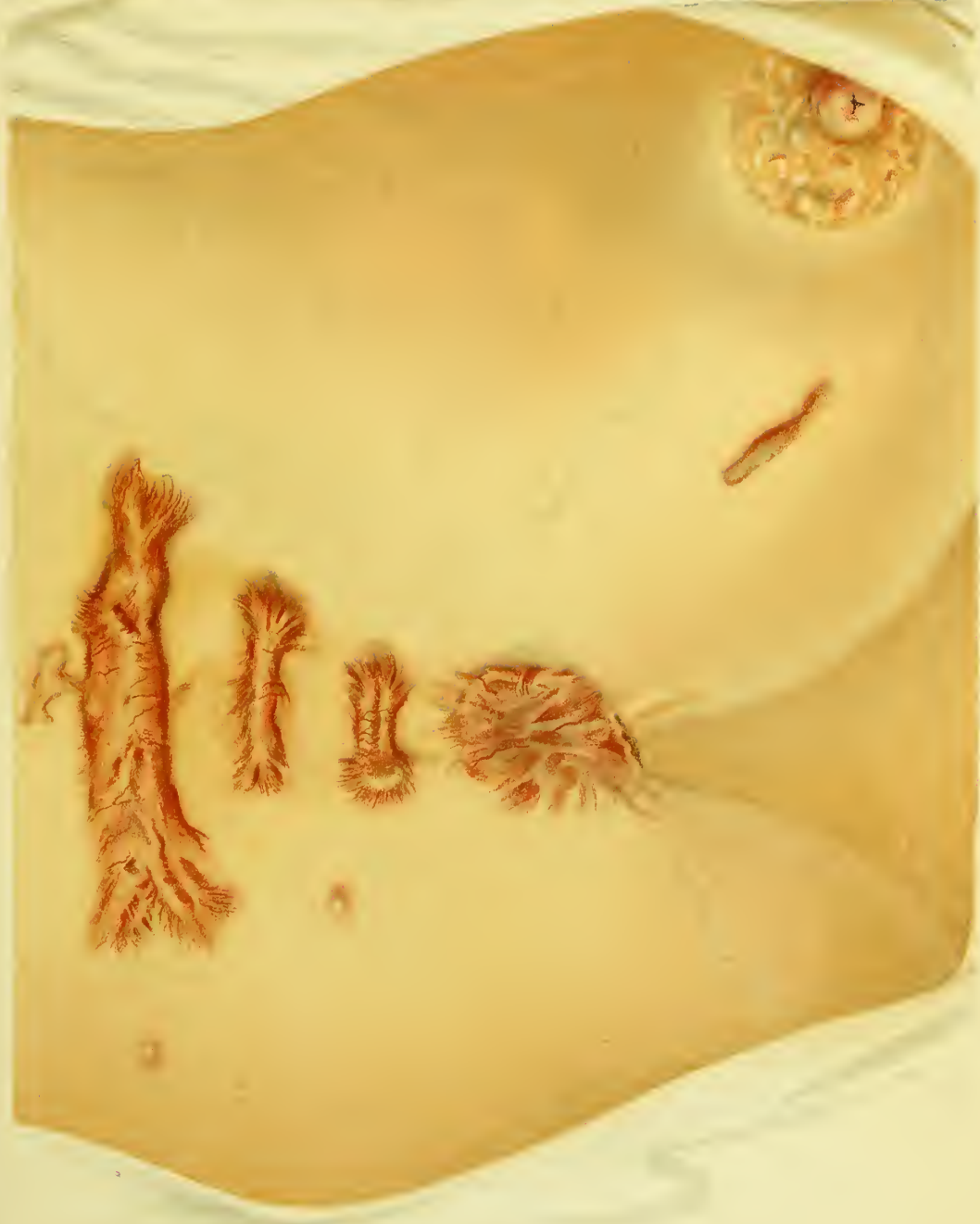



TAFEL 134.

**Keloid.**









TAFEL 135.

**Keratosis nigricans (Akanthosis nigricans autorum).**







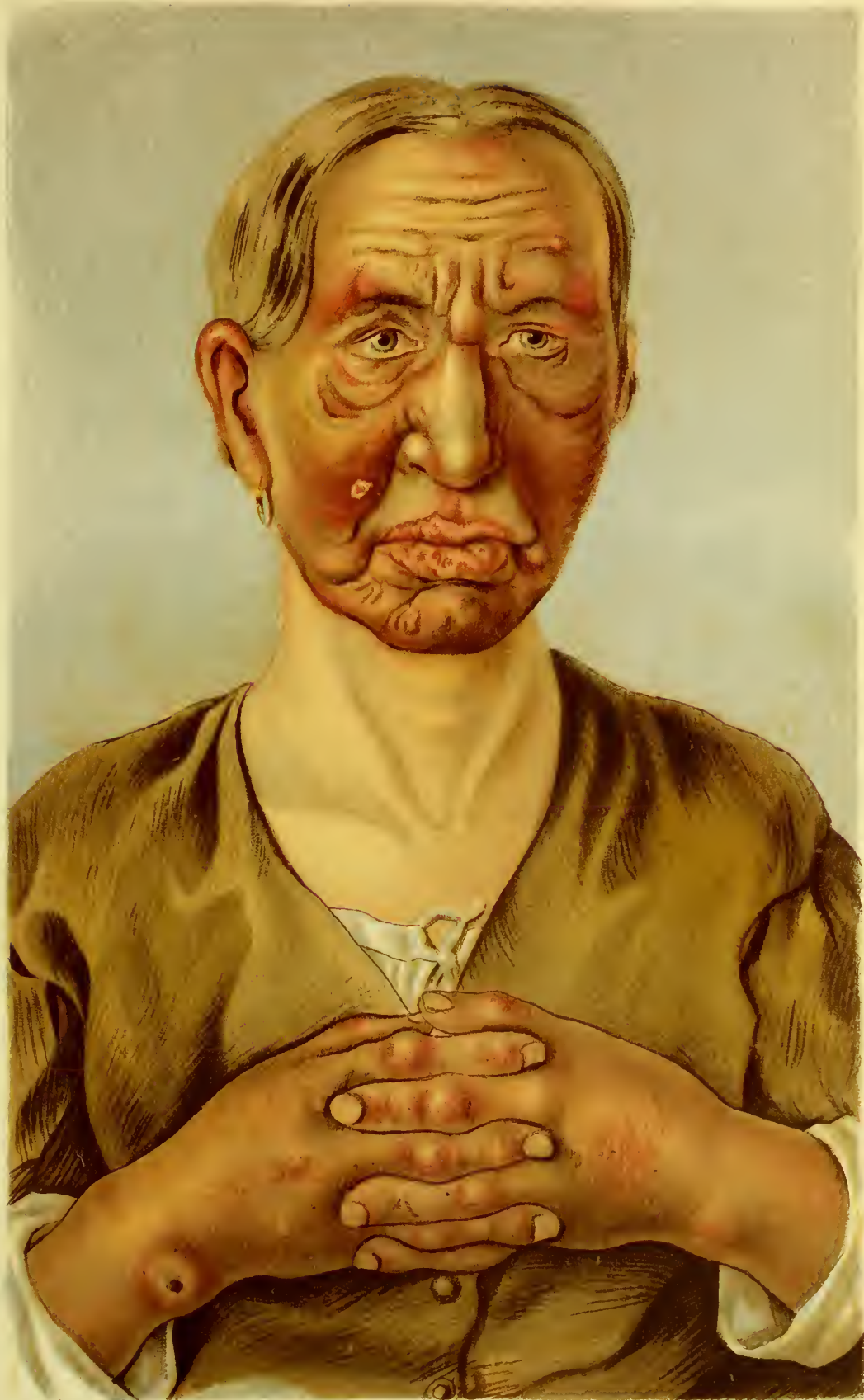TAFEL 136.

**Lepra tuberosa**

(Frau aus Weissenburg, Elsass, in St. Louis erkrankt).










TAFEL 137.

**Lepra maculosa et tuberosa**

(Mann aus Buenos-Ayres).







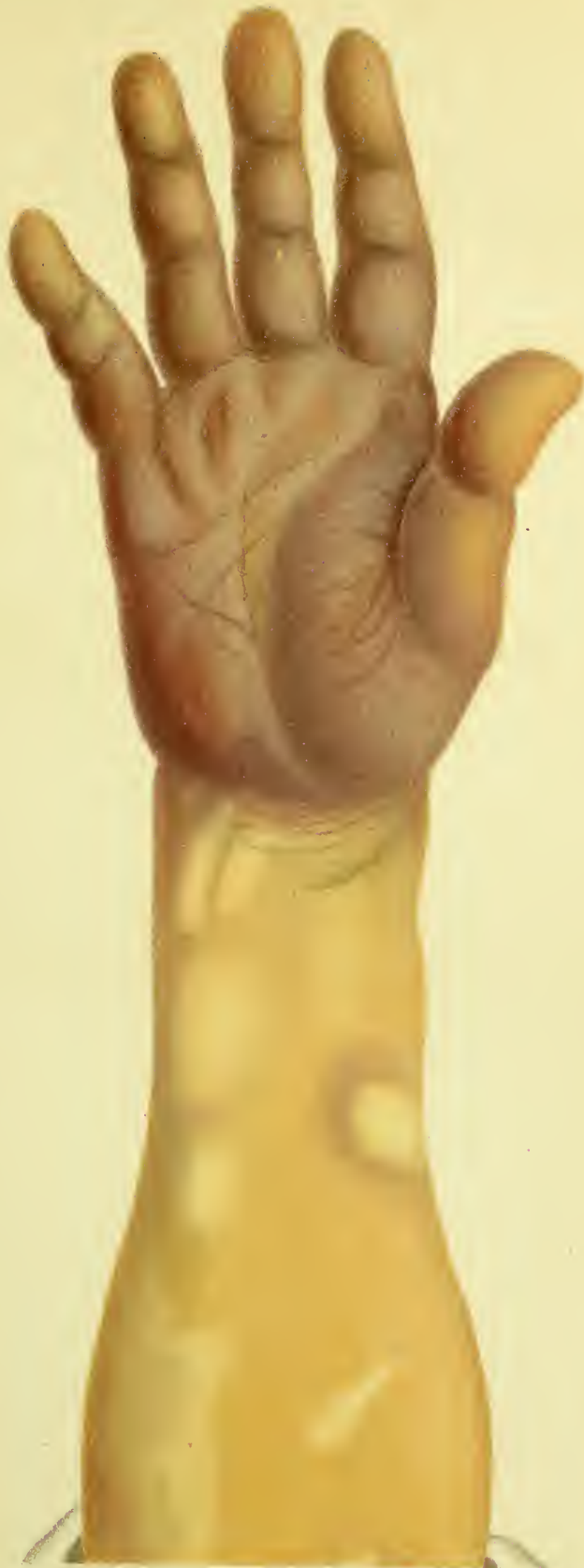

TAFEL 138.

**Lepra maculosa, tuberosa et anaesthetica**

(Taf. 137 zugehörig, Buenos-Ayres).



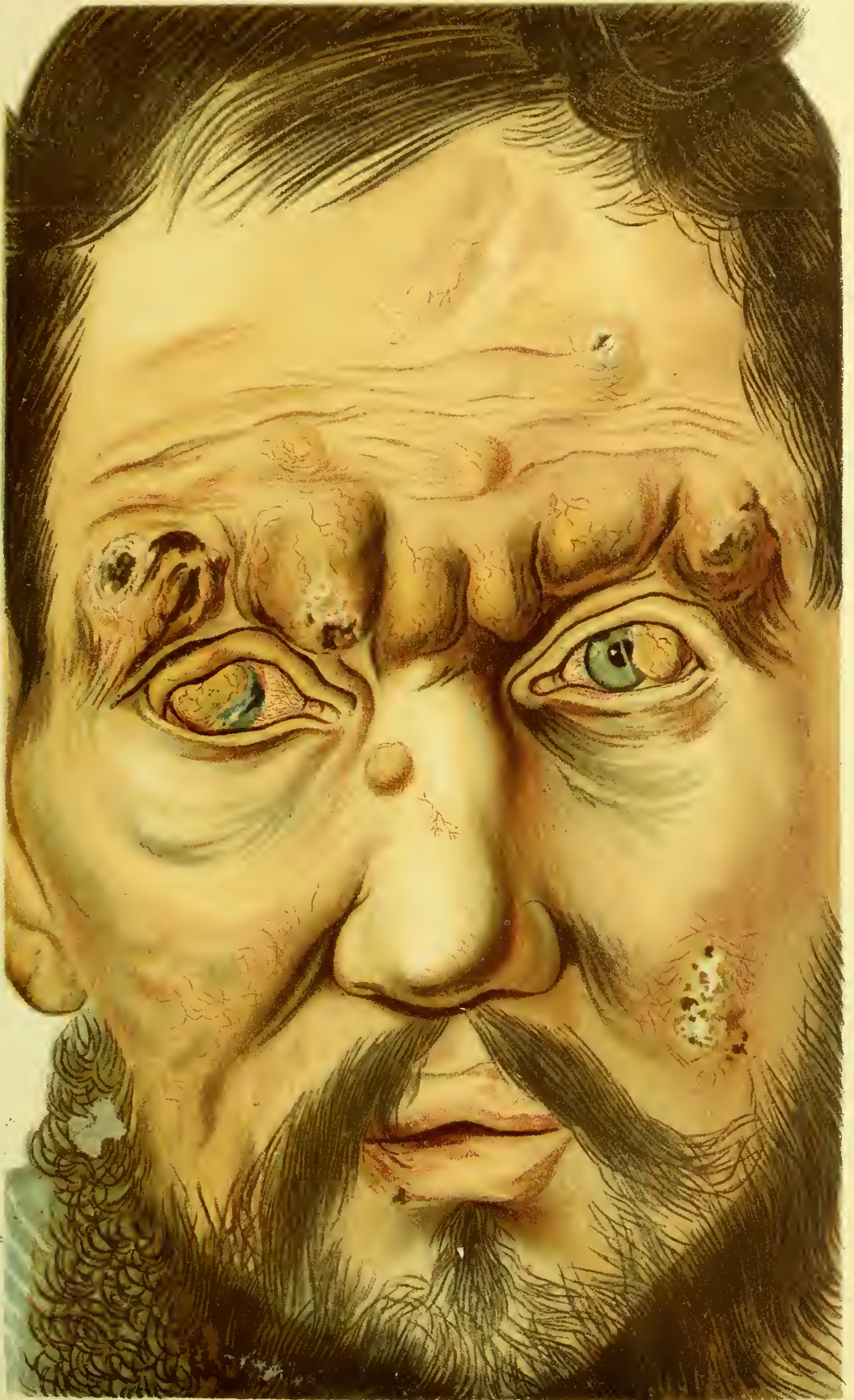




TAFEL 139.

Lepra tuberosa, anaesthetica, Pannus leprosus oculi  
utriusque  
(von Cerigo).







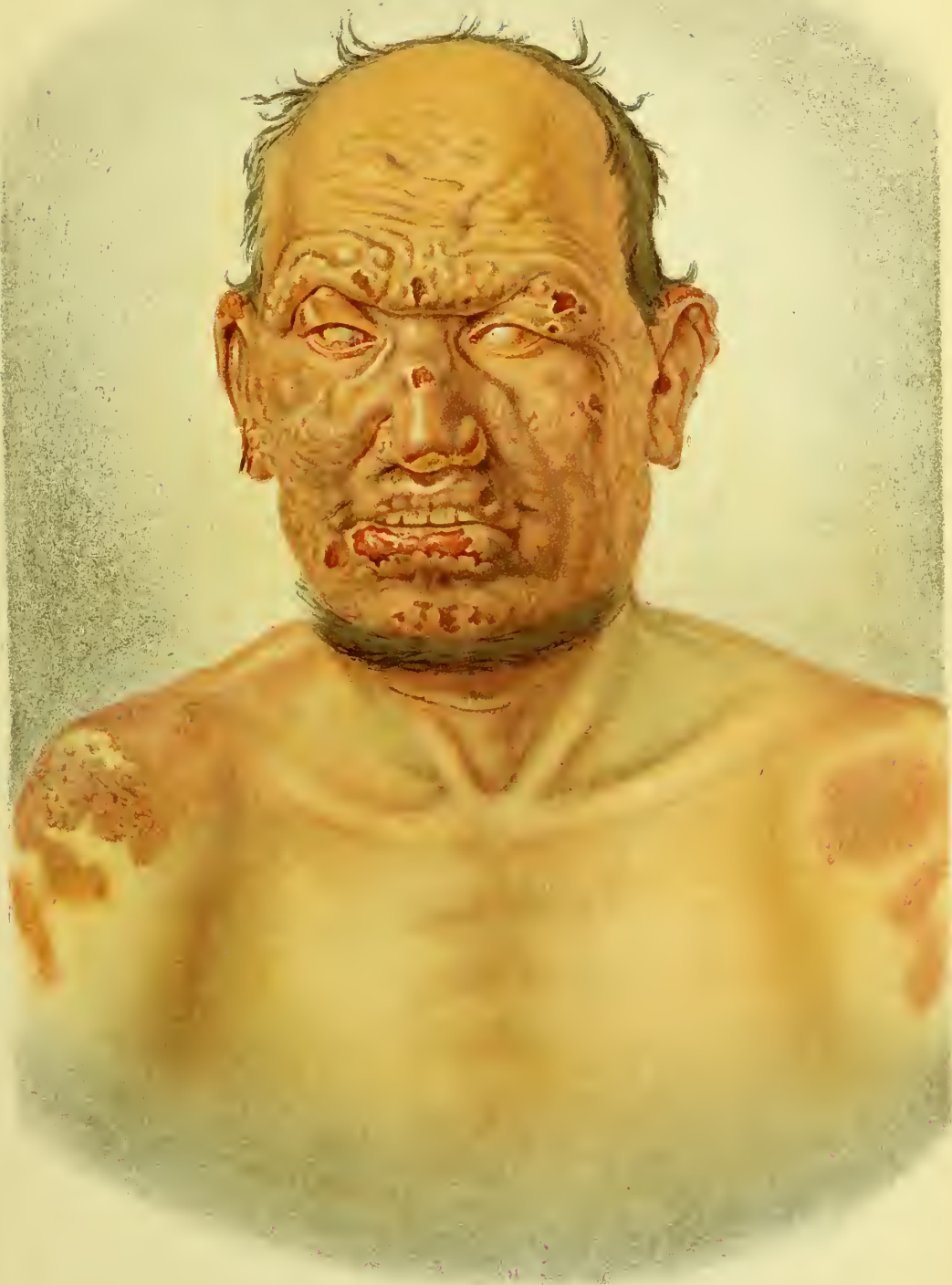

TAFEL 140.

**Lepra tuberosa, anaesthetica, Keratitis leprosa**

(dem Manne von Taf. 139 angehörig, späteres Stadium, von Cerigo).



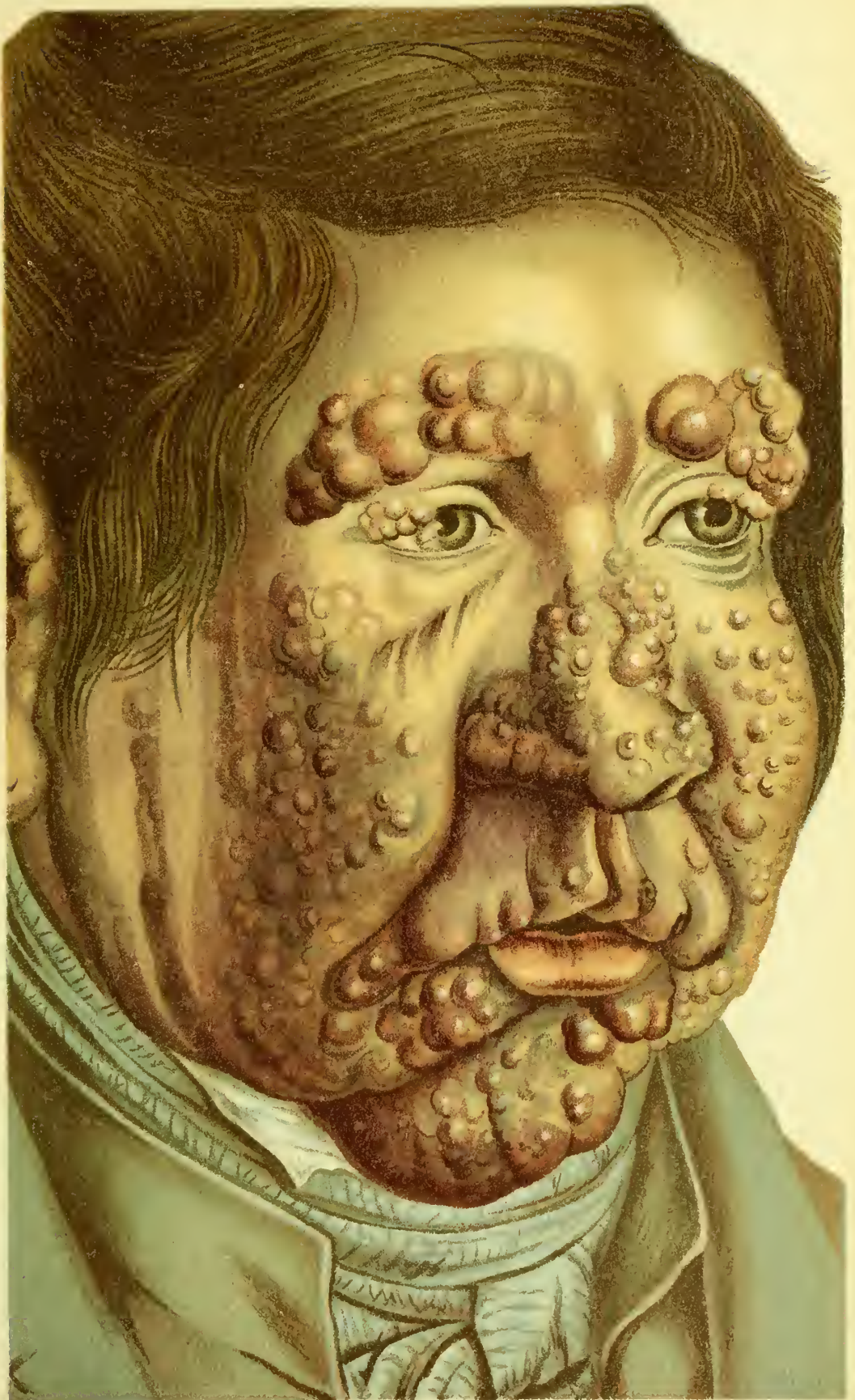



TAFEL 141.  
**Lepra tuberosa**  
(aus Norwegen).







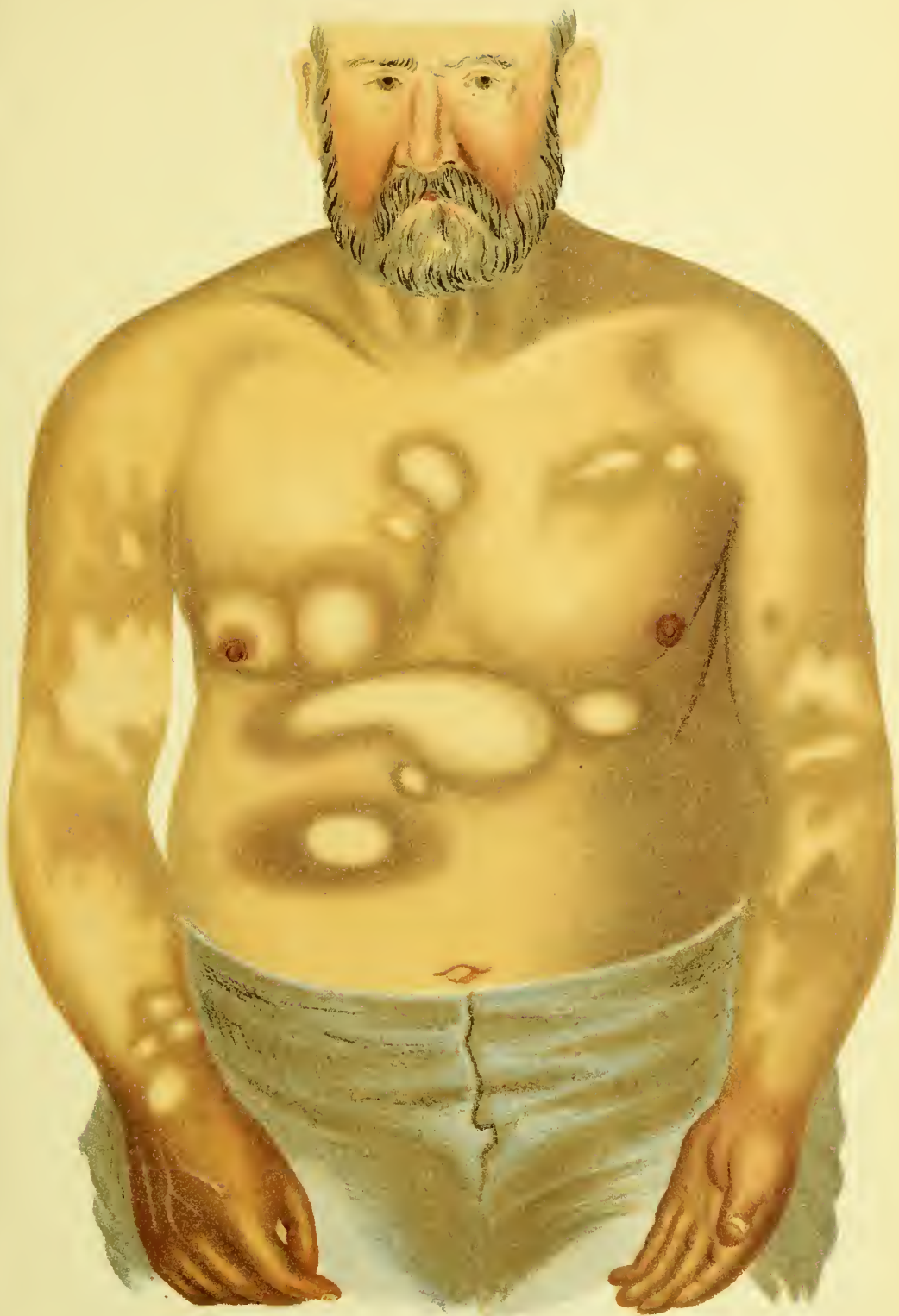

TAFEL 142.

**Lepra maculosa et anaesthetica**

(aus Buenos-Ayres).







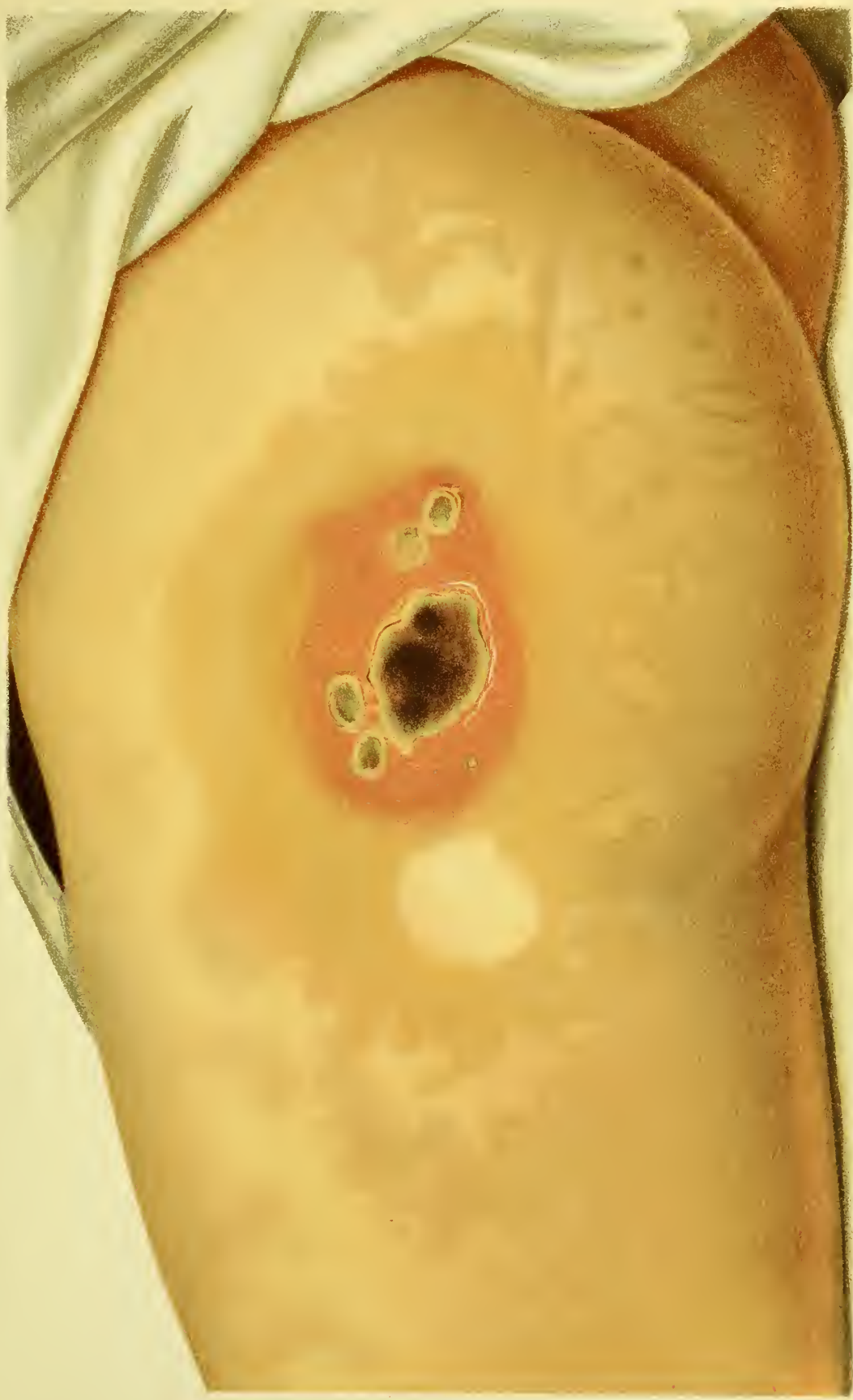

TAFEL 143.

Lepra maculosa et anaesthetica (Combustio escharotica  
propter Anaesthesiam impercepta).





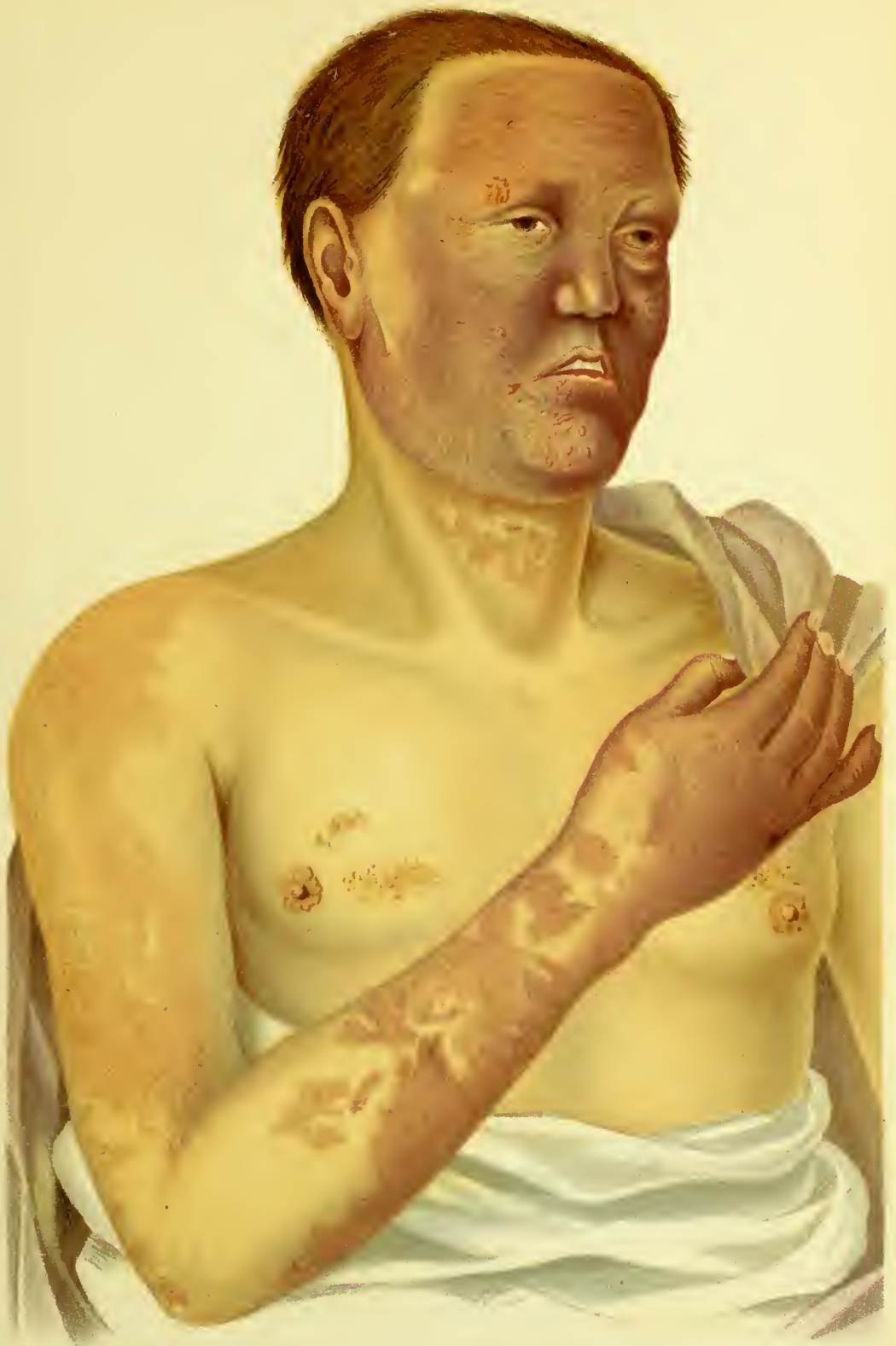



TAFEL 144.

Lepra maculosa et anaesthetica.





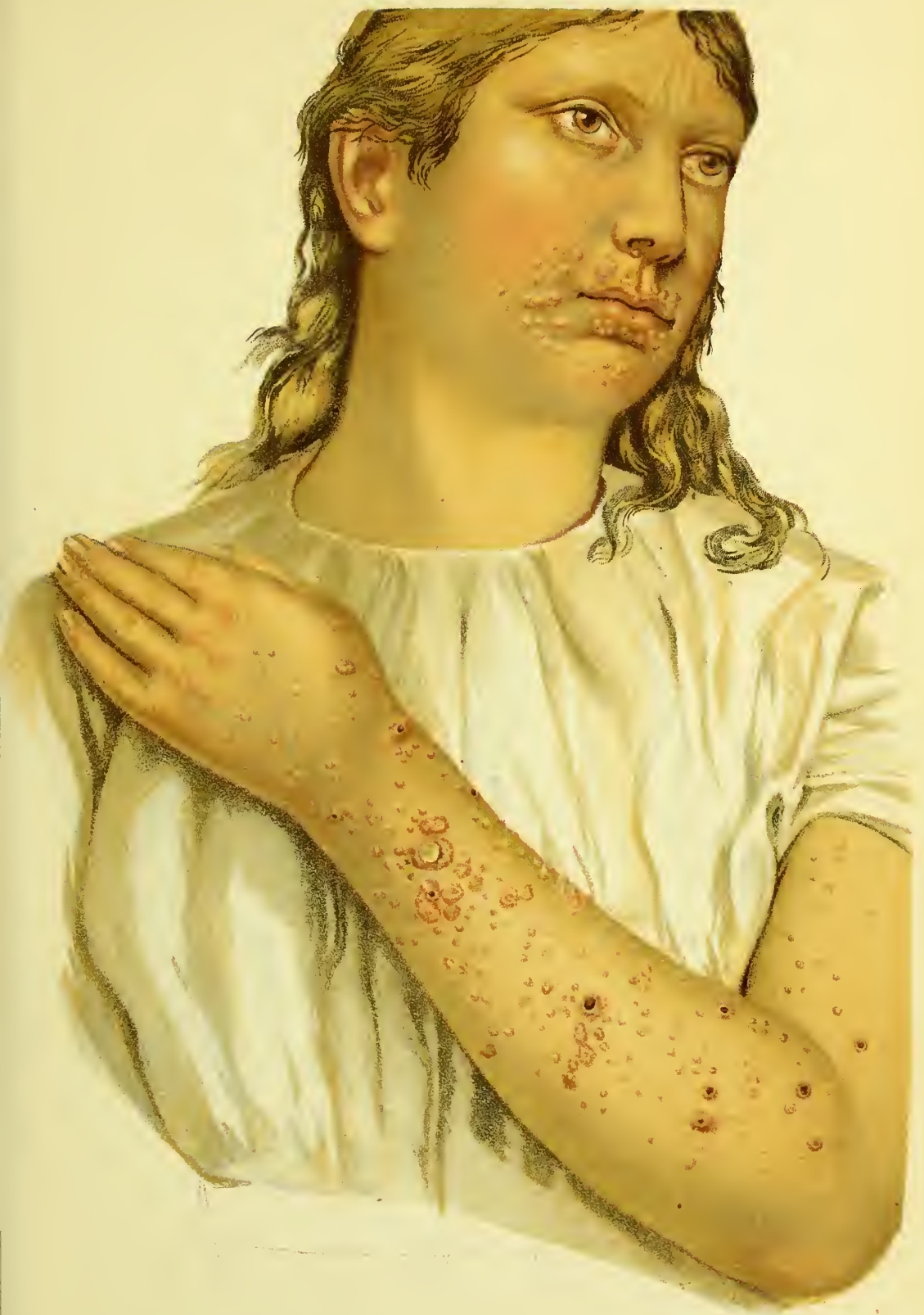



TAFEL 145.

Lepra papulosa — mihi — disseminata et circinnata  
(Mädchen aus Rewal).





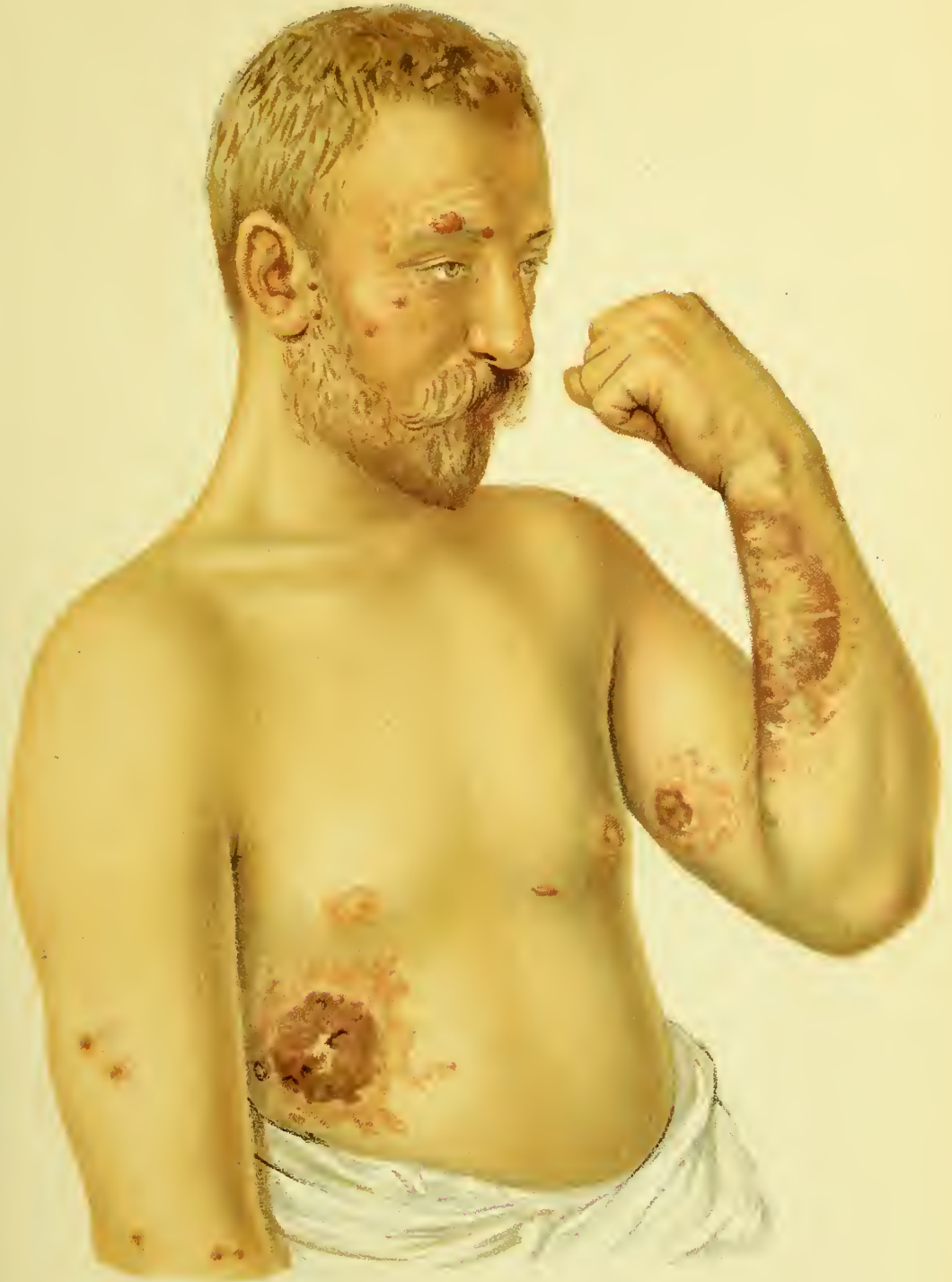


TAFEL 146.

**Lepra tuberosa et anaesthetica acutissima**

(Mann aus Salonich).





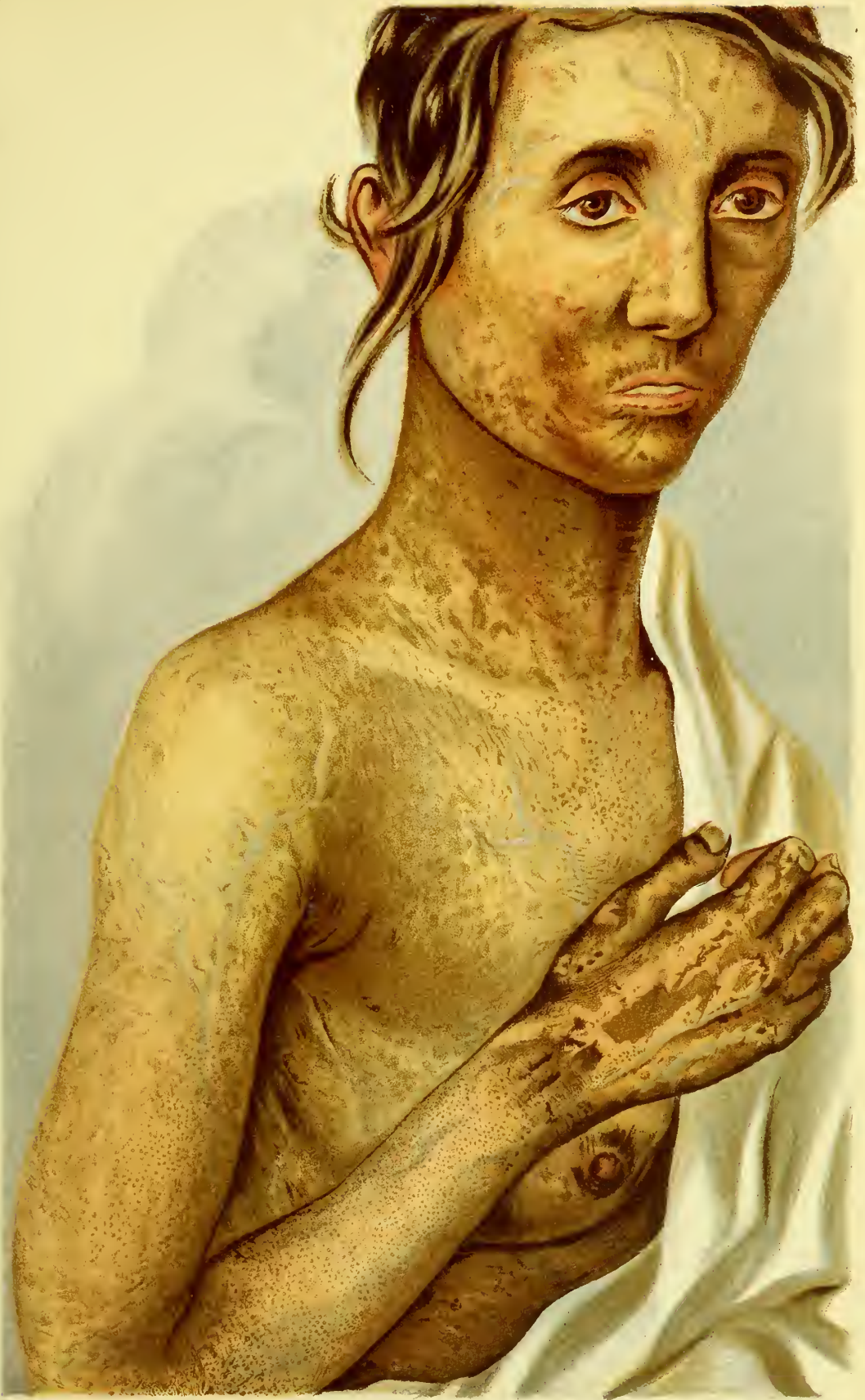




TAFEL 147.

**Lepra maculosa-pigmentosa — mihi — et mutilans**  
(Frau aus Rumänien).







TAFEL 148.

**Lepra maculosa-anaesthetica — Lepra nervorum**  
(aus Norwegen).





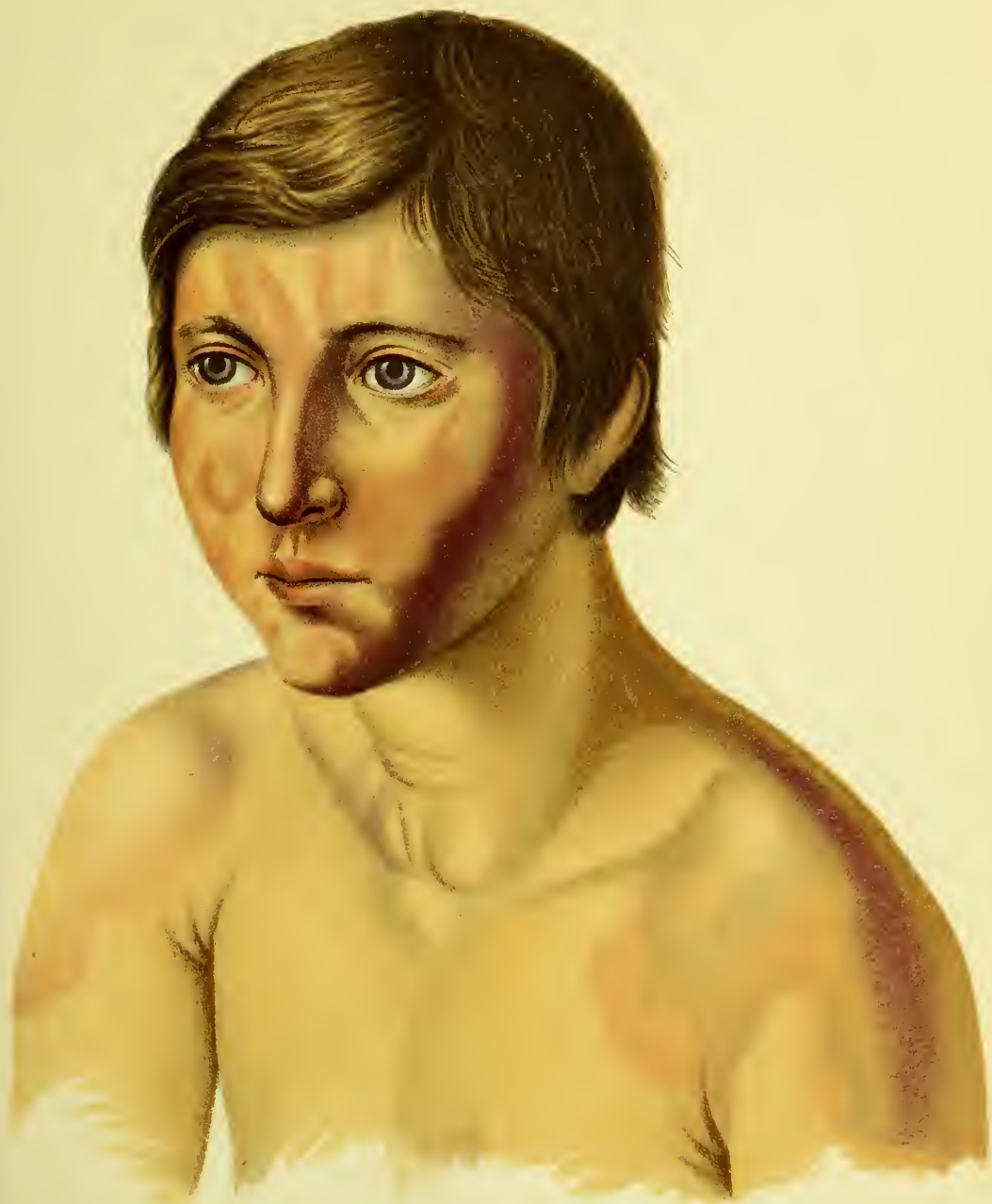



TAFEL 149.

**Lepra maculosa-anaesthetica**  
(aus Norwegen).







TAFEL 150.

**Lepra nervorum**  
(aus Norwegen).





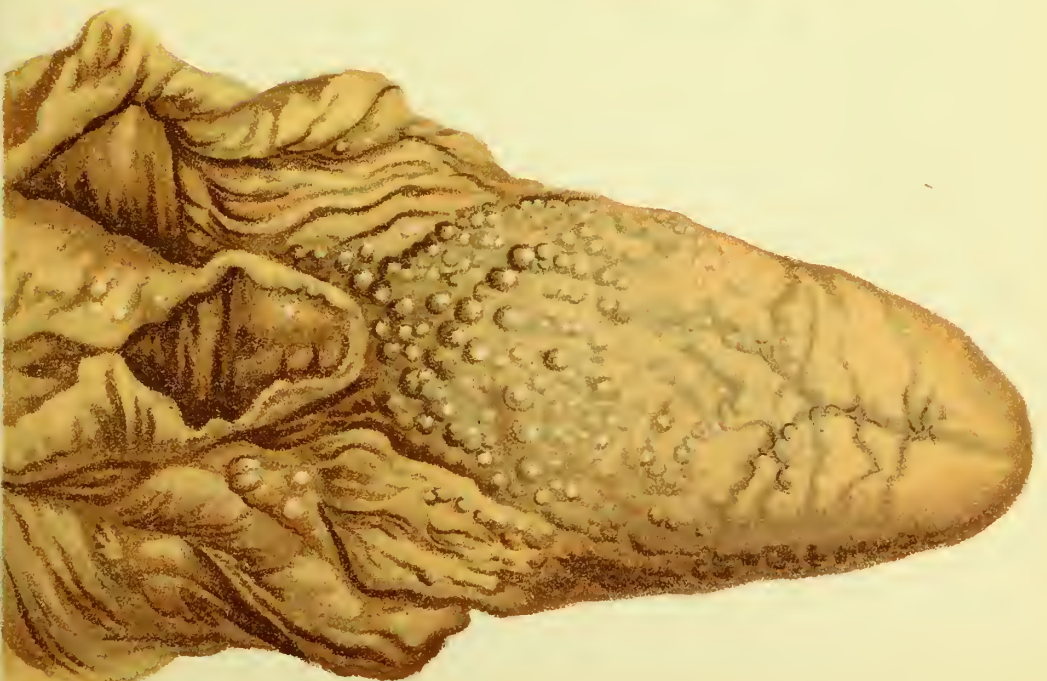
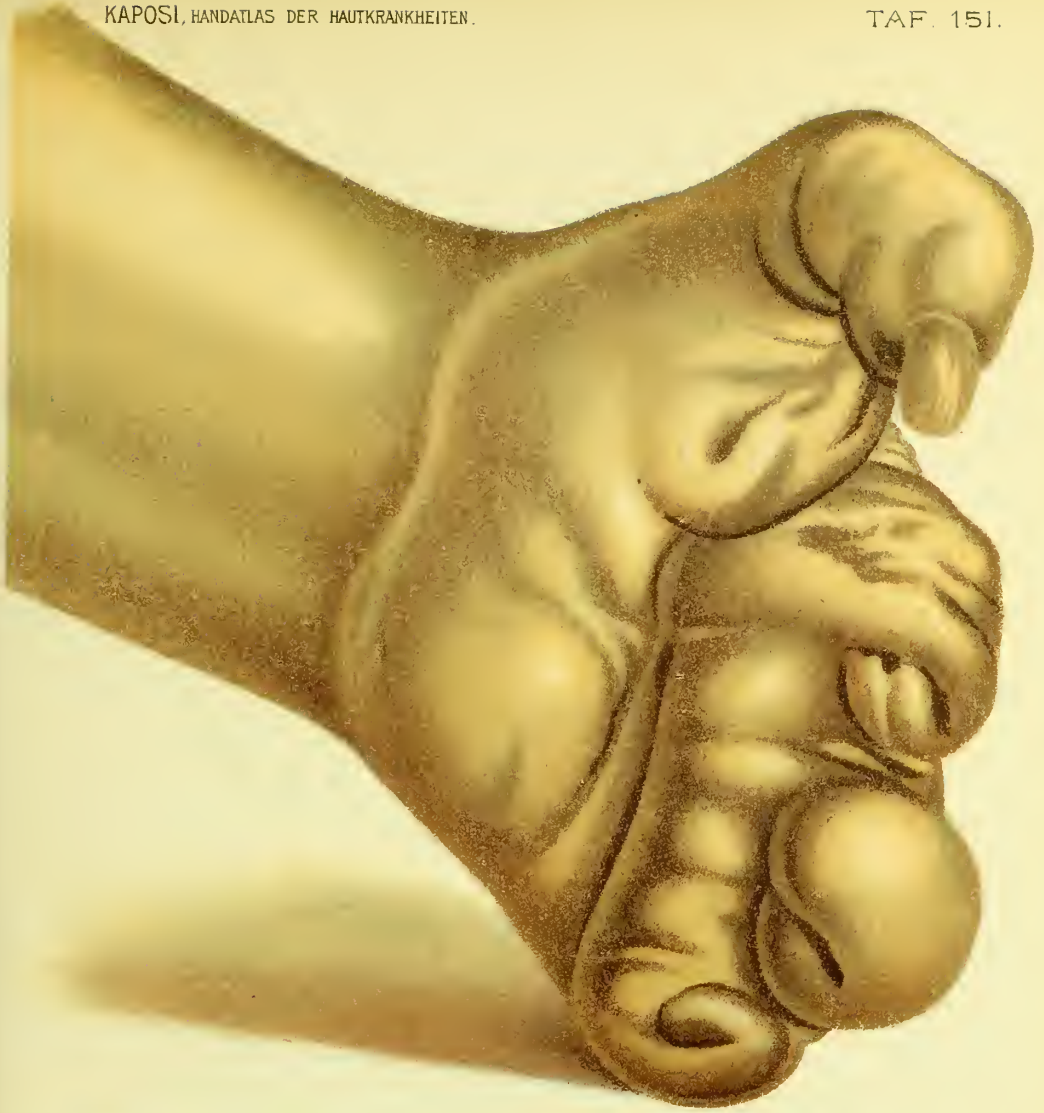



TAFEL 151.

**Lepra mutilans — Lepra nodosa linguae**  
(aus Norwegen).





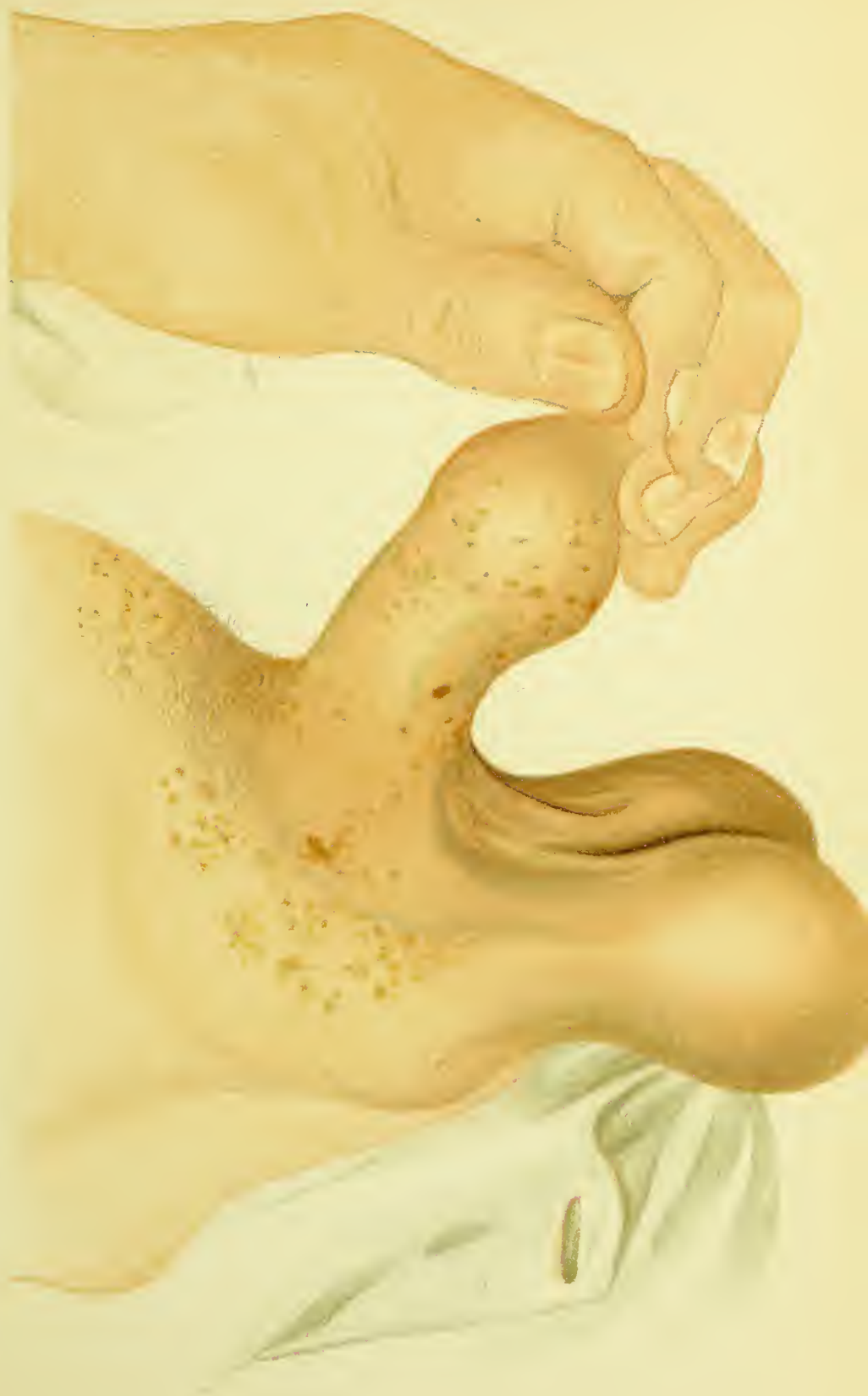



TAFEL 152.

Lentigo — Ephelis (penis).







TAFEL 153.  
**Lentigo — Ephelis.**



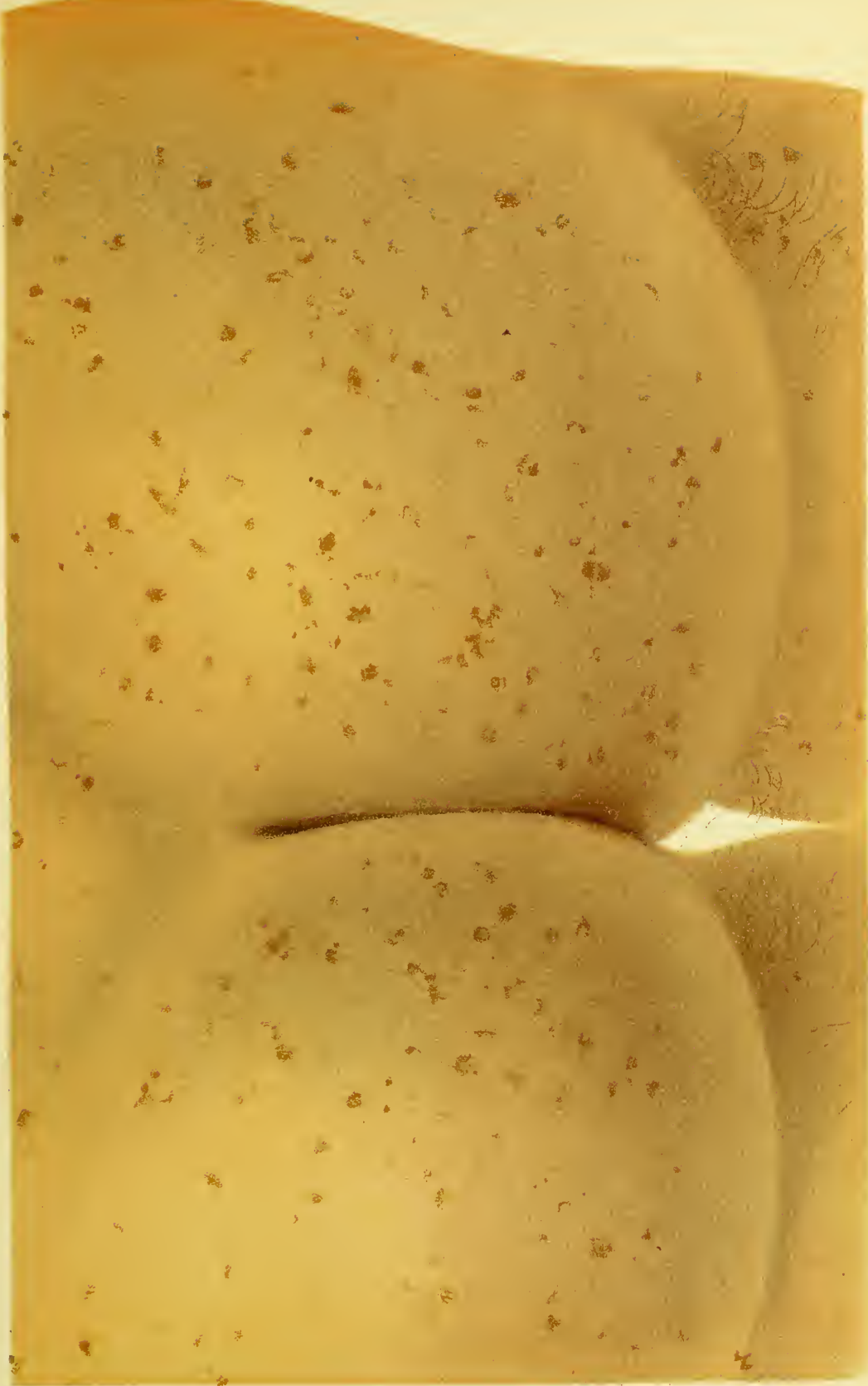






TAFEL 154.  
Lentigo — Ephelis (nates).





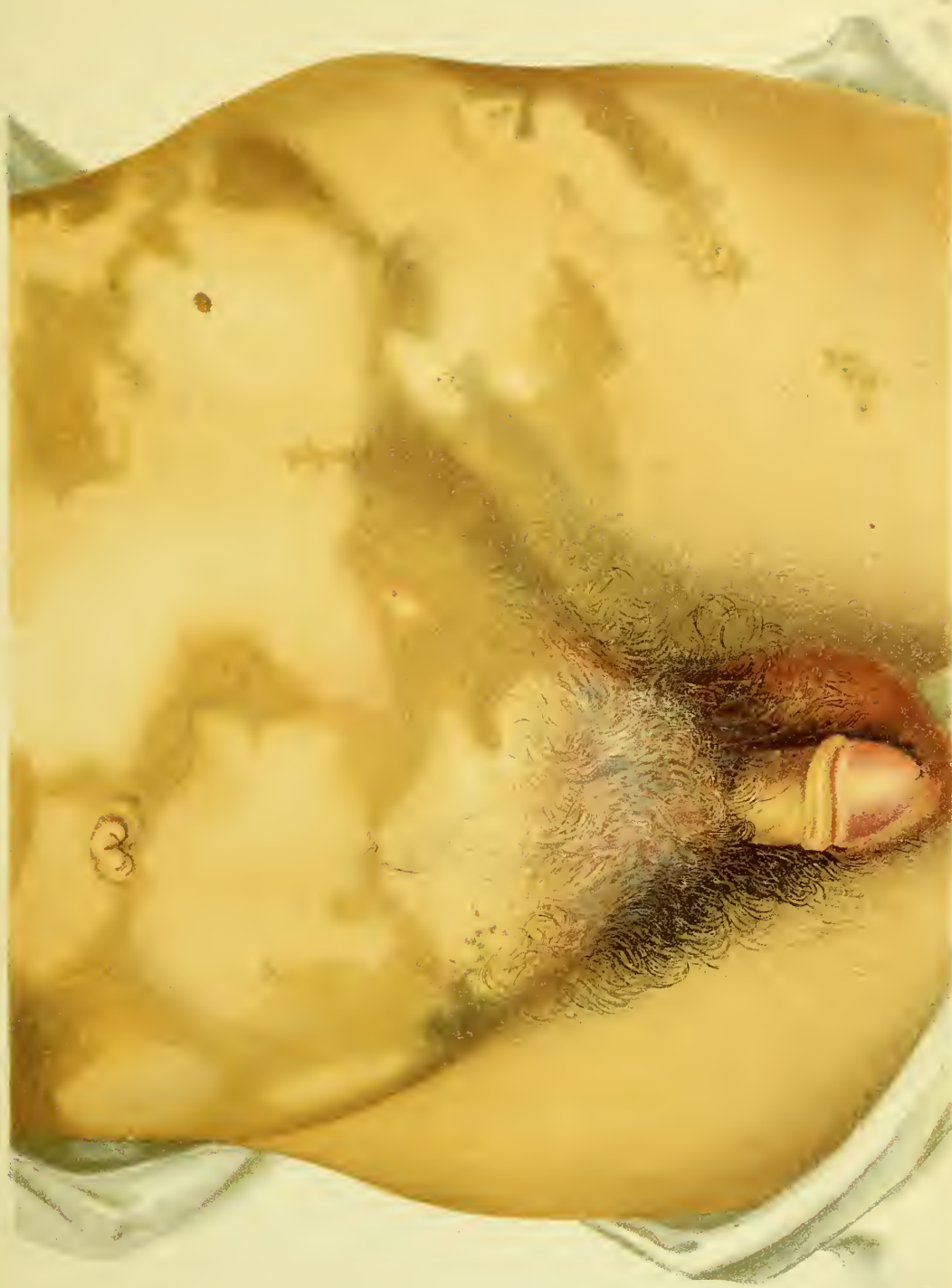

TAFEL 155.

Leukoderma acquisita — Vitiligo — Poliosis, Achromatia  
acquisita.





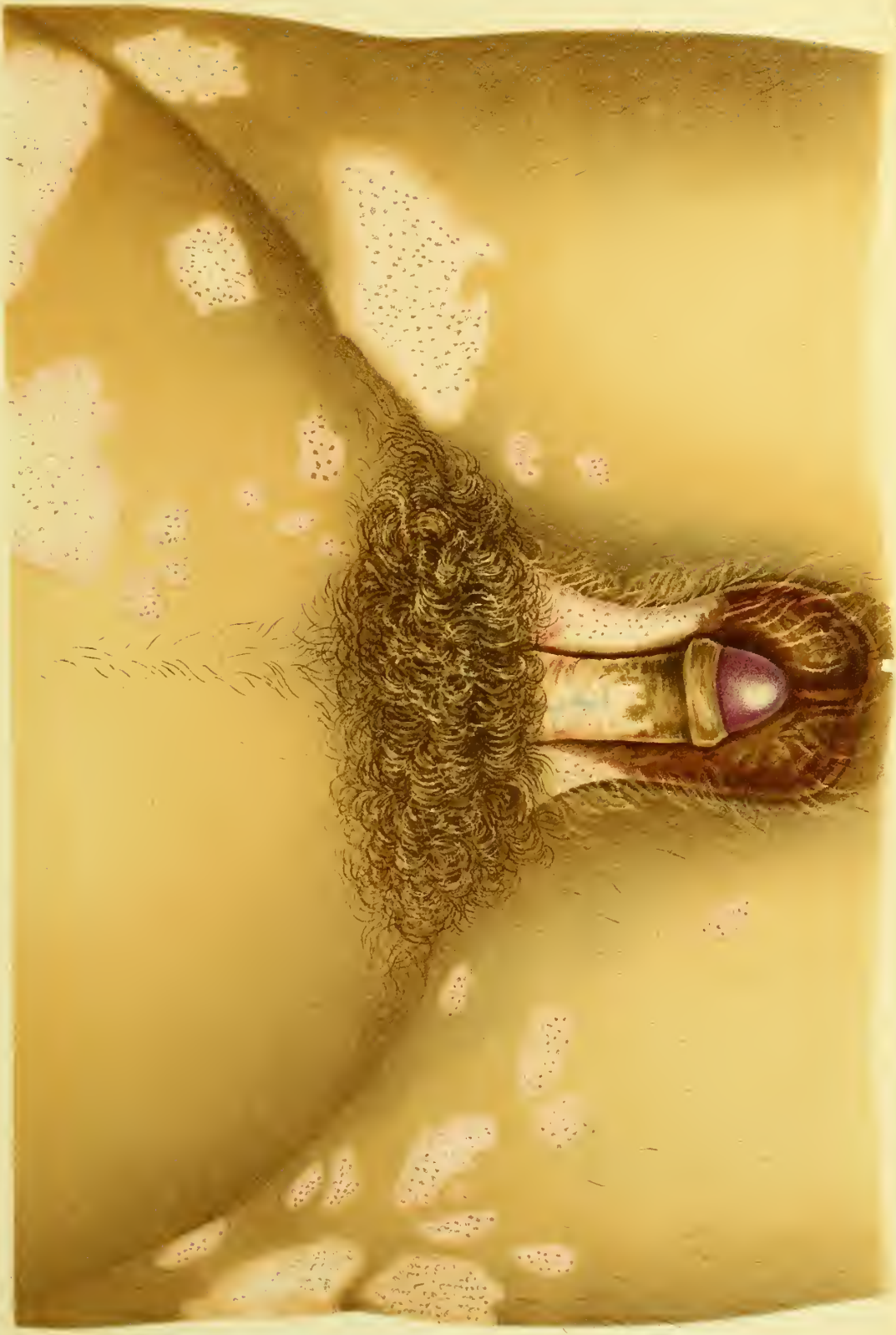



TAFEL 156.

Leukoderma -- Vitiligo -- Poliosis, Achromatia acquisita.







TAFEL 157.

**Leukoderma syphiliticum — Pigment. Syphilis.**





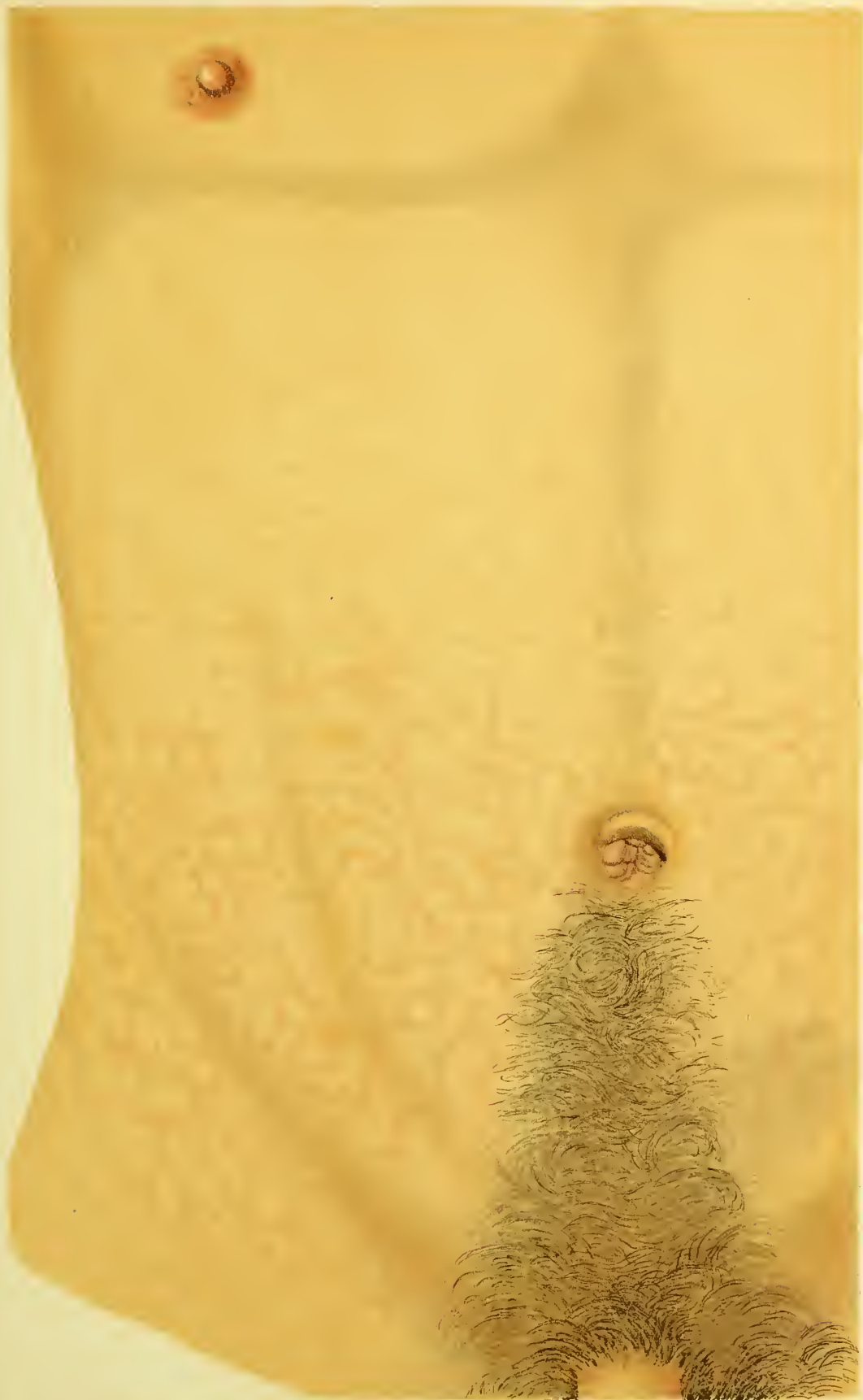



TAFEL 158.

**Leukoderma syphiliticum — Pigment. Syphilis.**







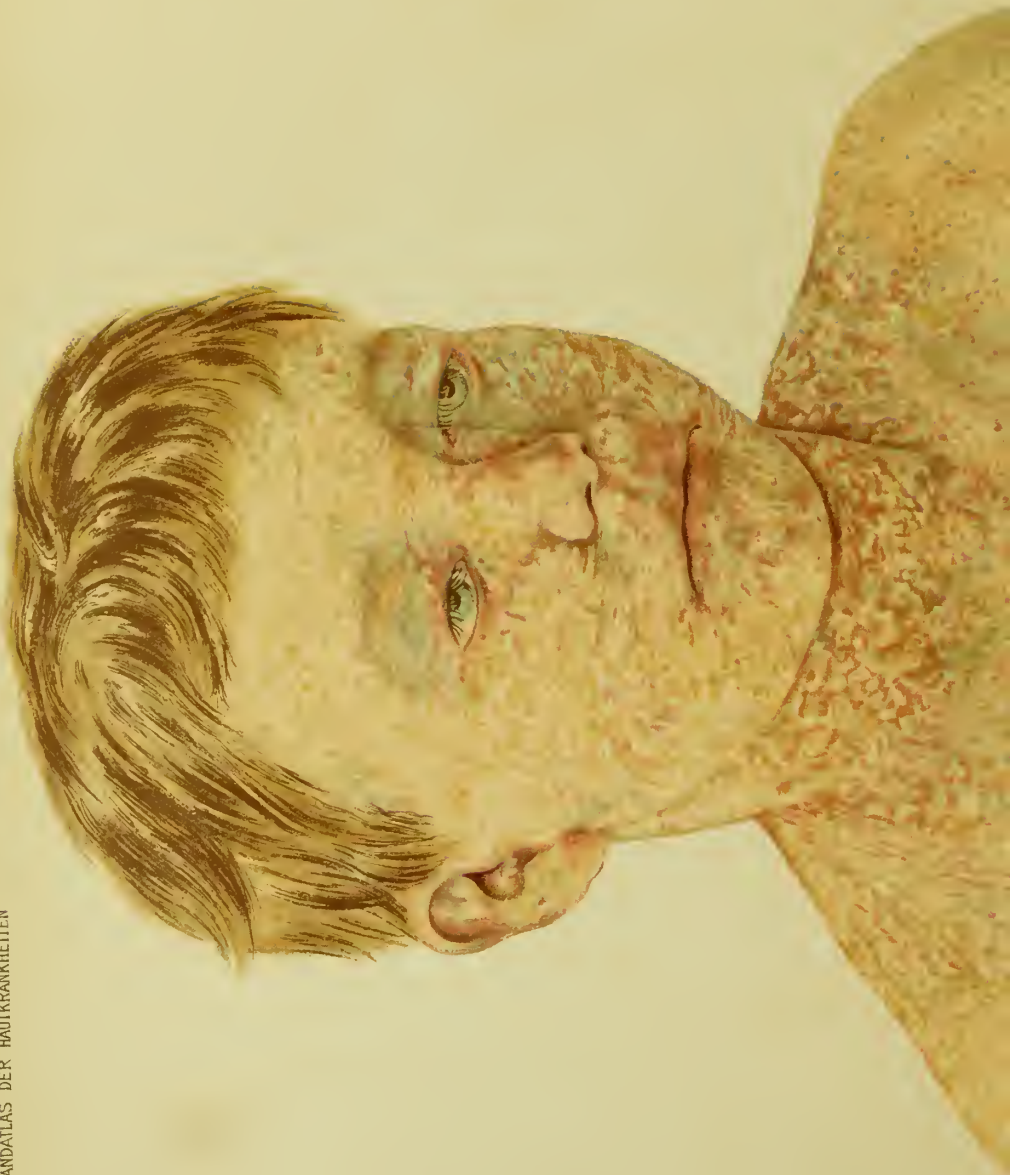

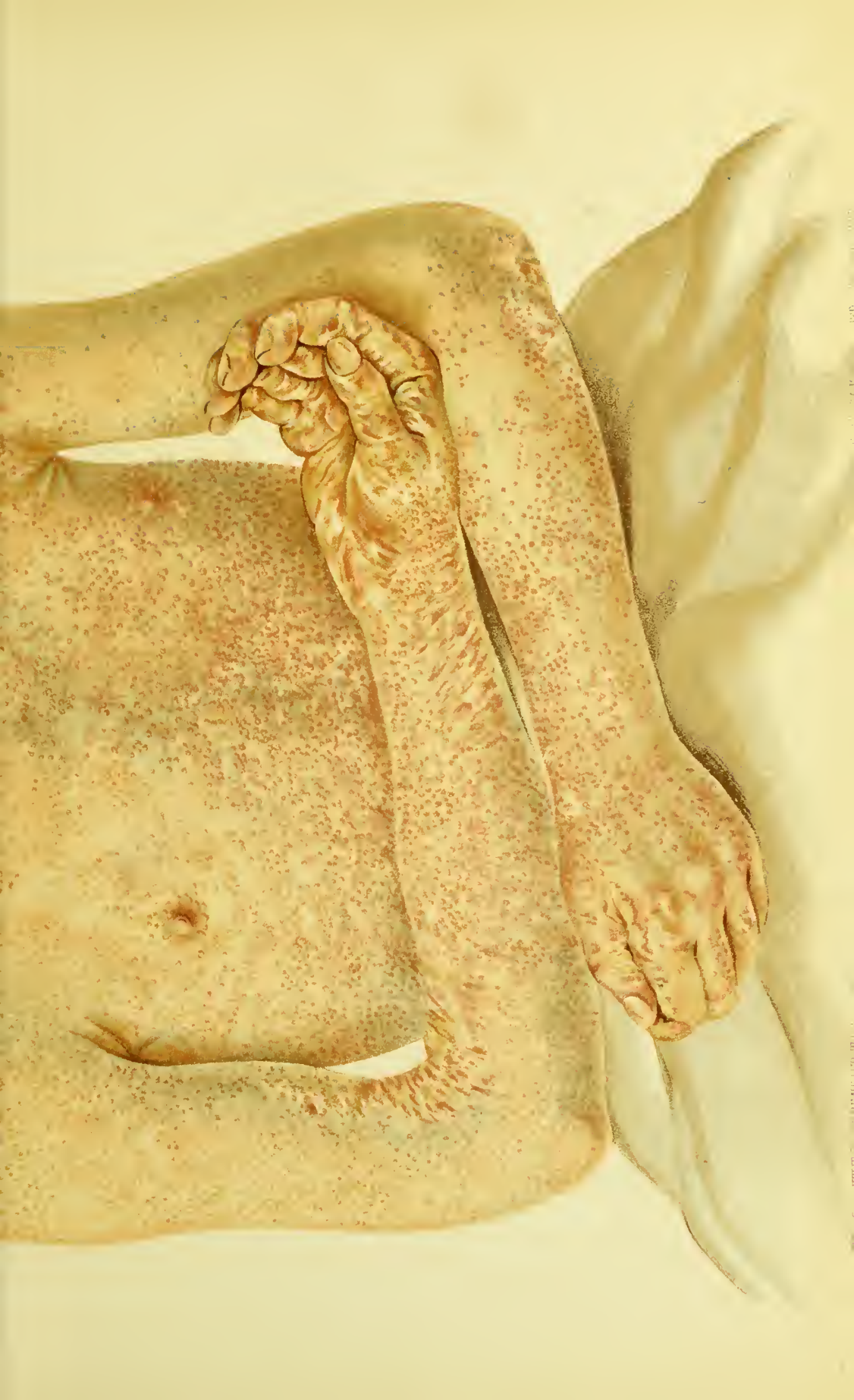TAFEL 159.

**Lichen ruber acuminatus.**











TAFEL 160.

Lichen ruber acuminatus.



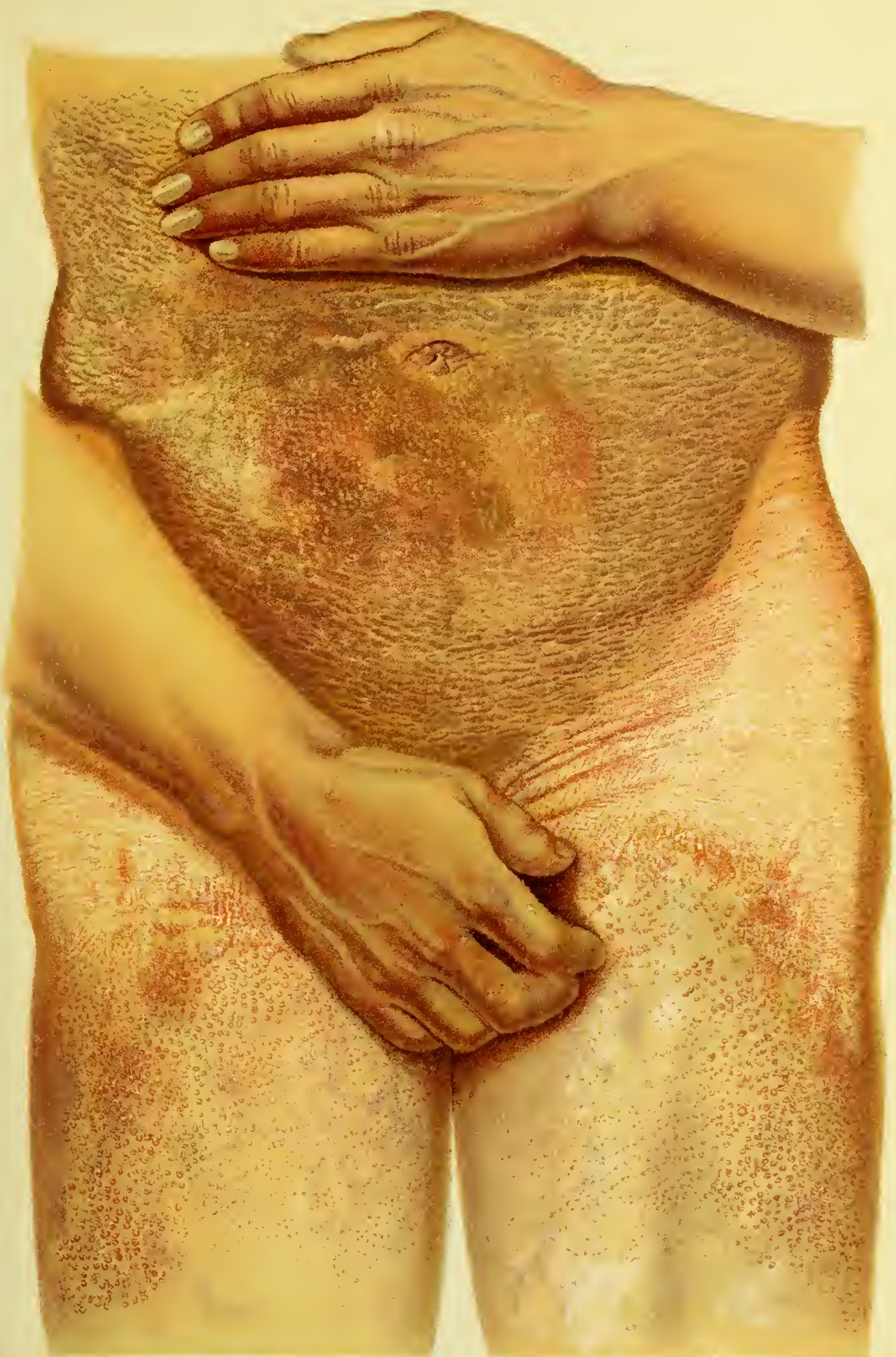






TAFEL 161.  
Lichen ruber acuminatus.







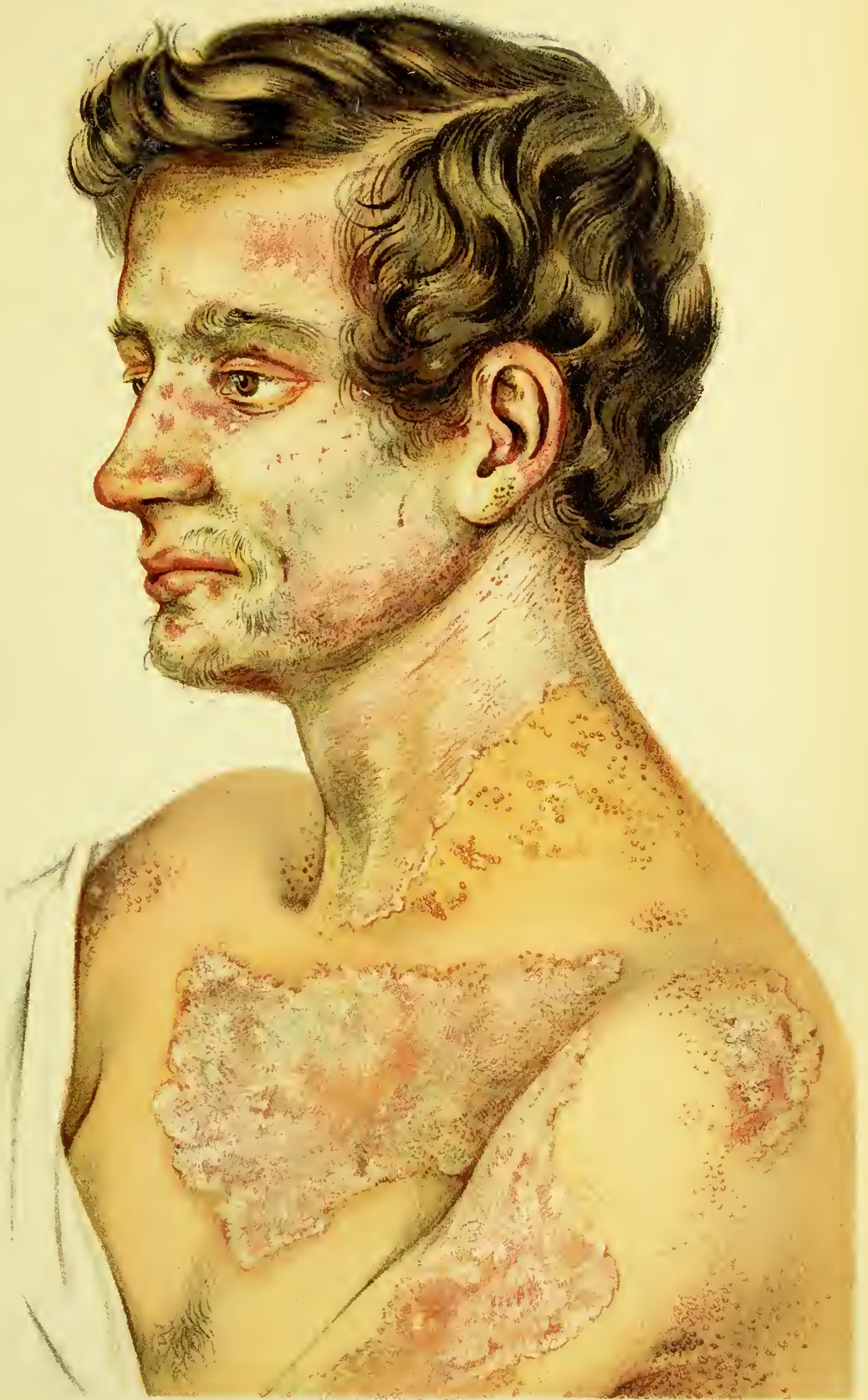


TAFEL 162.

**Lichen ruber acuminatus.**







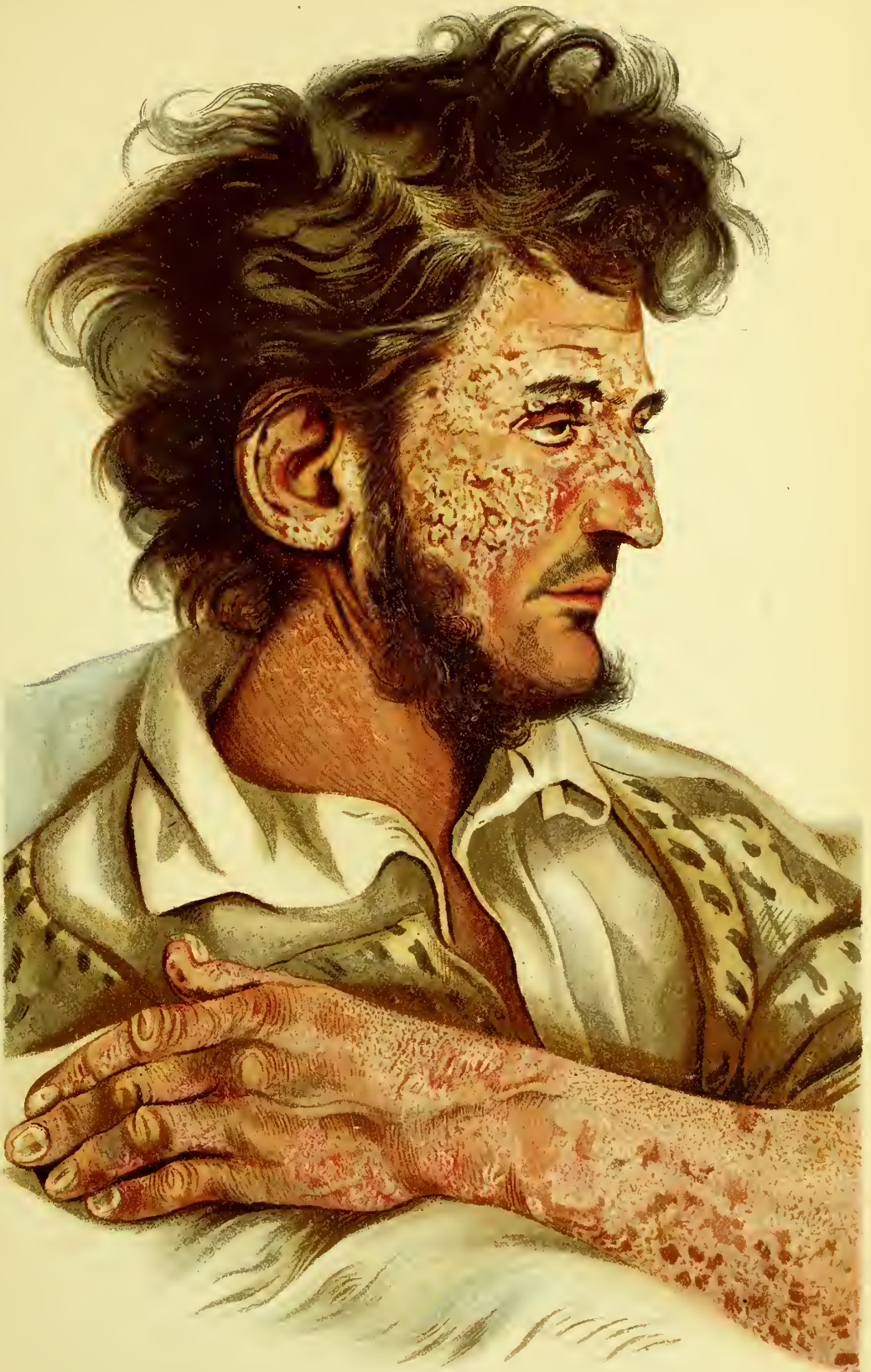

TAFEL 163.

Lichen ruber acuminatus.







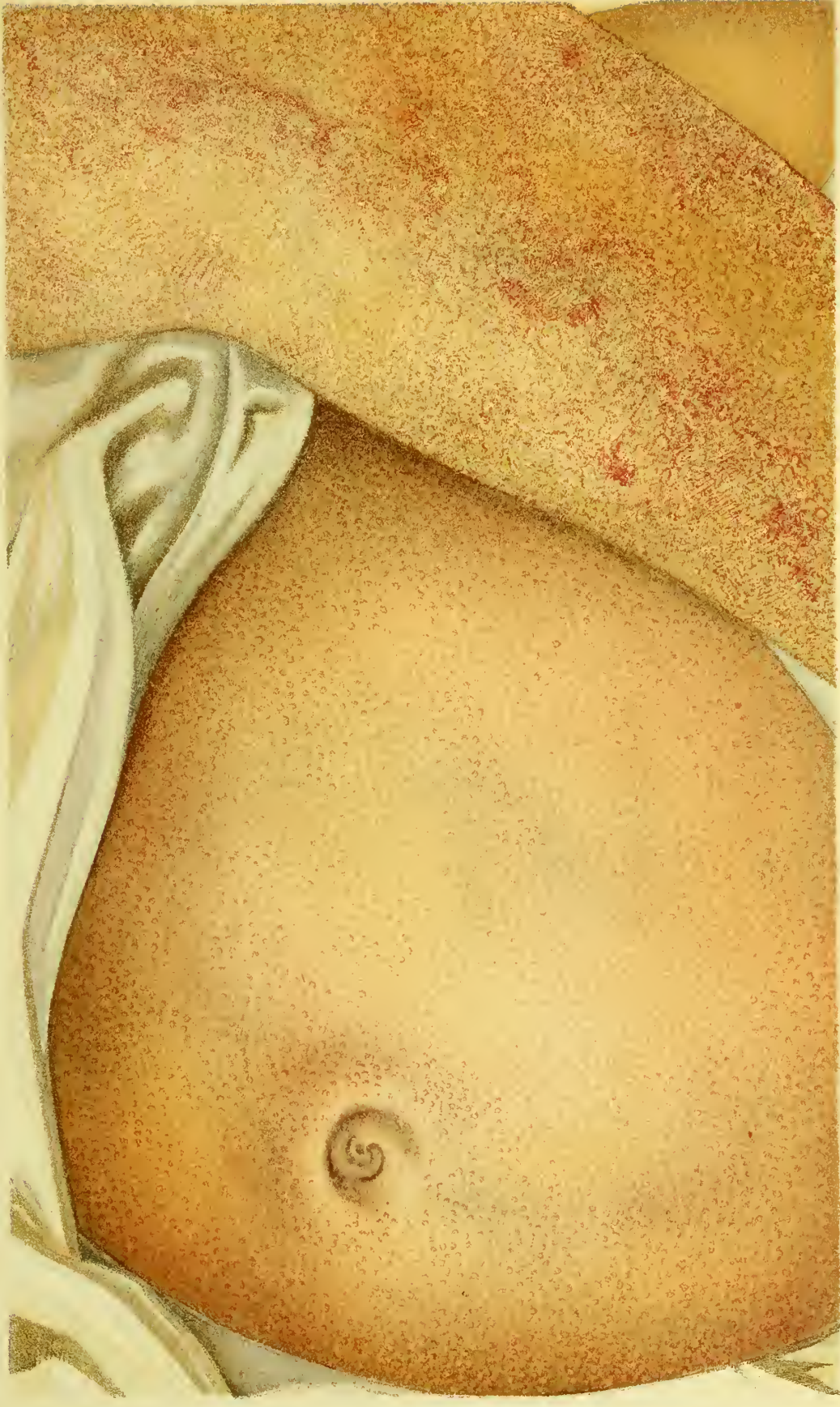

TAFEL 164.

Lichen ruber acuminatus.







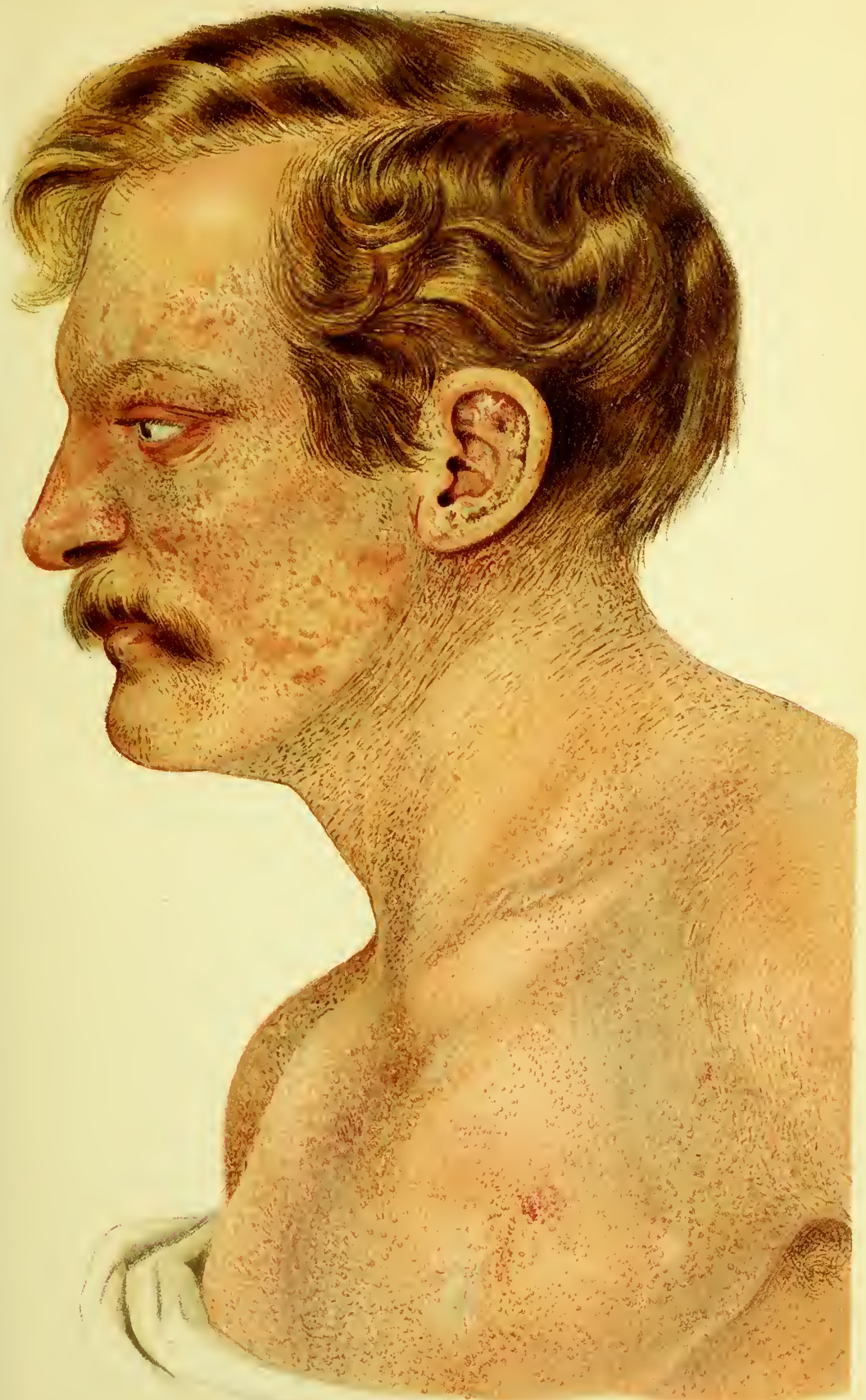

TAFEL 165.

Lichen ruber acuminatus.







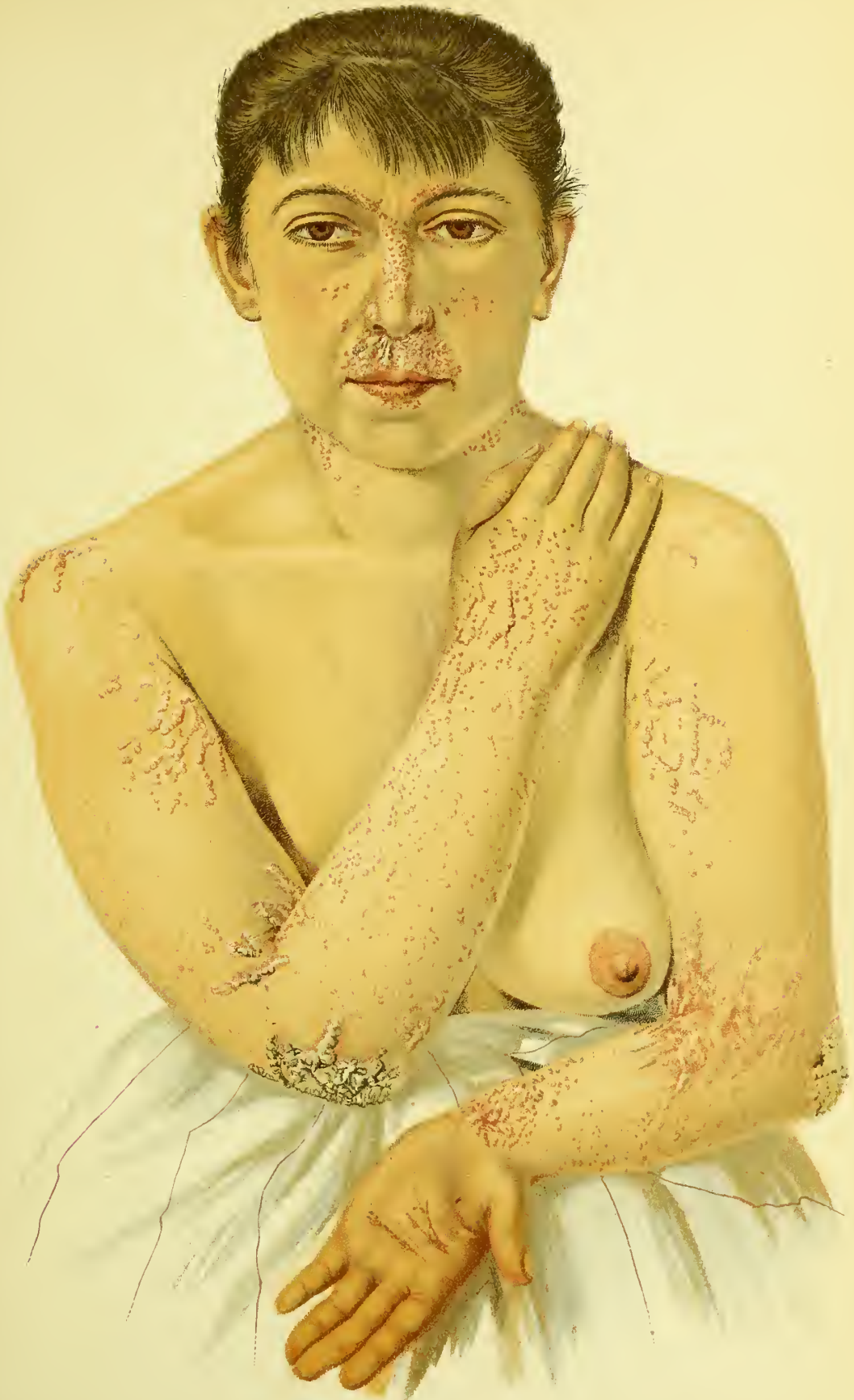



TAFEL 166.

Lichen ruber acuminatus verrucosus et reticularis.



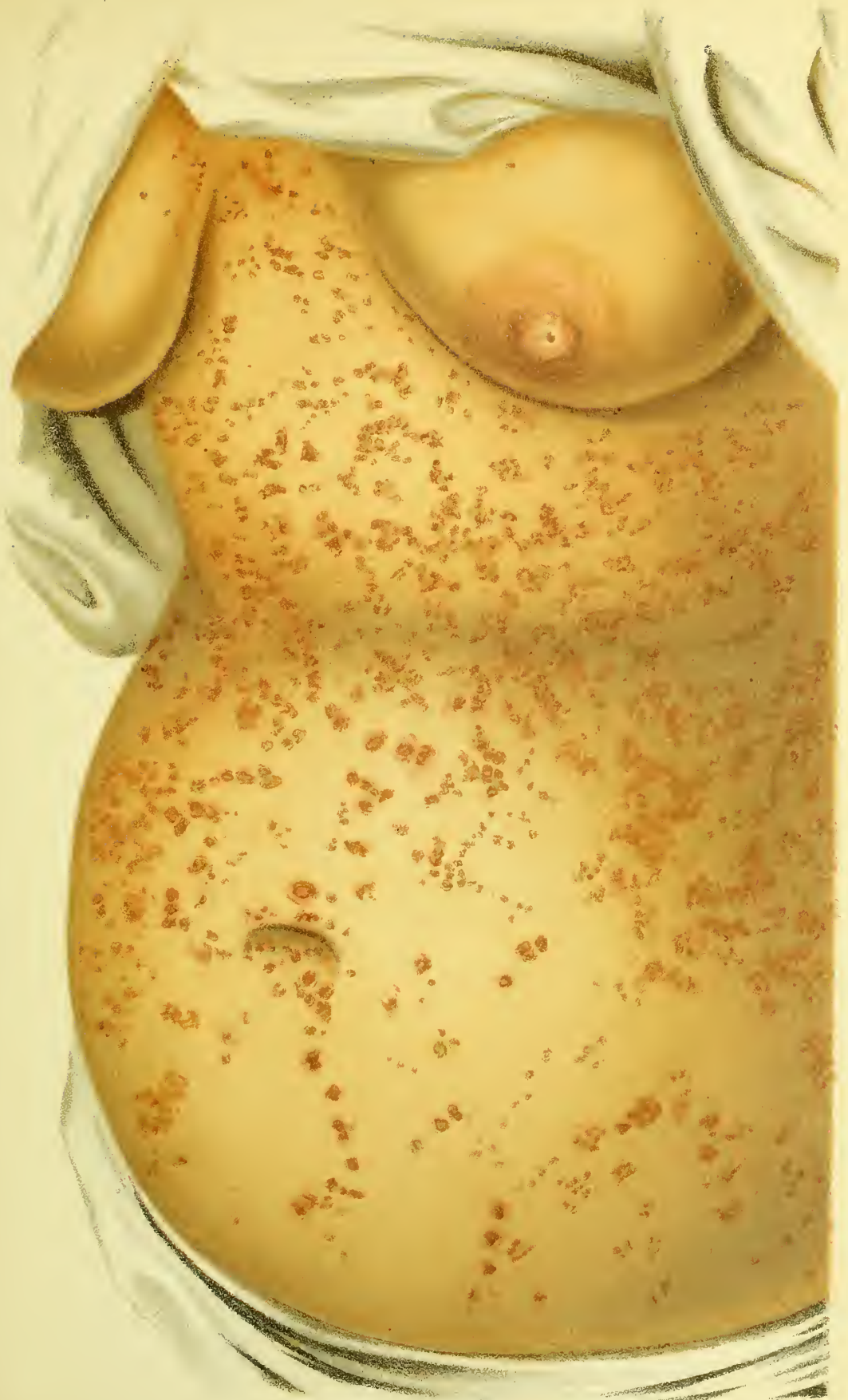



TAFEL 167.

Lichen ruber planus (vorderer Stamm).







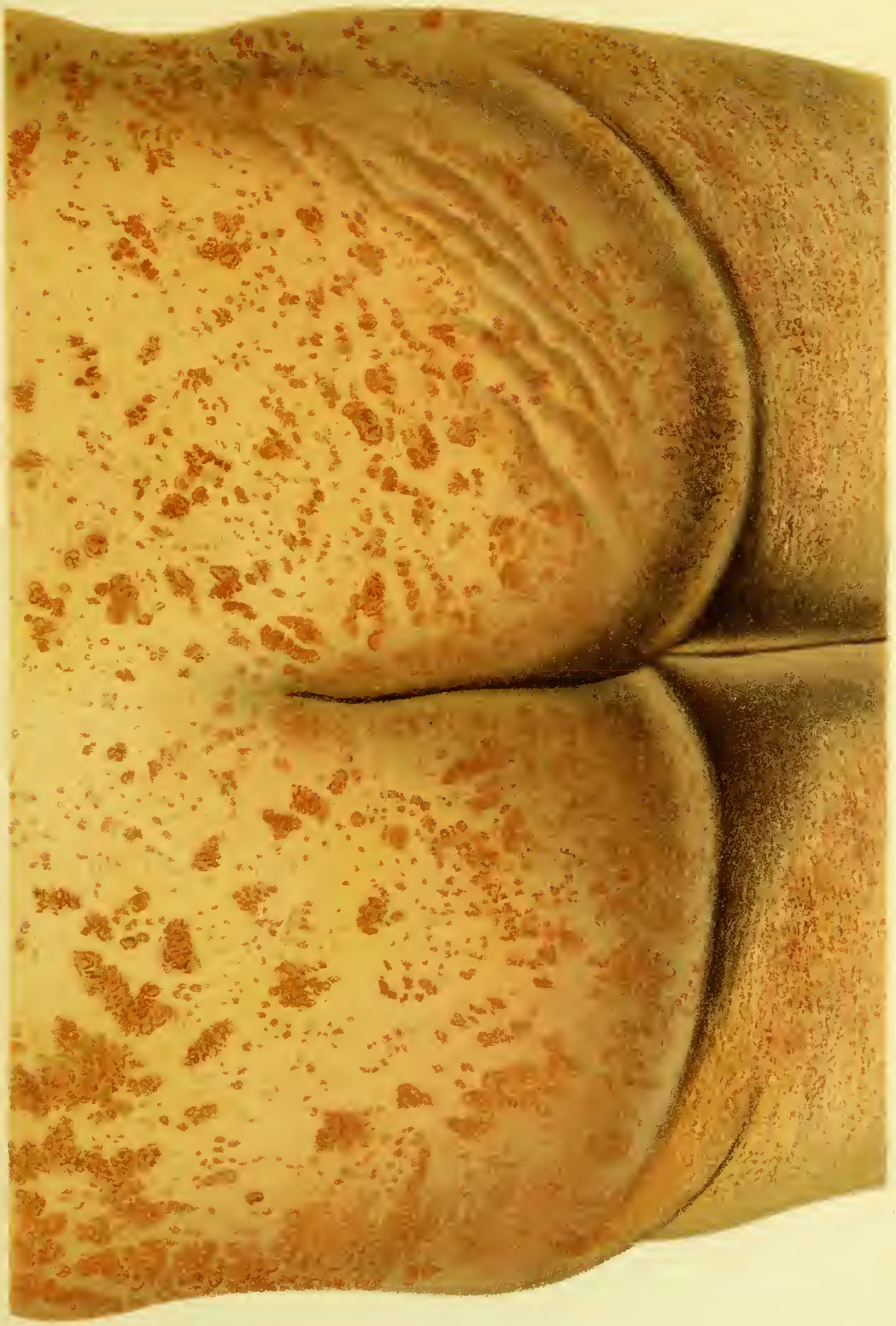

TAFEL 168.

**Lichen ruber planus**

(Nates, der Patientin von Taf. 167 zugehörig).





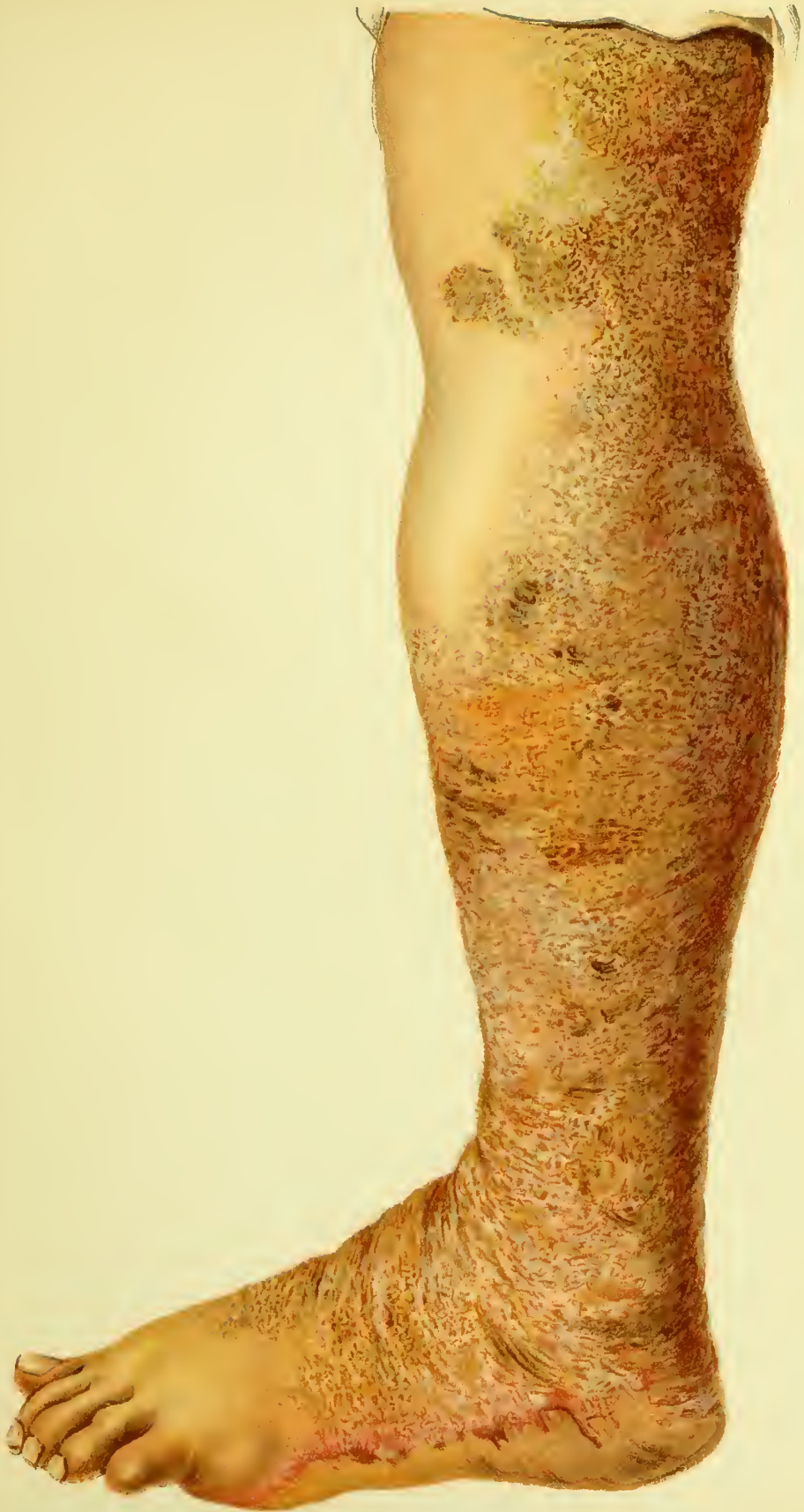

TAFEL 169.

**Lichen ruber planus extremitat. inferiorum**  
(diffuse präcursorische Röthung, zu Taf. 167 u. 168 gehörig).







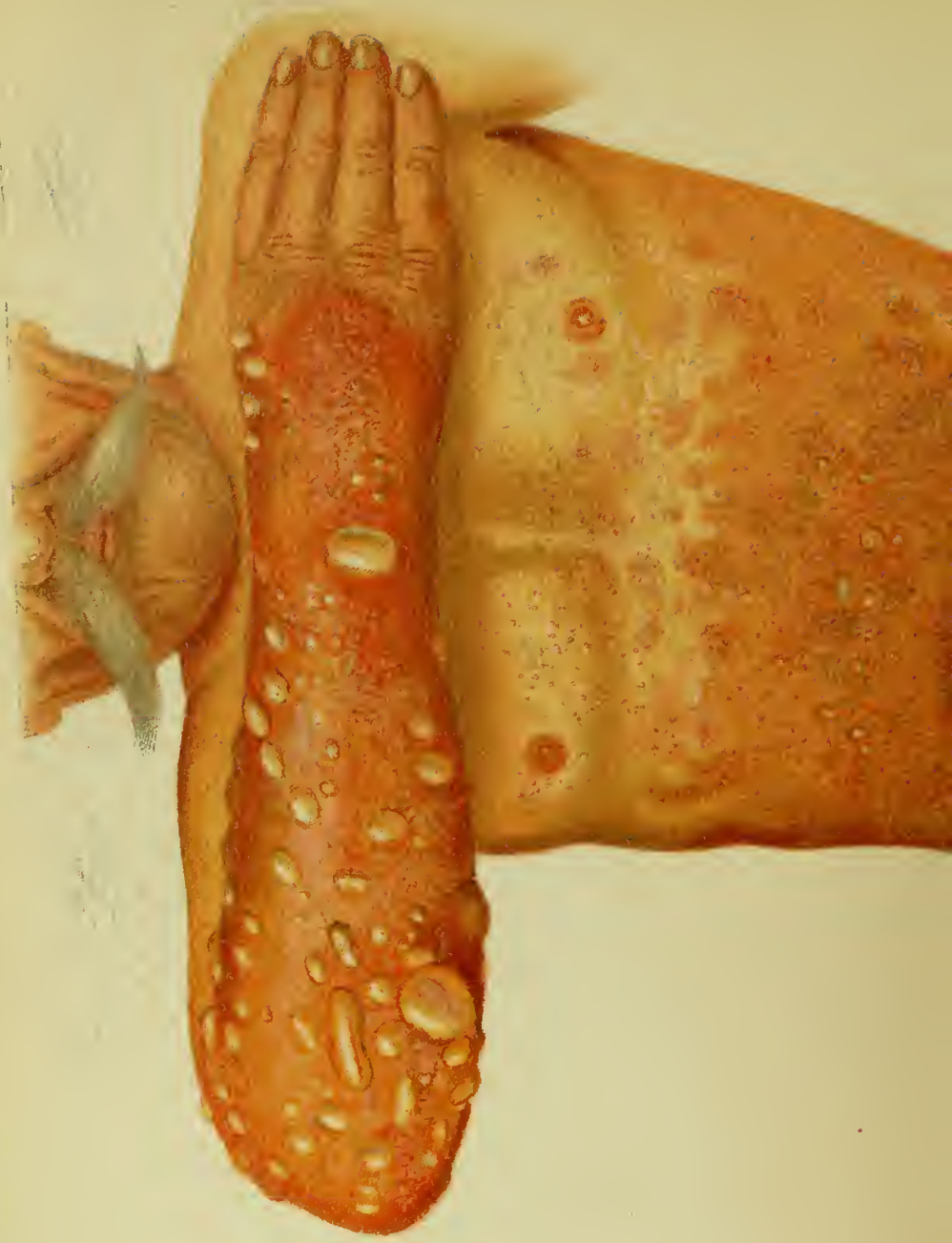


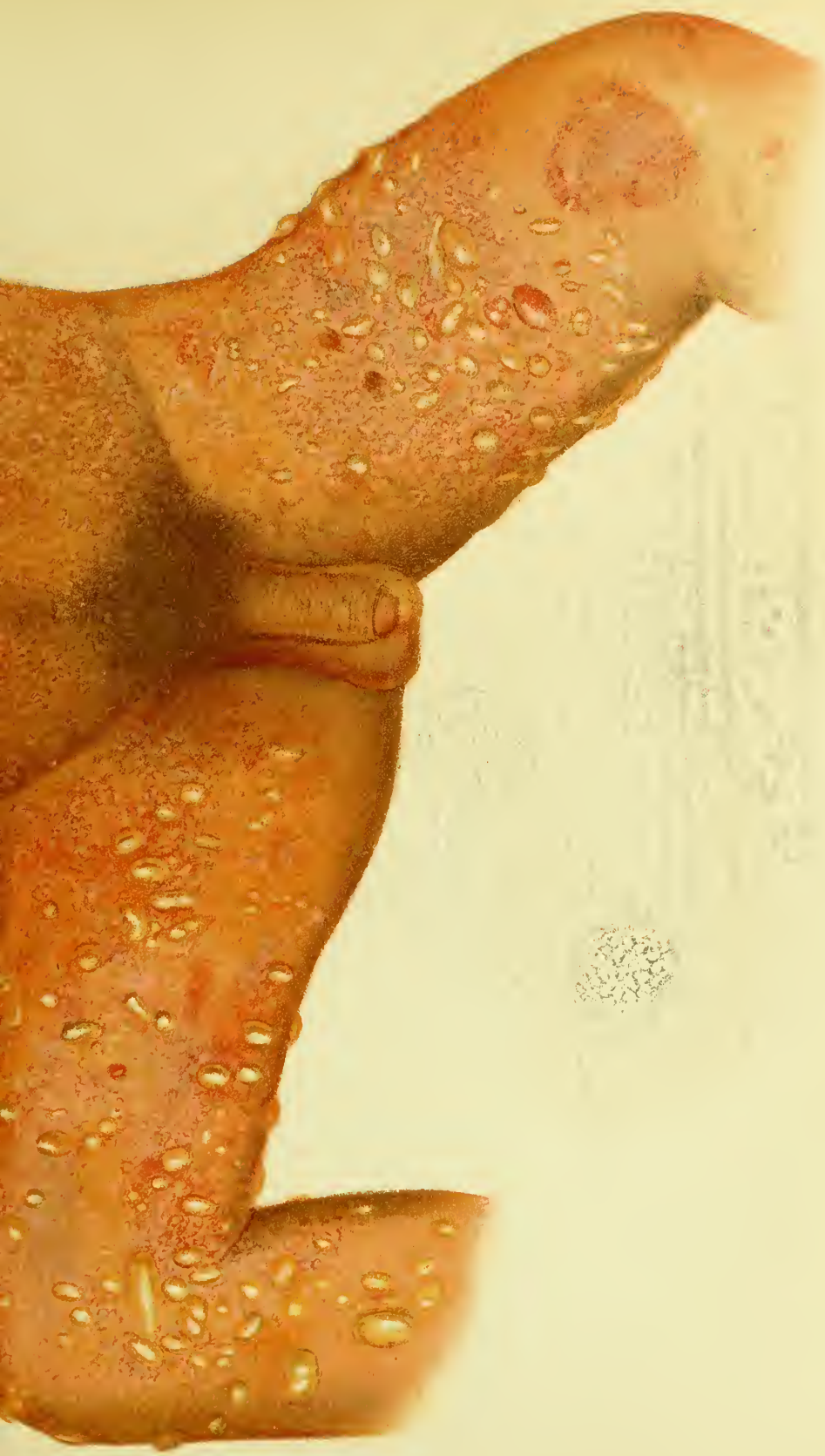TAFEL 170.

Lichen ruber planus acutissimus pemphygoides — mihi.









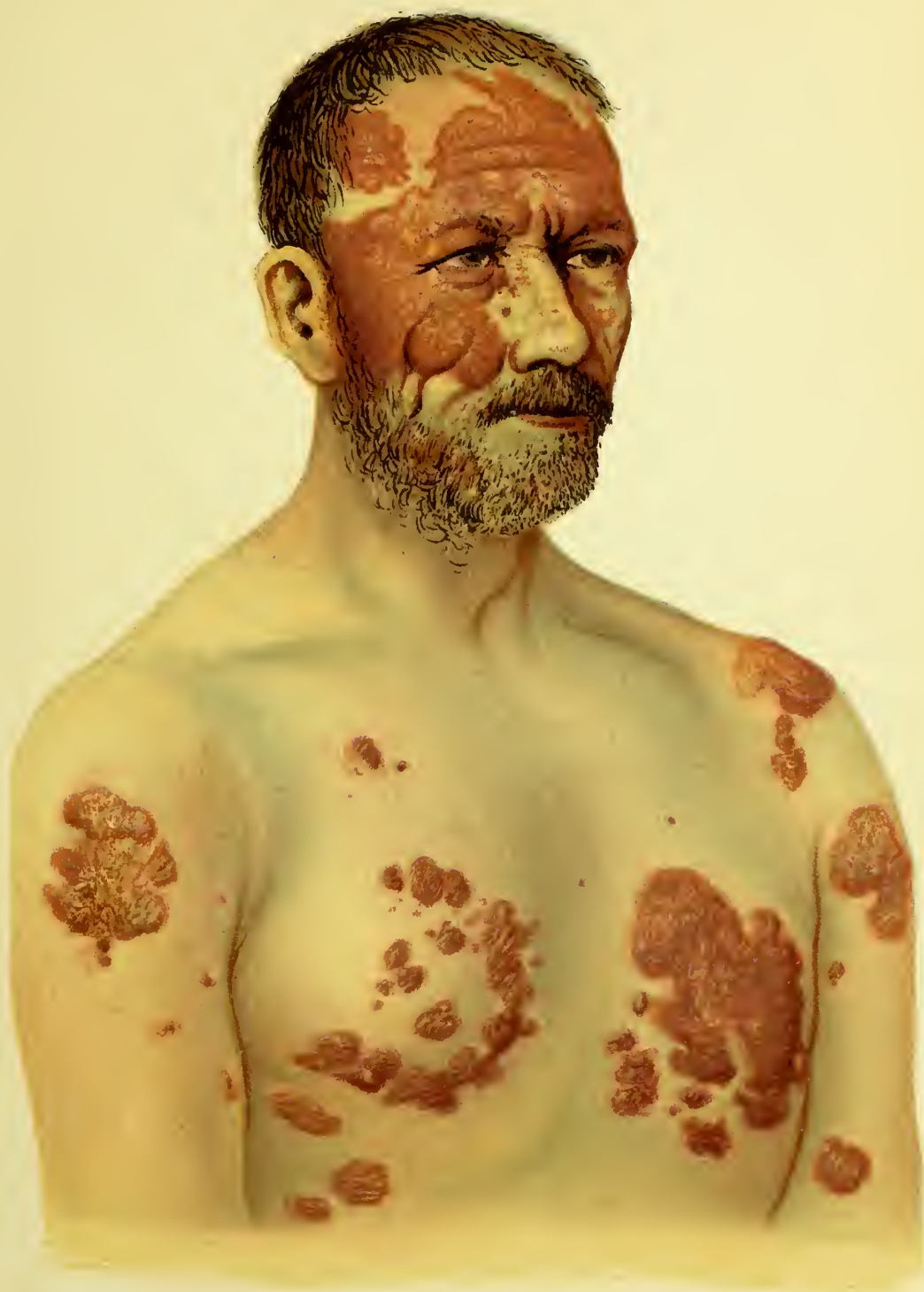



TAFEL 171.

Lichen ruber planus exuberans (en plaques).





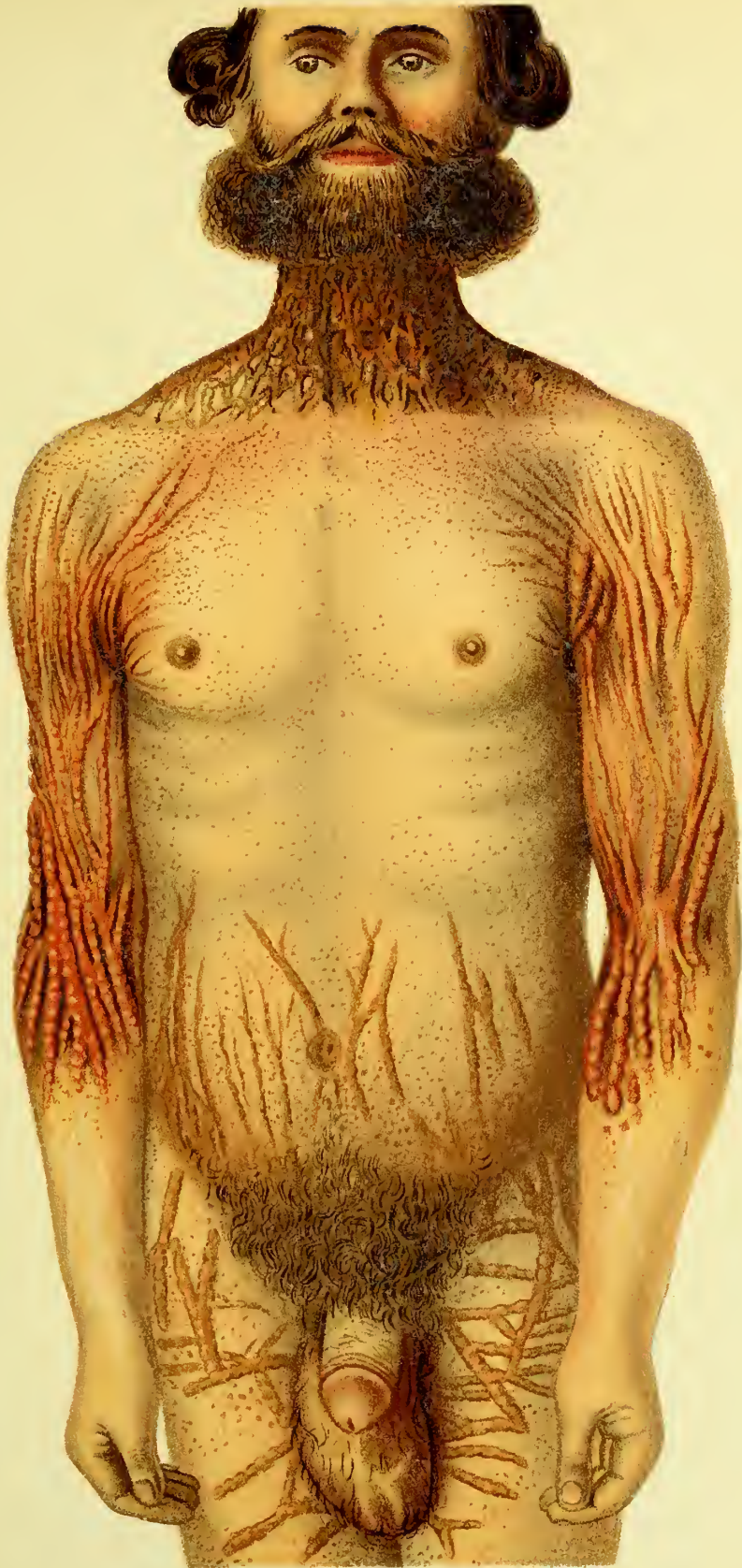


TAFEL 172.

Lichen ruber planus moniliformis — mihi.







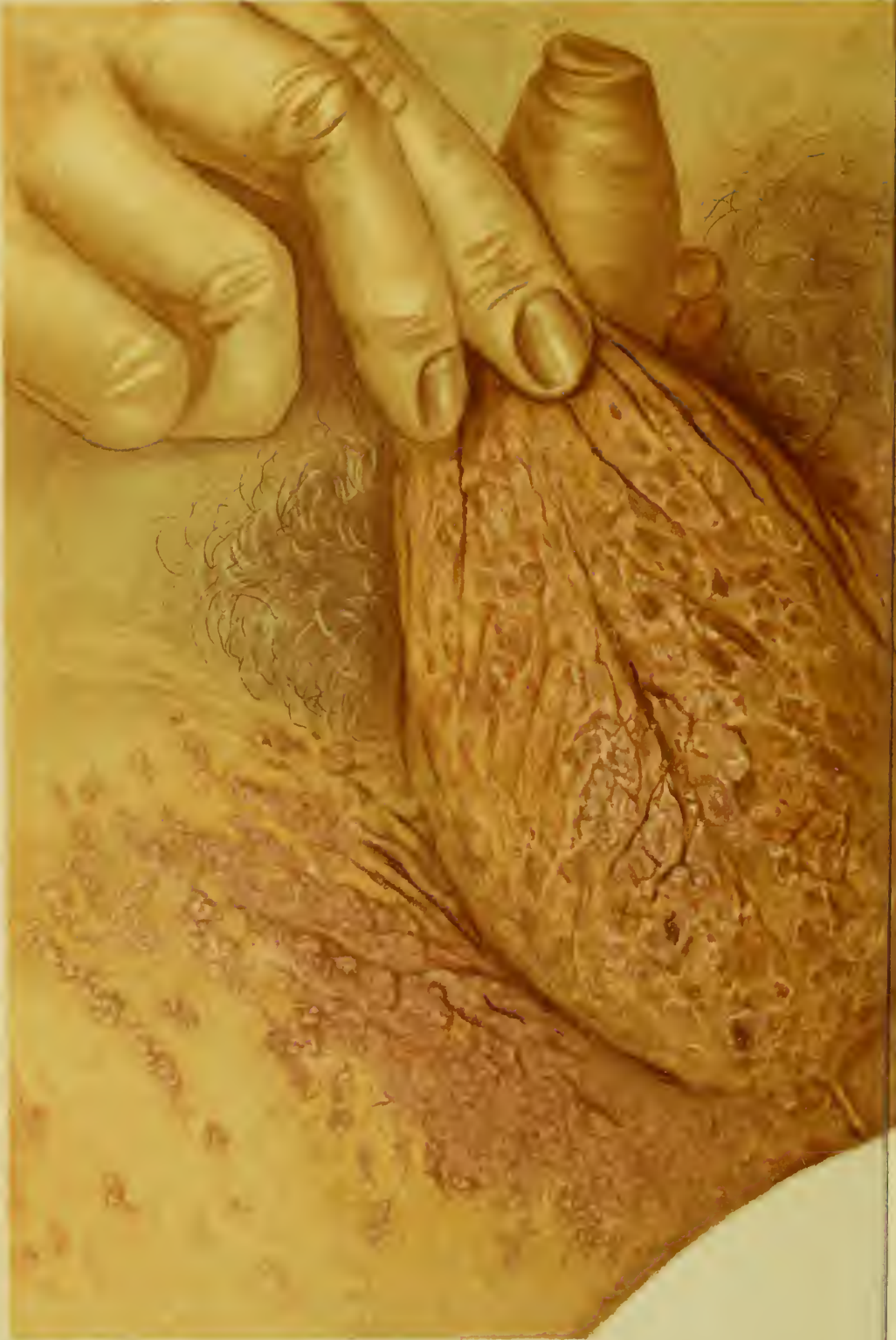


TAFEL 173.

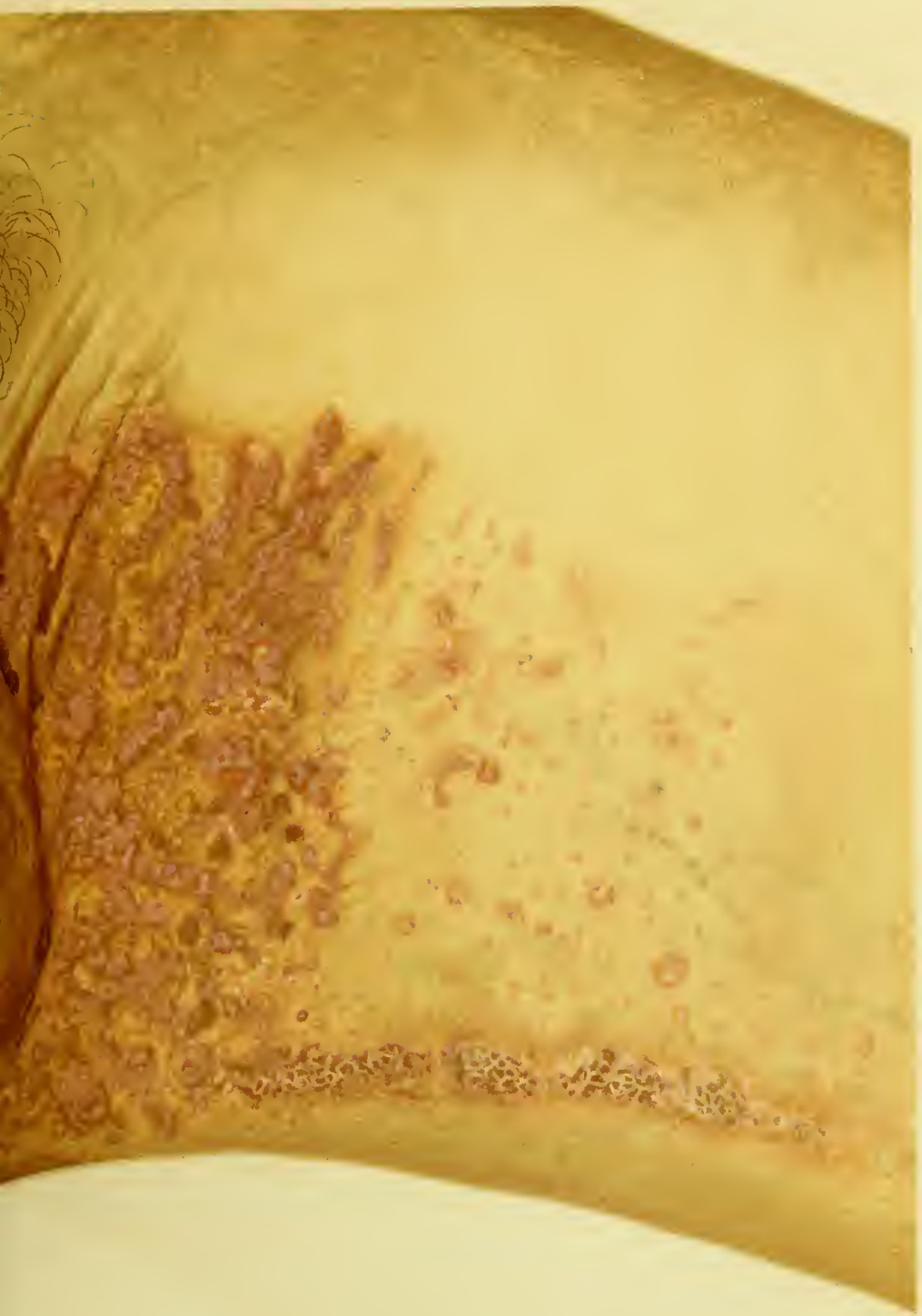
Lichen ruber planus Scroti, inguinis et linearis femoris.











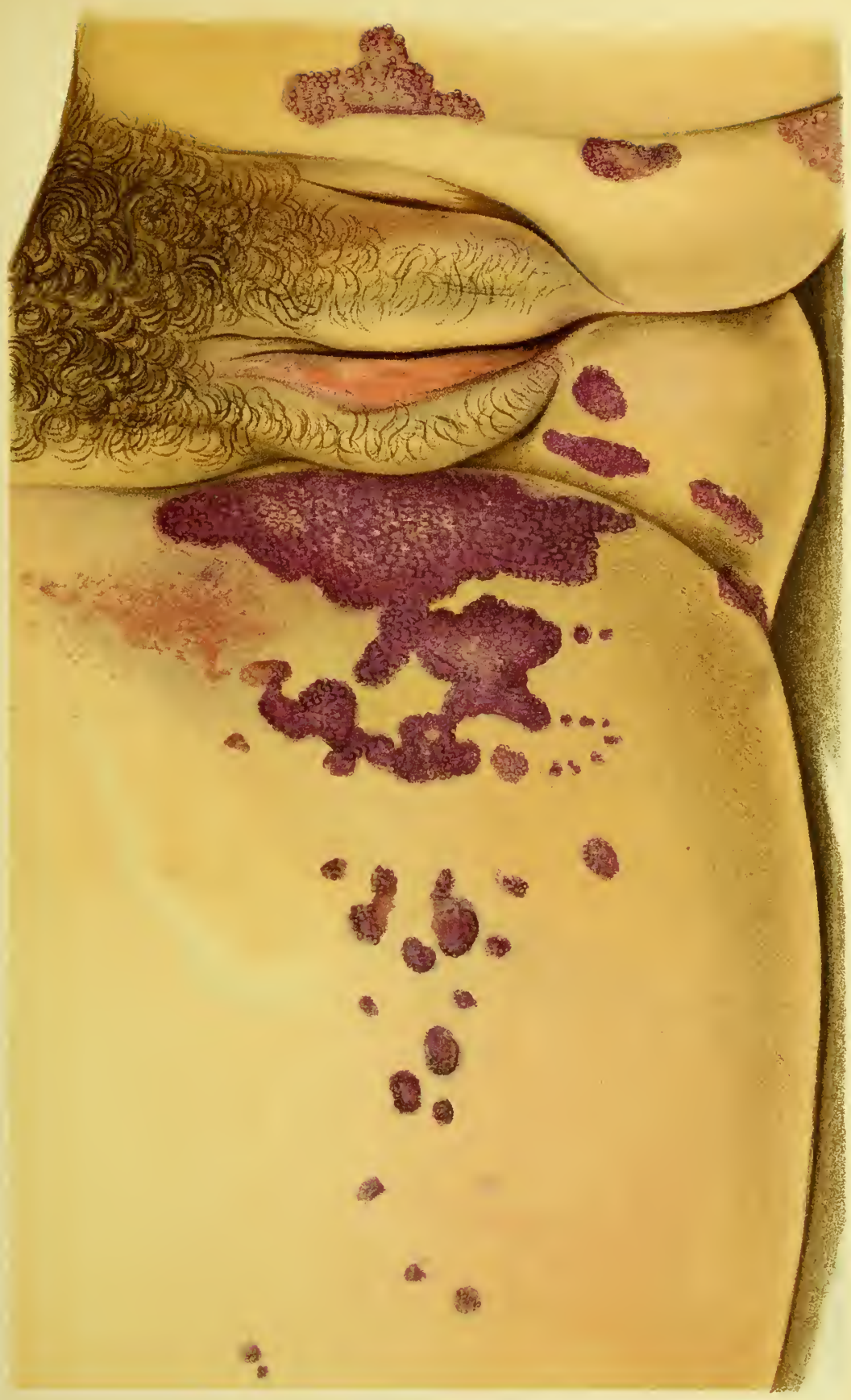



TAFEL 174.

Lichen ruber. planus plicae inguinalis in femina.



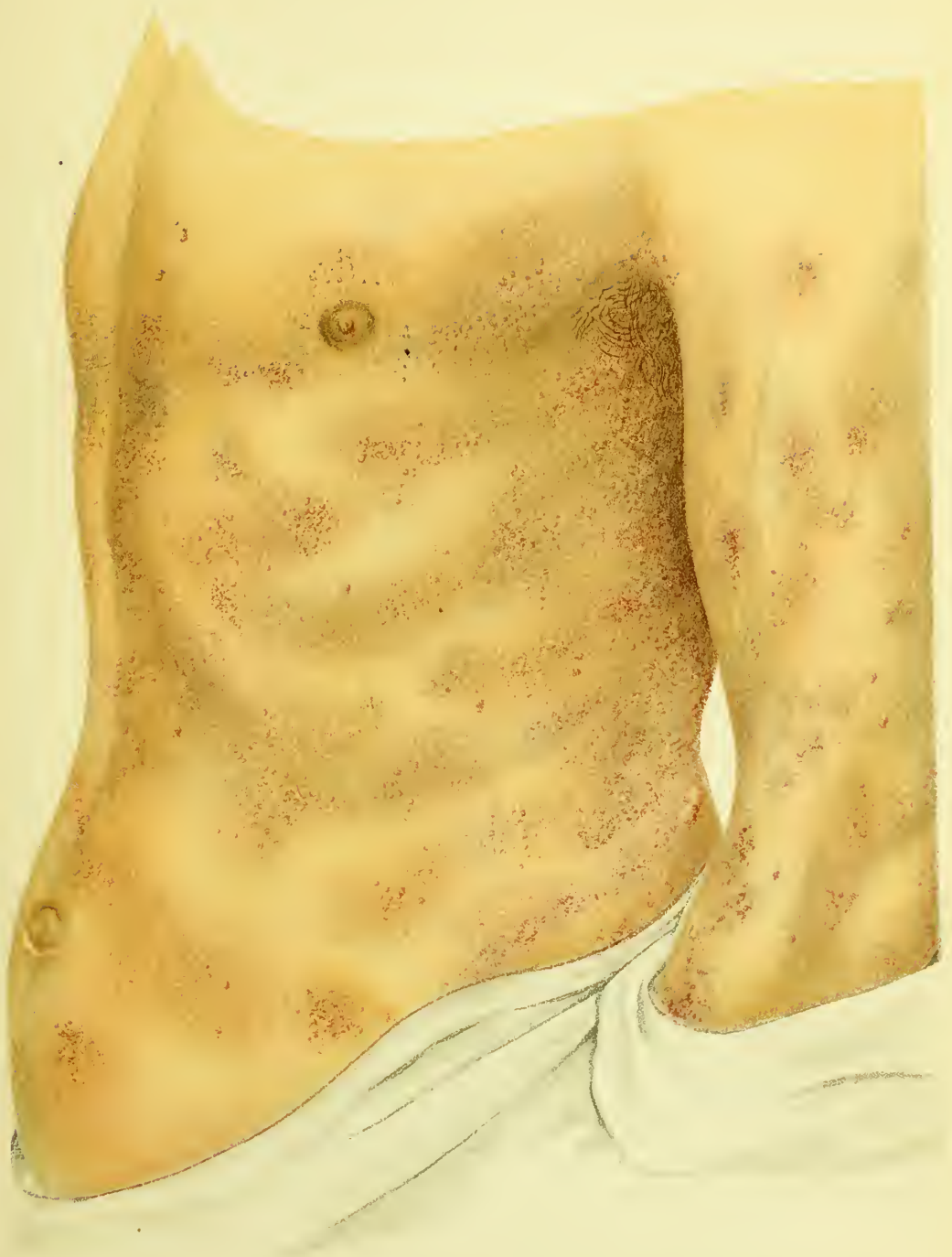



TAFEL 175.

Lichen scrophulosorum trunci.





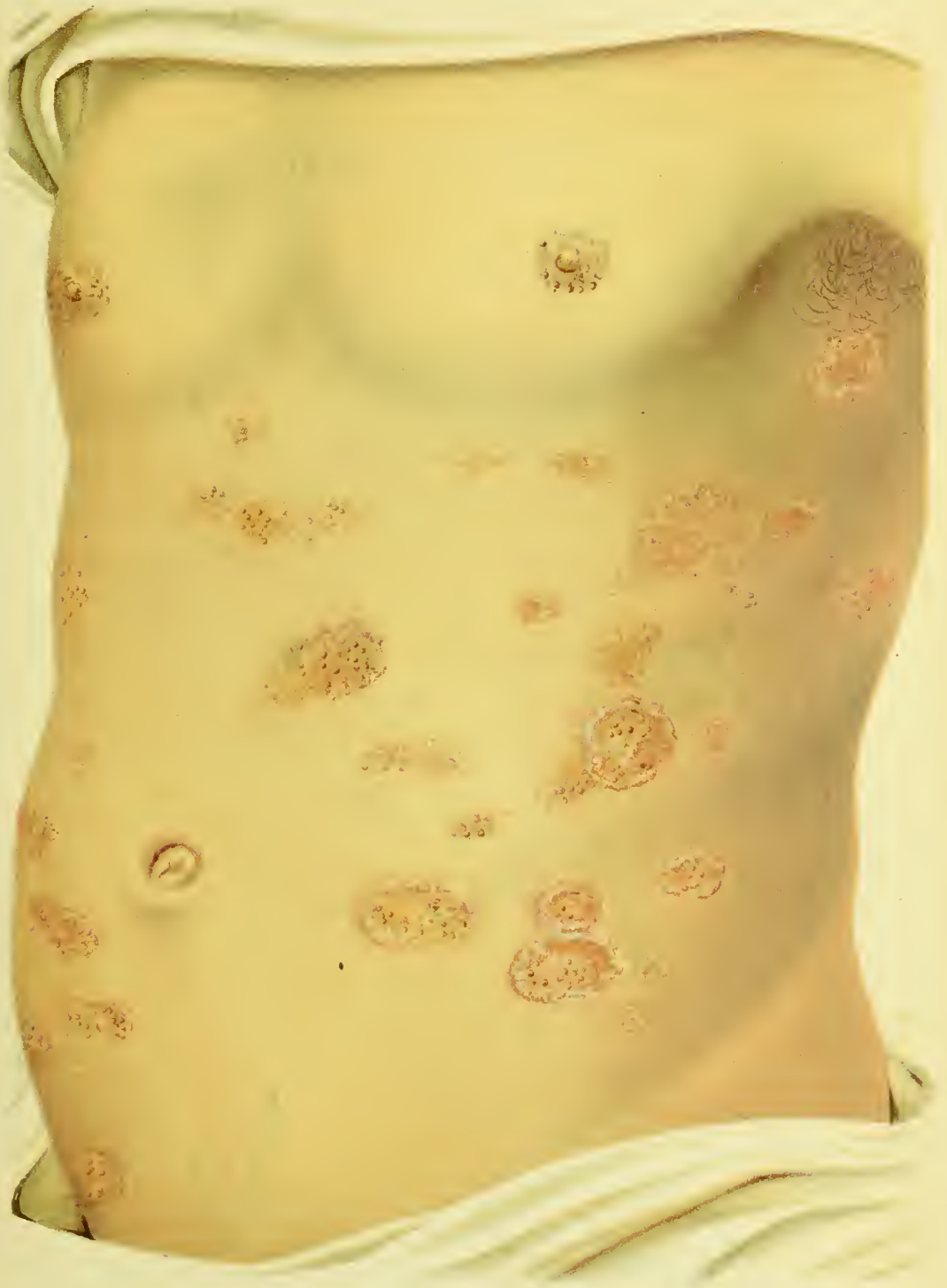




TAFEL 176.

Lichen scrophulosorum trunci.



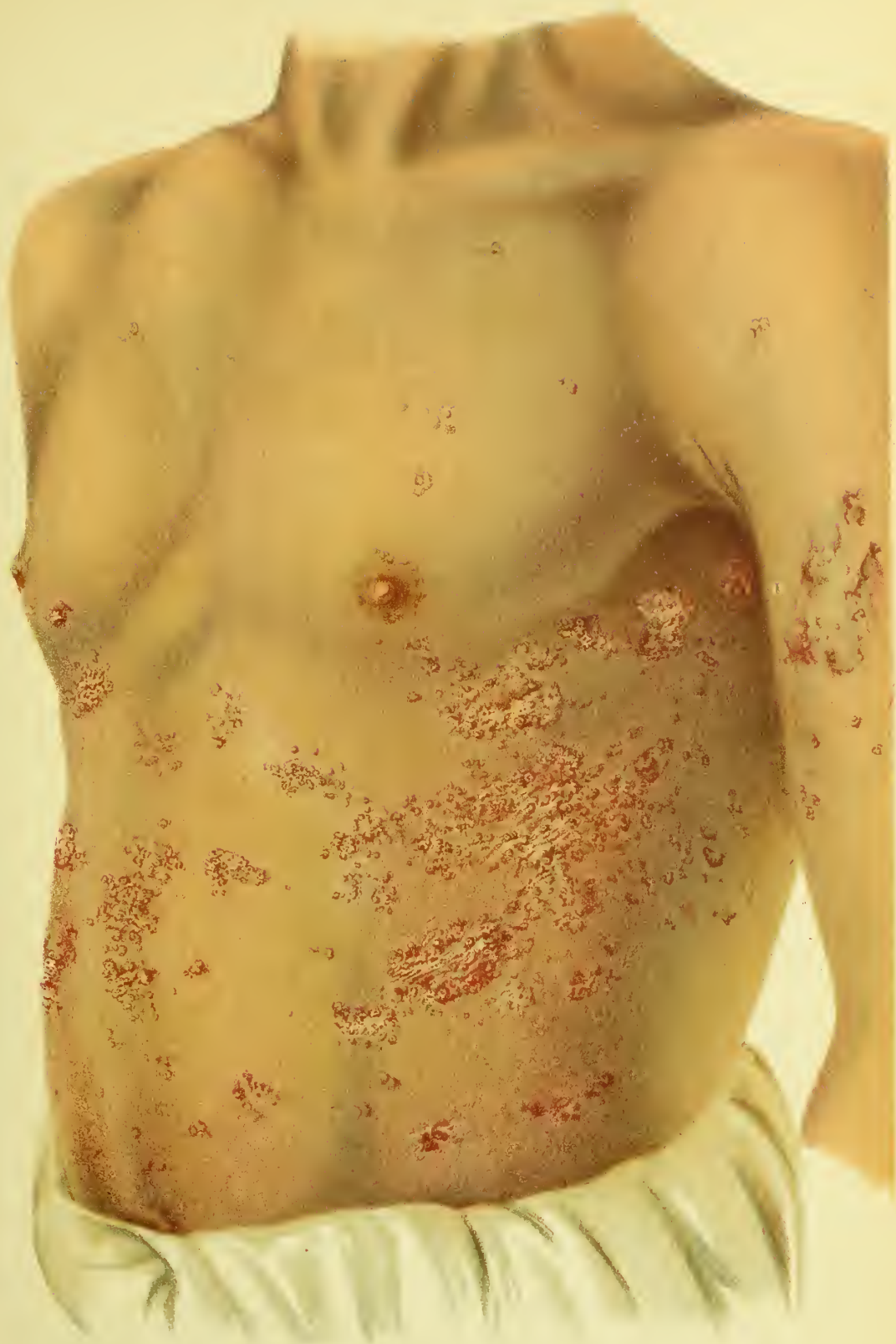



TAFEL 177.

Lichen scrophulosorum et Acne cachecticorum.



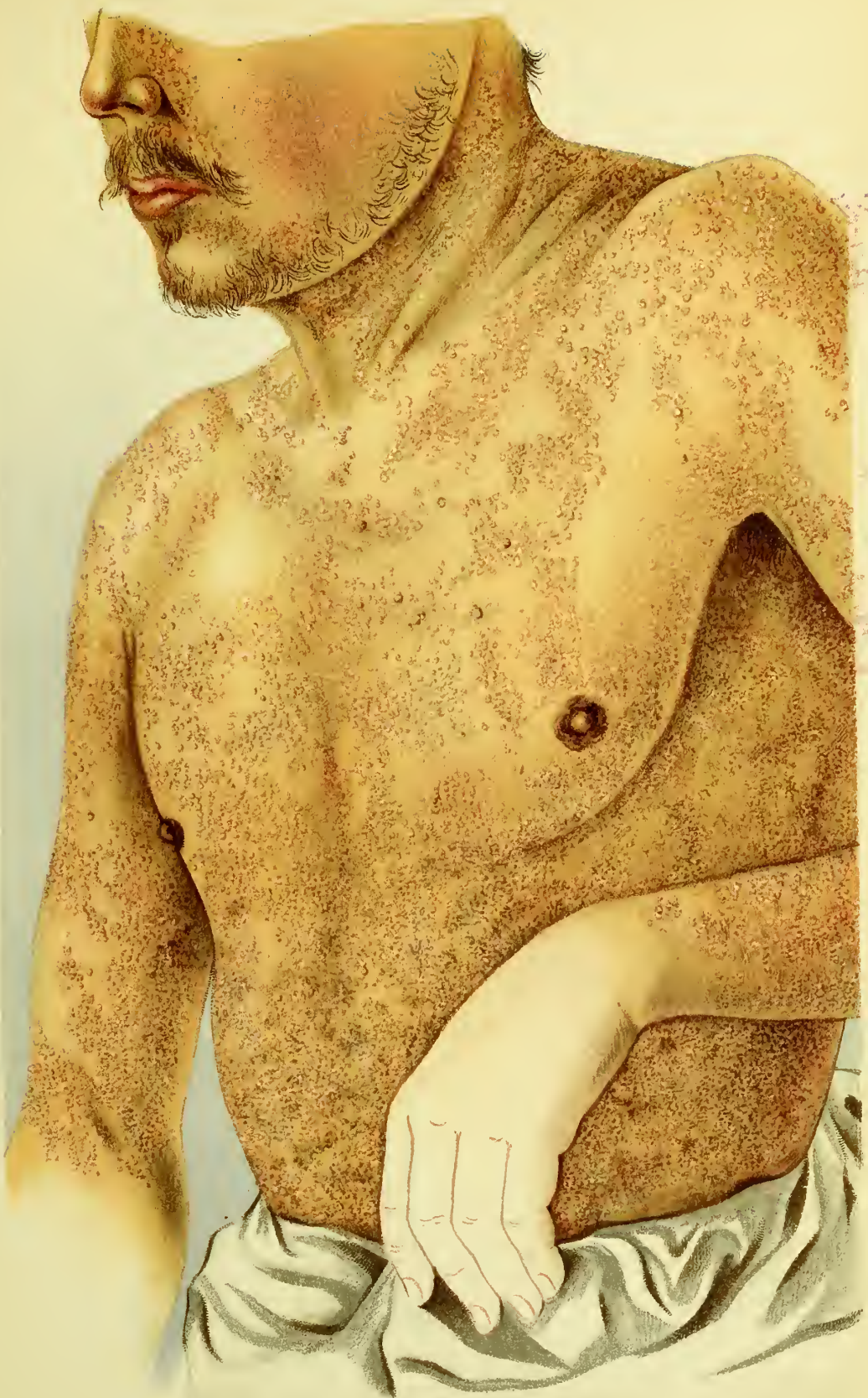





TAFEL 178.  
Lichen scrophulosorum.





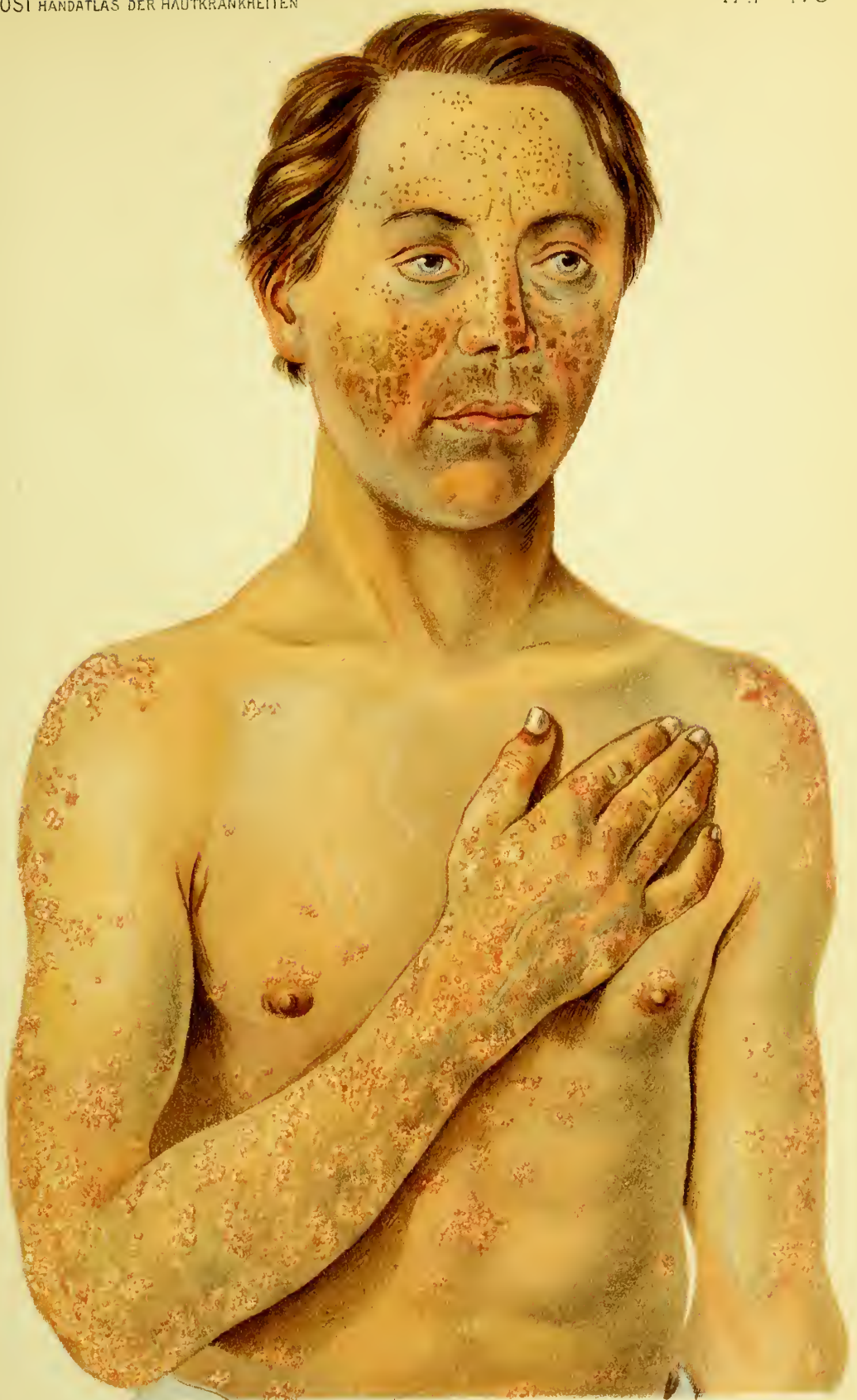

TAFEL 179.

Lichen scrophulosorum et Chloasma cachecticorum.







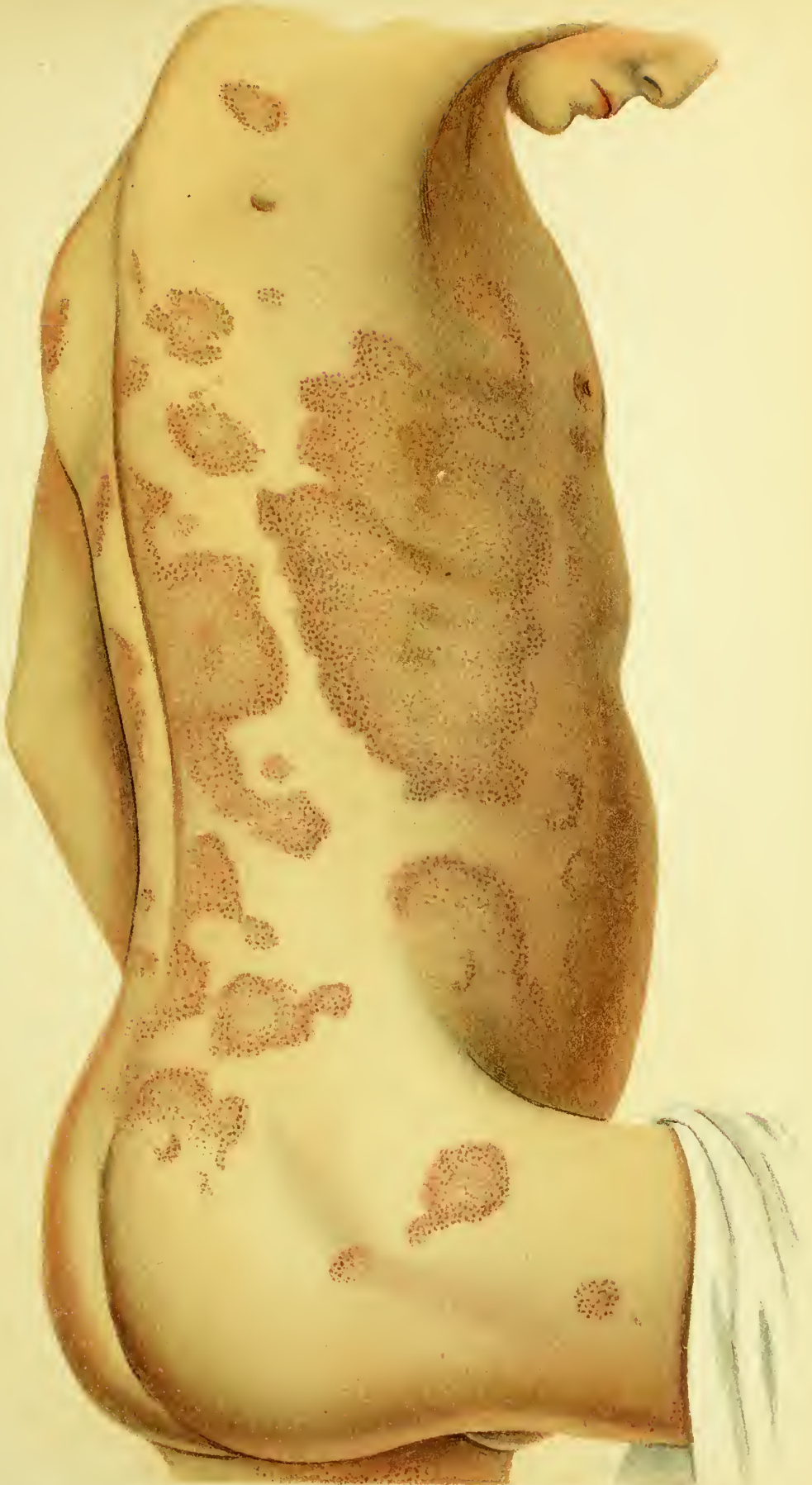



TAFEL 180.

Lichen scrophulosorum serpiginosus.





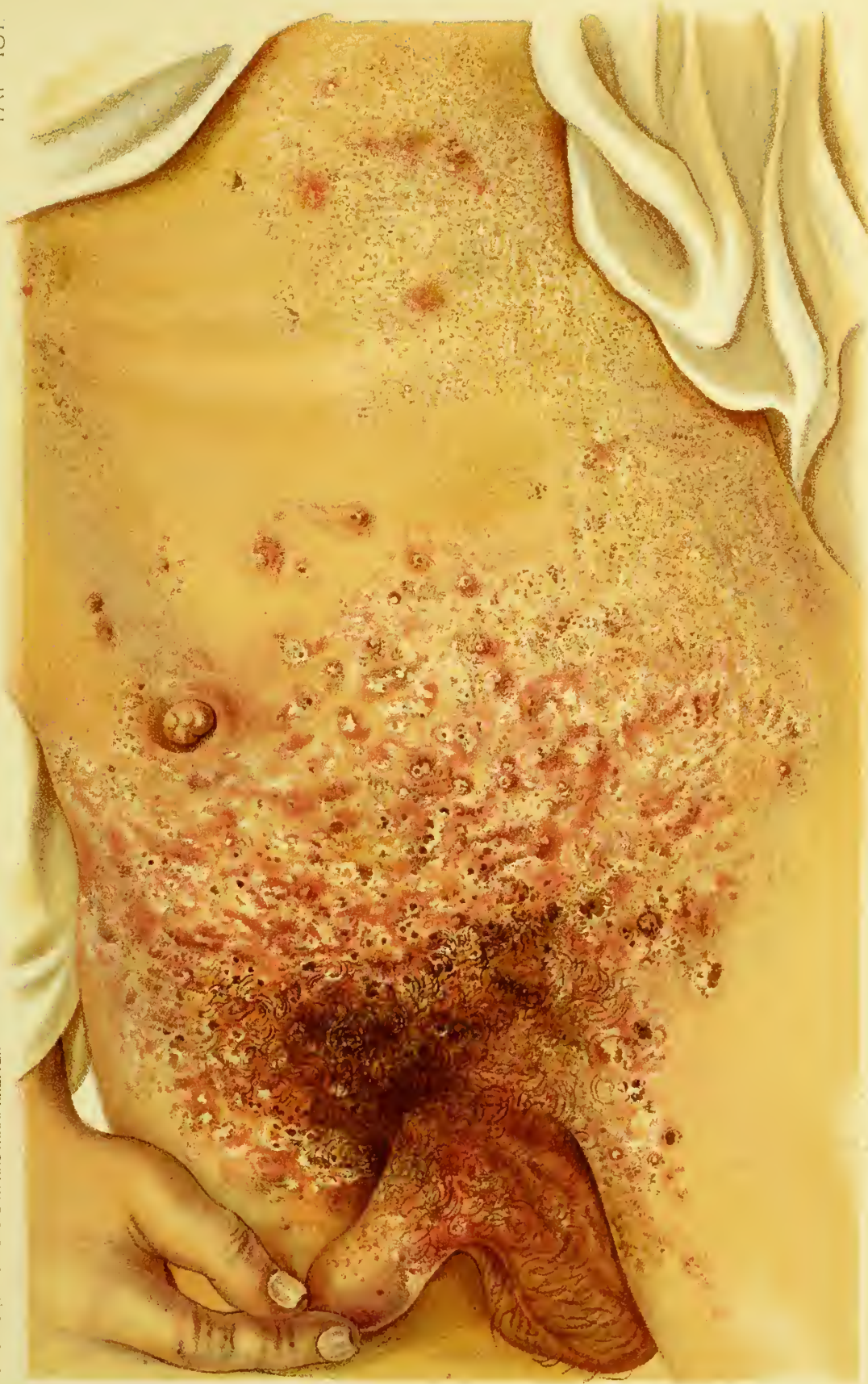

TAFEL 181.

Lichen scrophulosorum et Acne cachecticorum et Eczema  
c. Seborrhoea Genitalium.







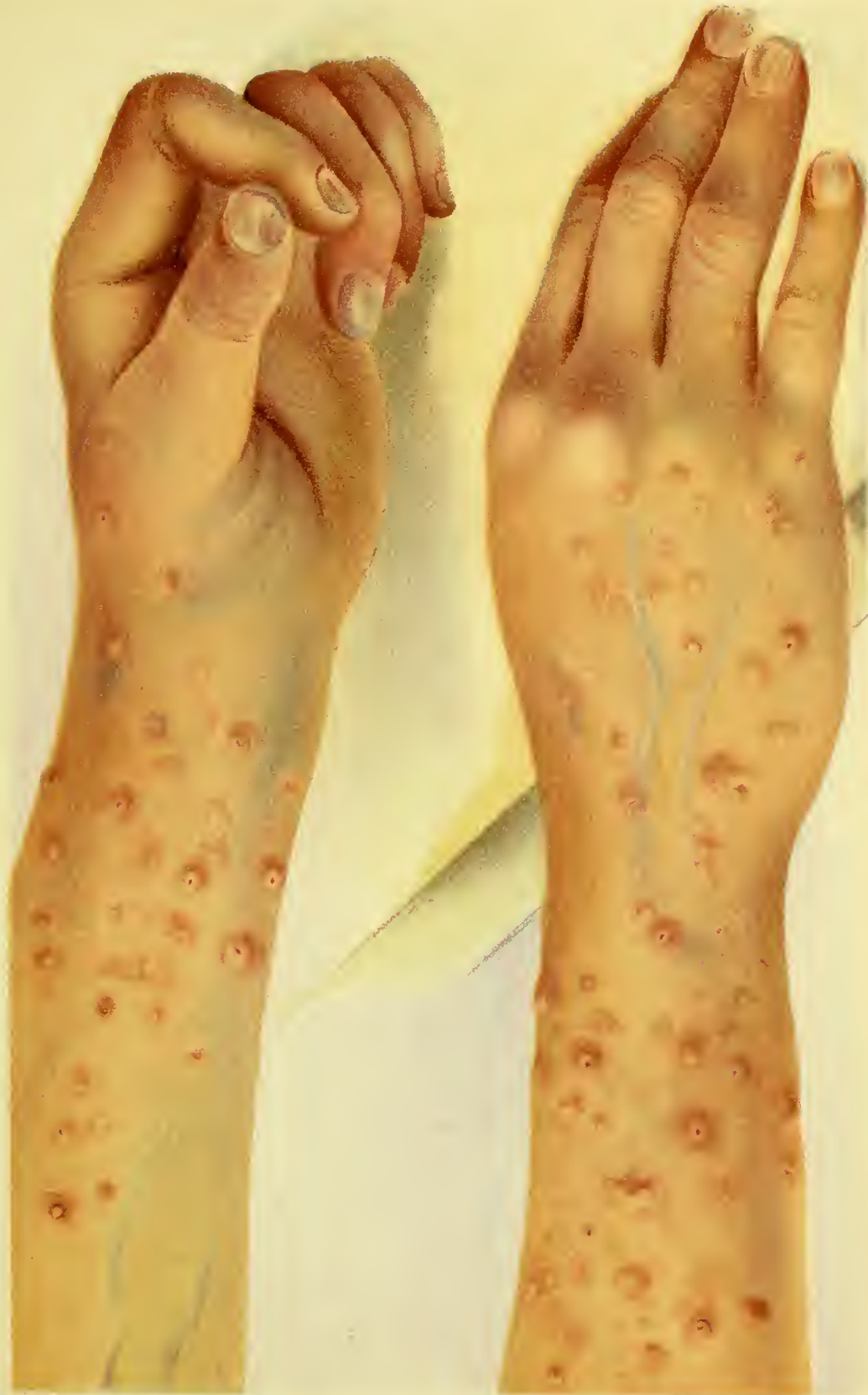



TAFEL 182.

Lichen urticatus (faciei et antibrachii utriusque).



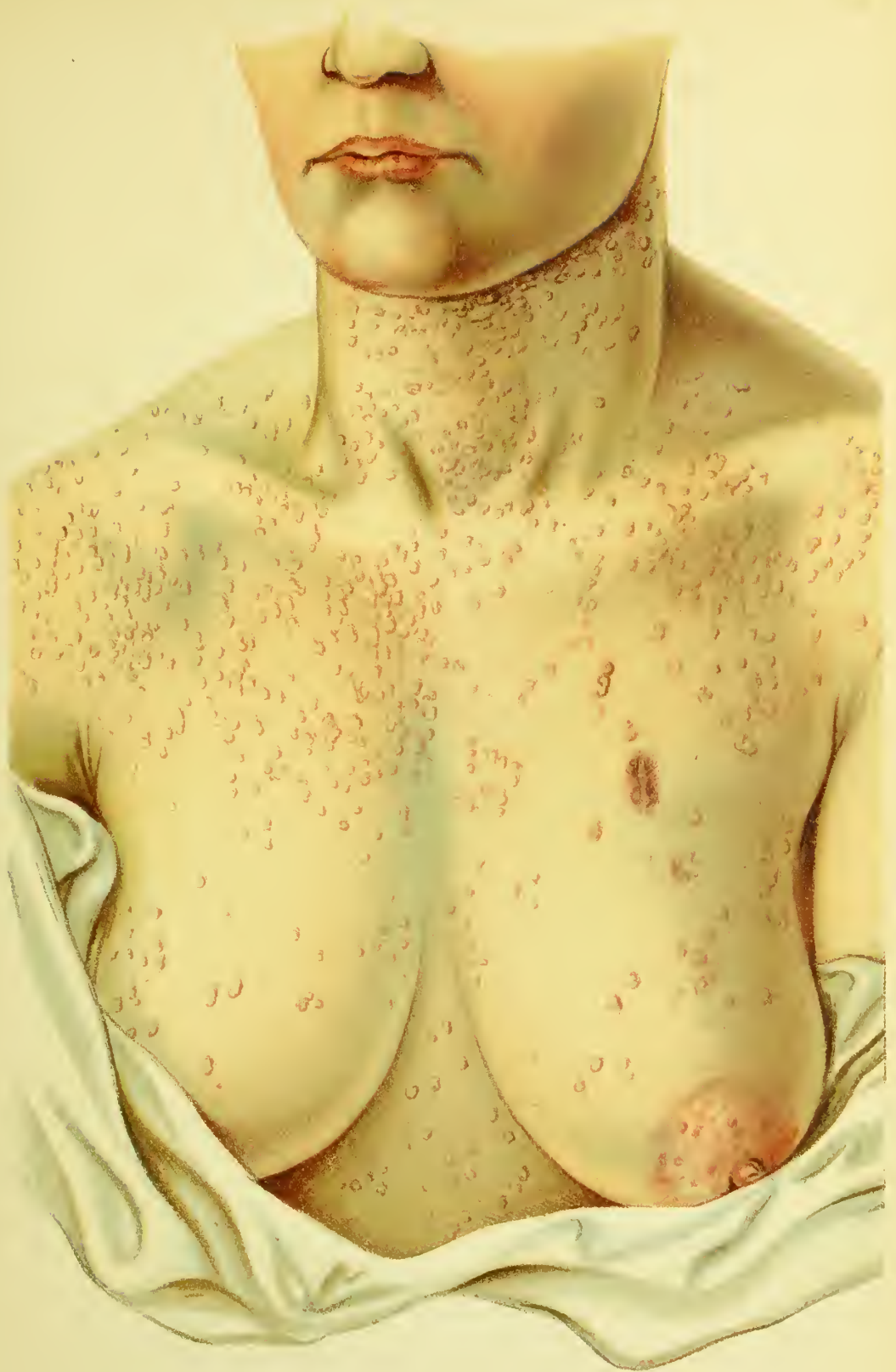



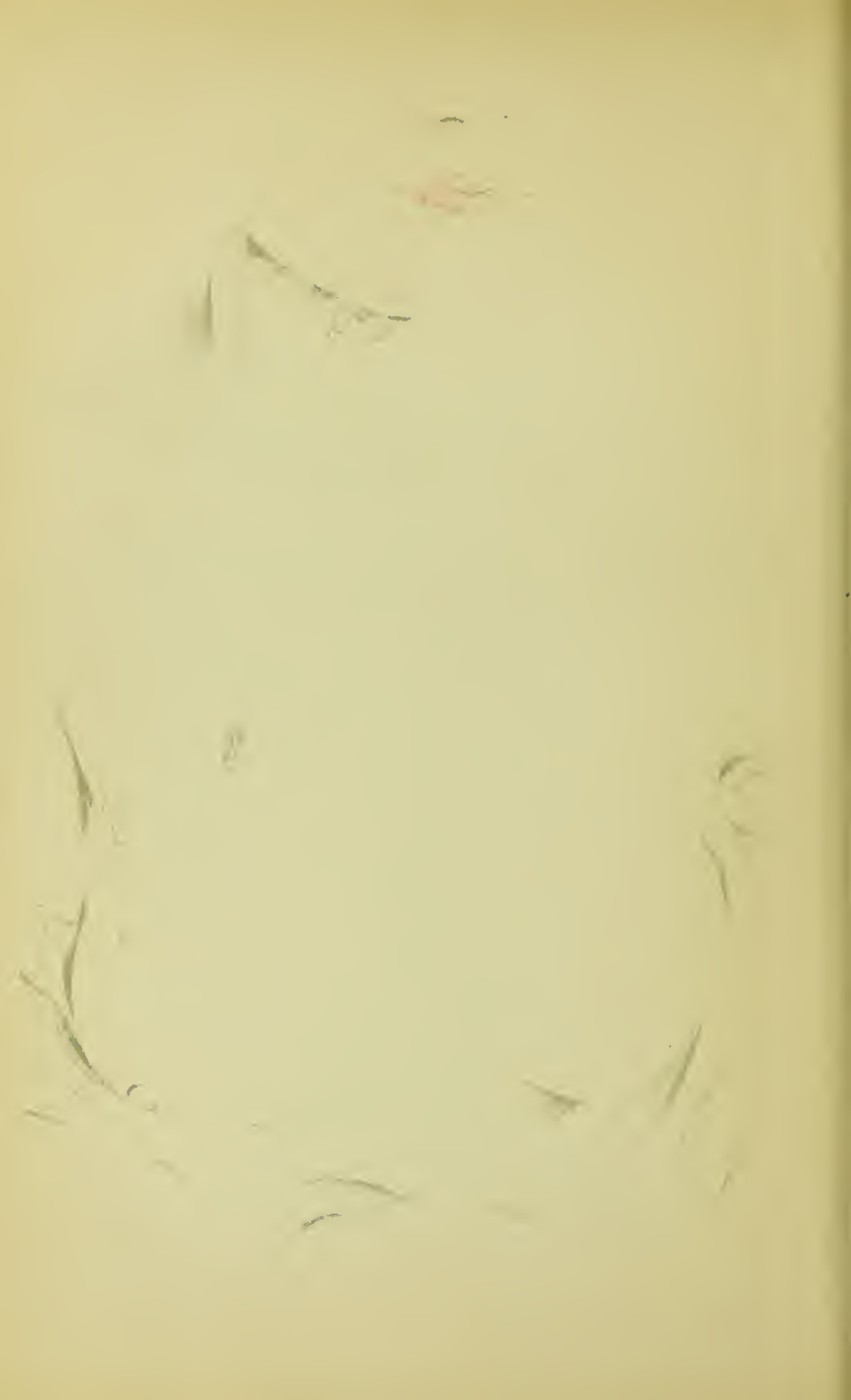
TAFEL 183.

Lymphangioma tuberosum multiplex adnata — mihi.





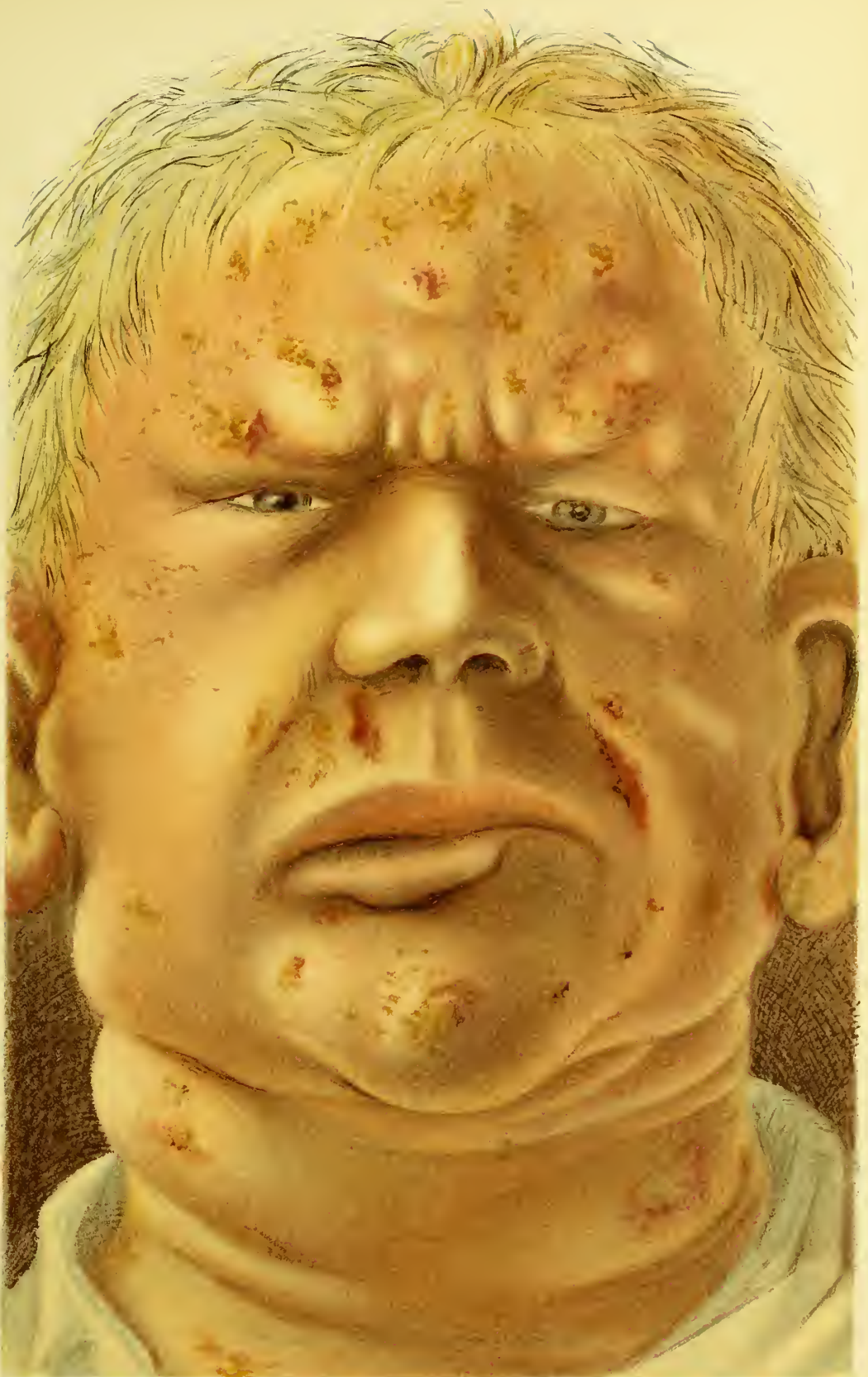



TAFEL 184.

*Lymphodermia perniciosa* — mihi.







TAFEL 185.

Lymphodermia perniciosa — mihi — incipiens; forse Stadium  
prodromale morbi Mycosis fungoides dicti.





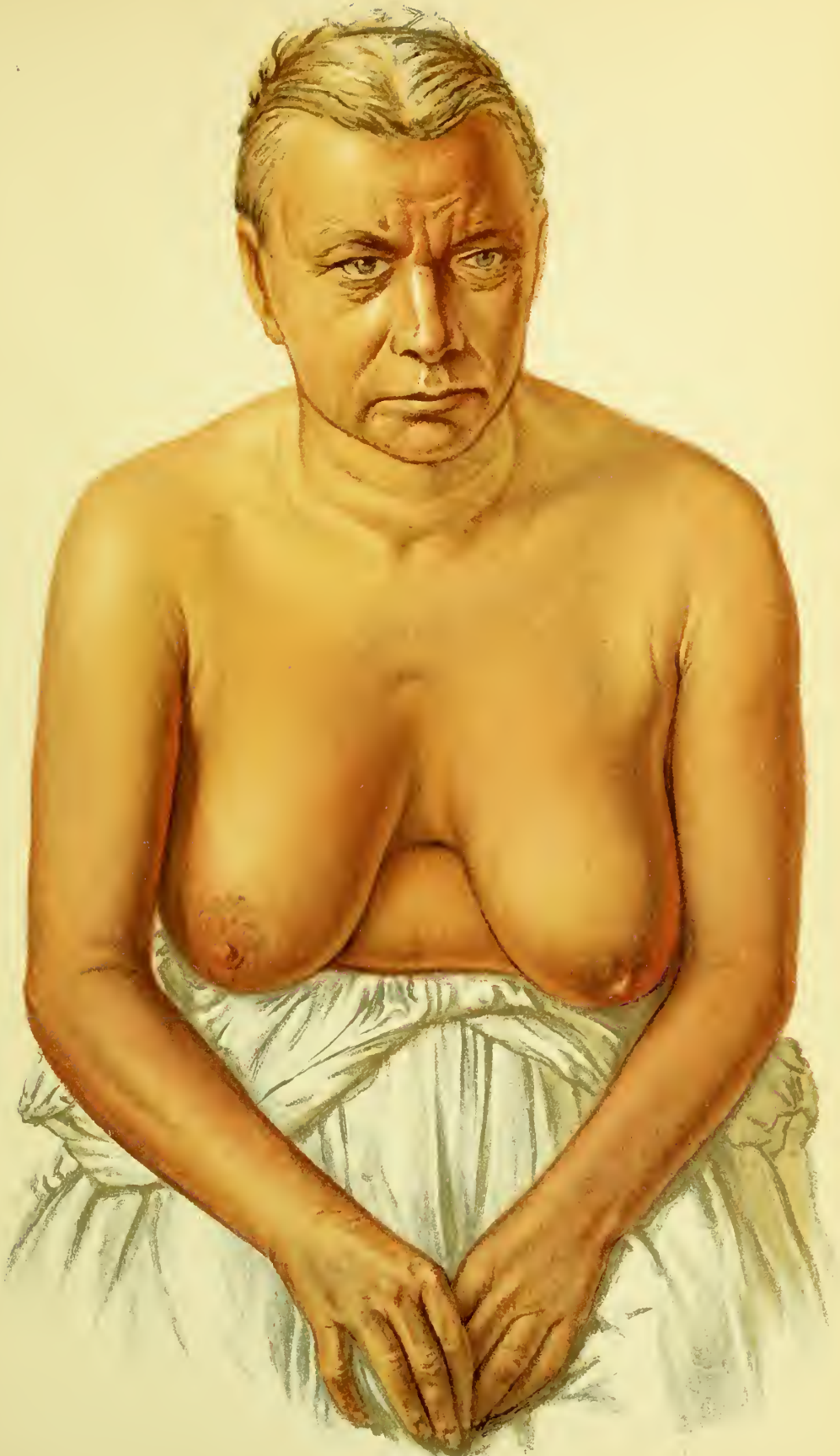



TAFEL 186.

Lymphodermia perniciosa — mihi — incipiens — forse  
Mycosis fungoides incipiens.



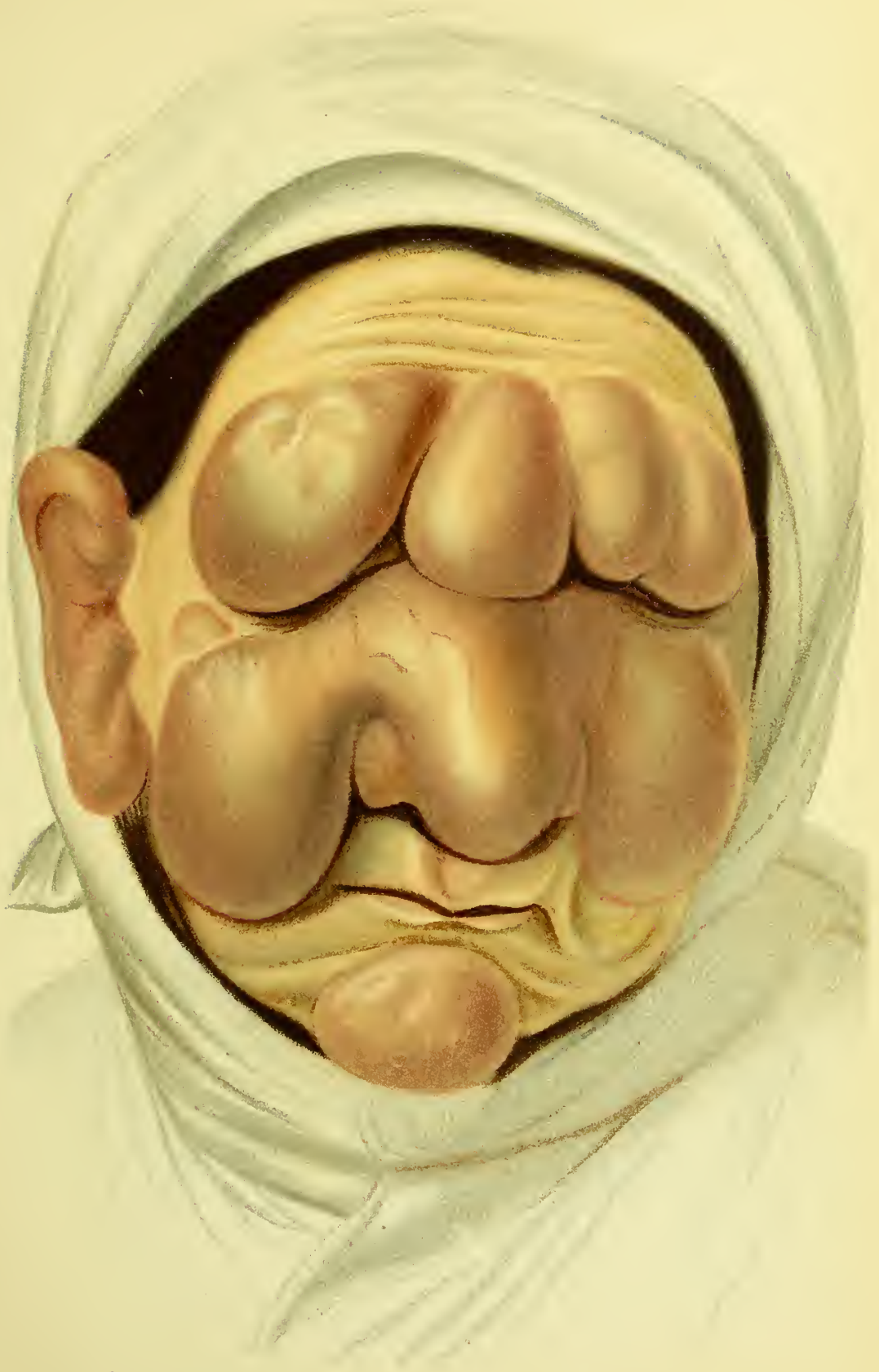



TAFEL 187.

Leucaemia cutis = Tumores leucaemici.









TAFEL 188.

**Lupus erythematosus discoides.**





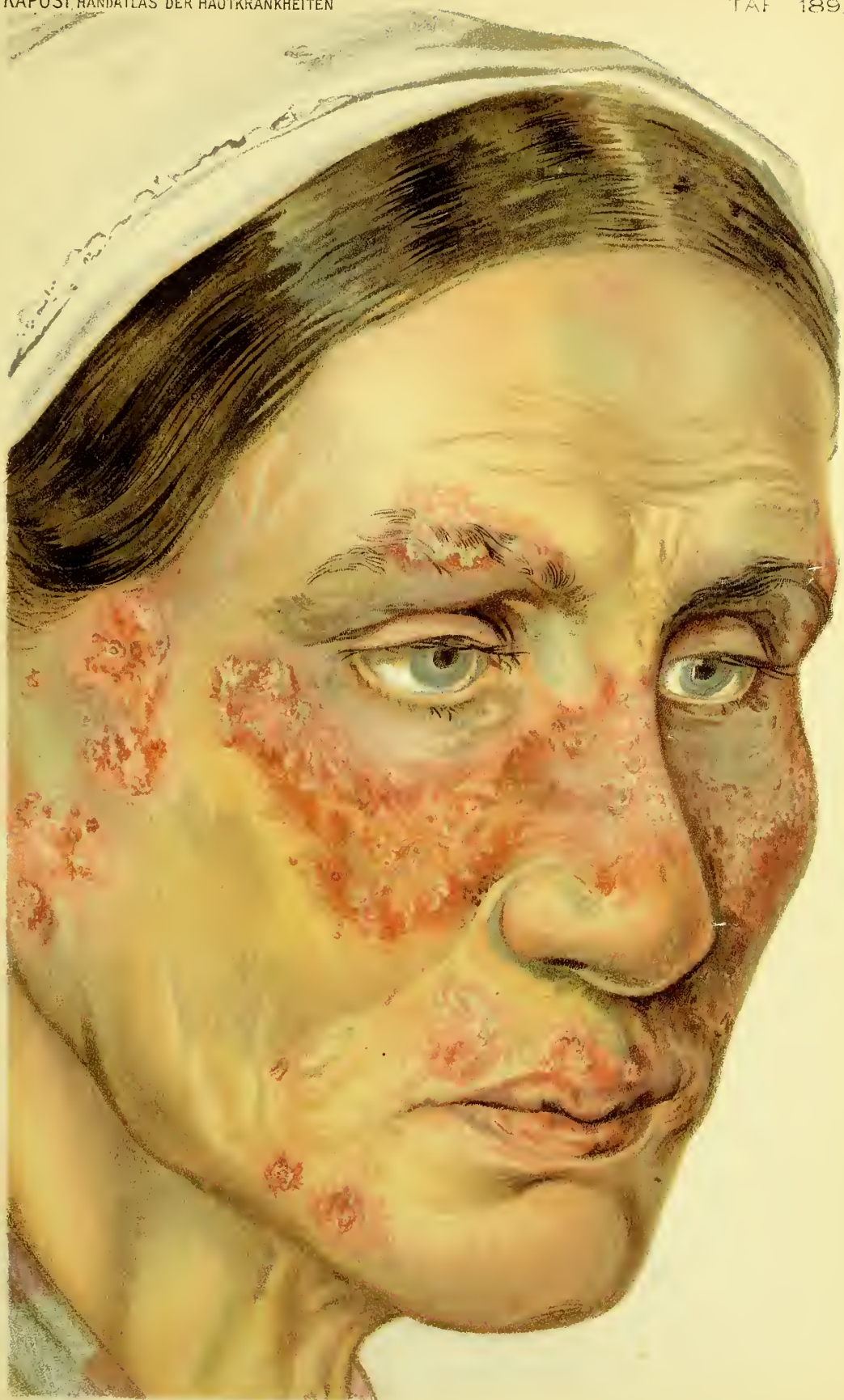

TAFEL 189.

Lupus erythematosus discoides et disseminatus.







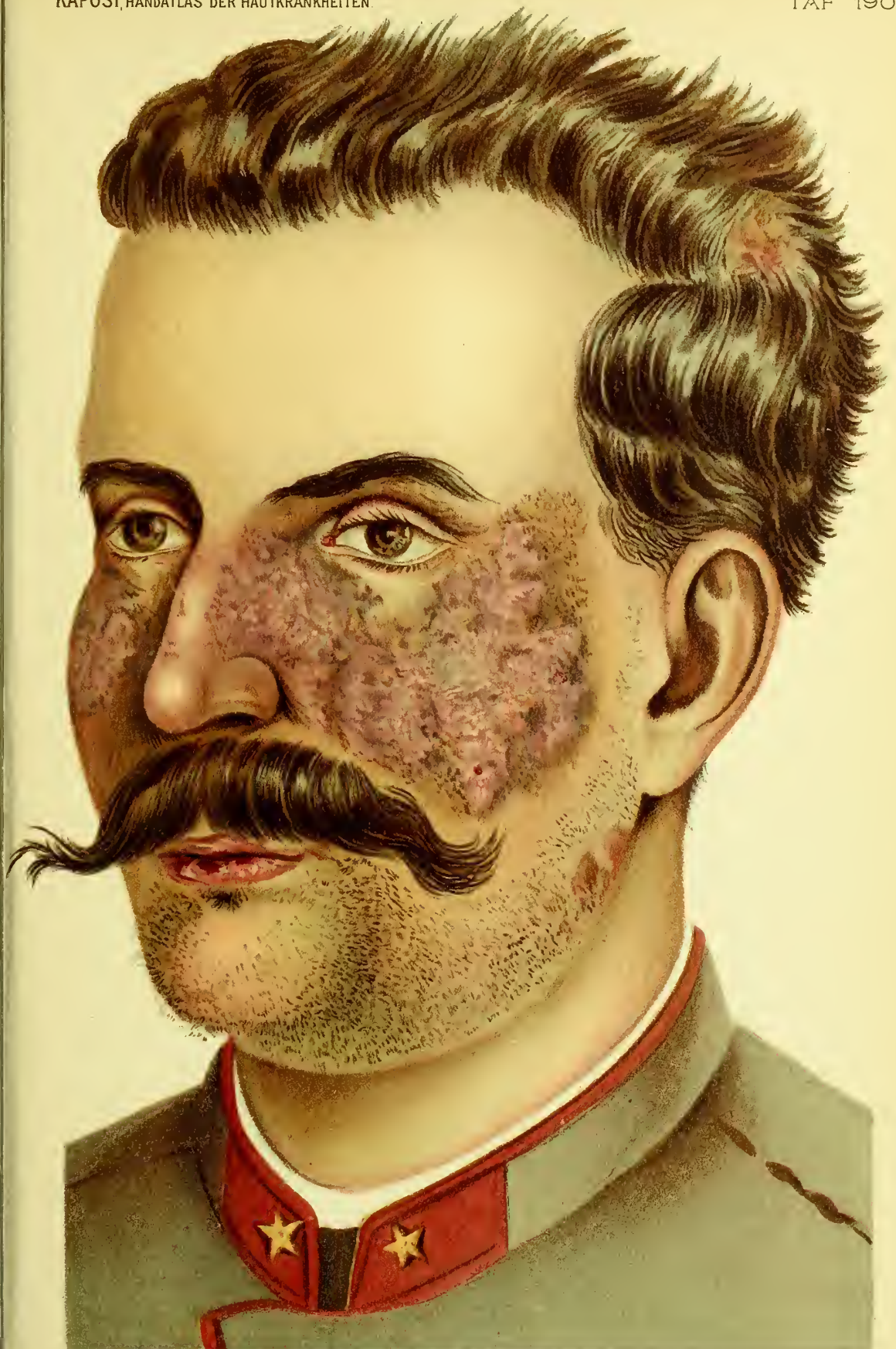




TAFEL 190.

**Lupus erythematosus discoides.**





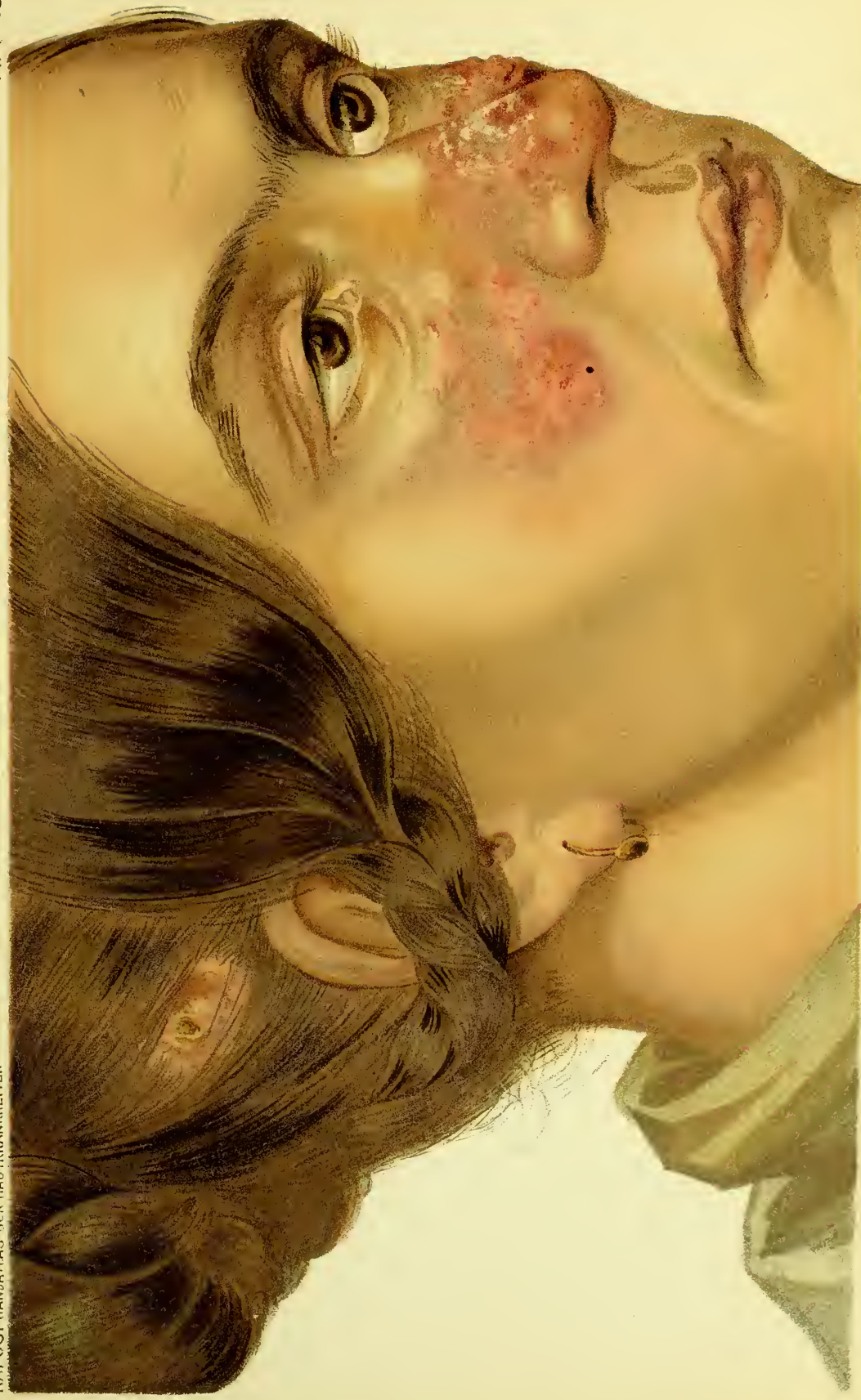

TAFEL 191.

Lupus erythematosus discoides faciei et capillitii.







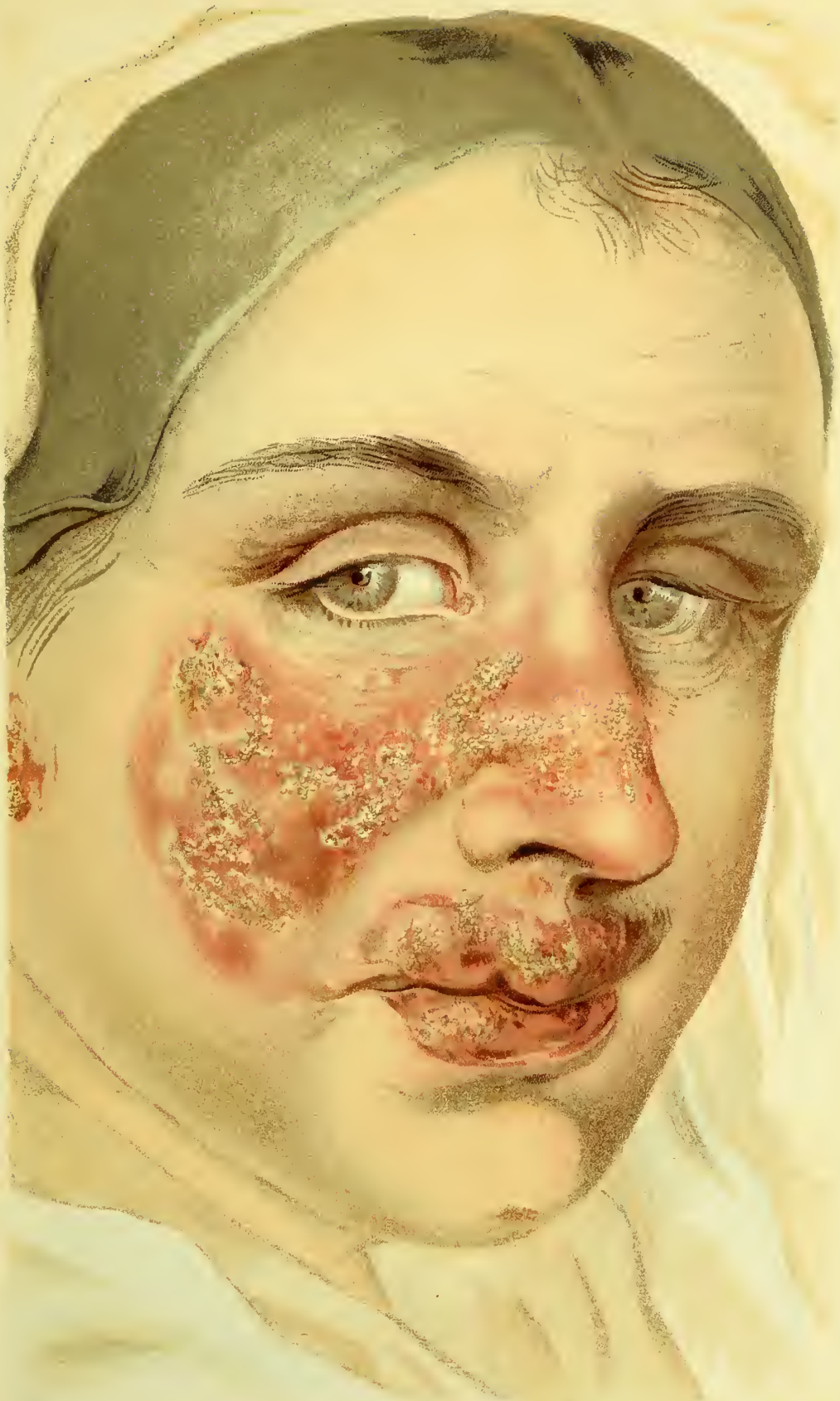



TAFEL 192.

Lupus erythematosus discoides faciei et labiorum oris.





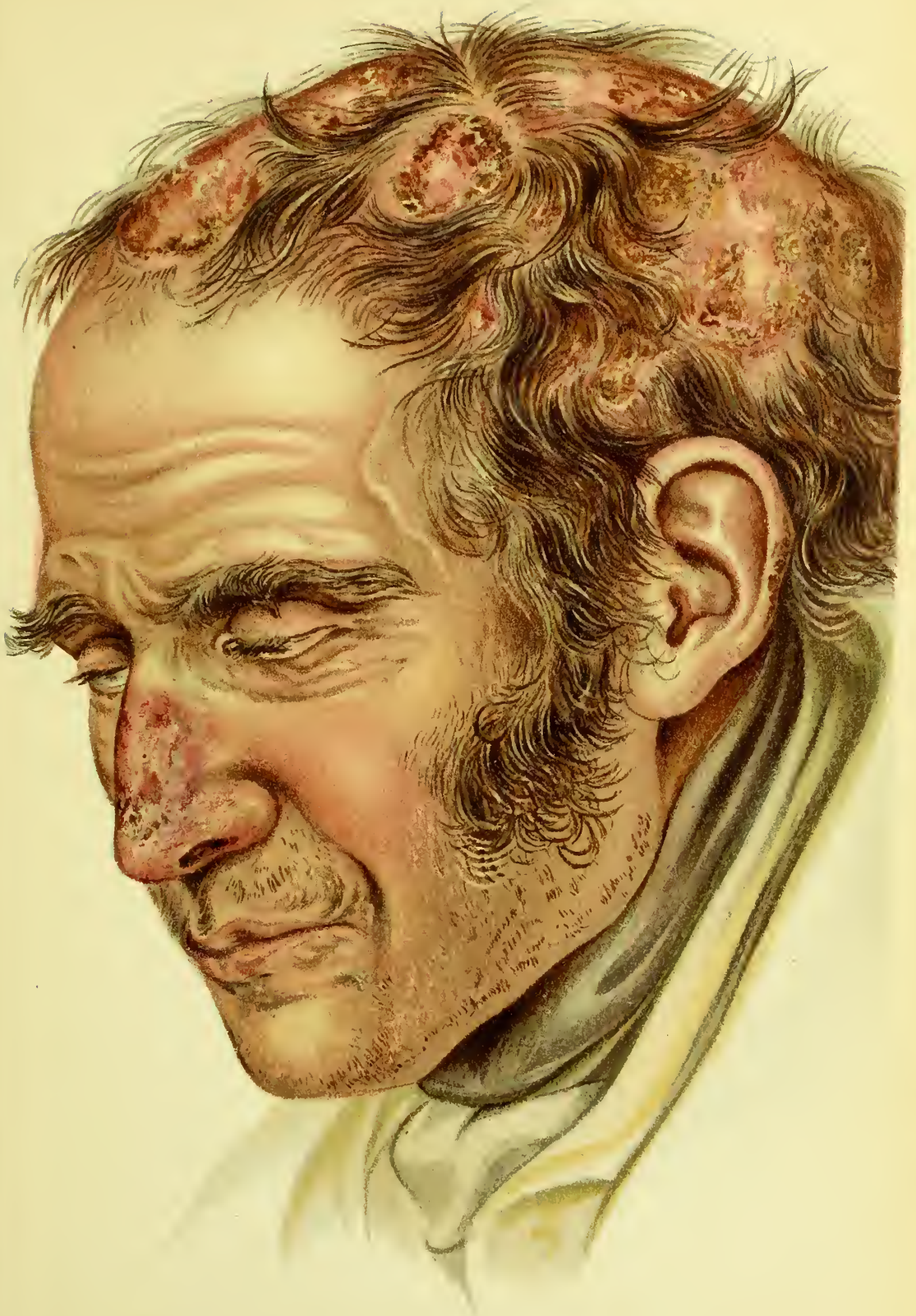

TAFEL 193.

Lupus erythematosus discoides Capillitii.







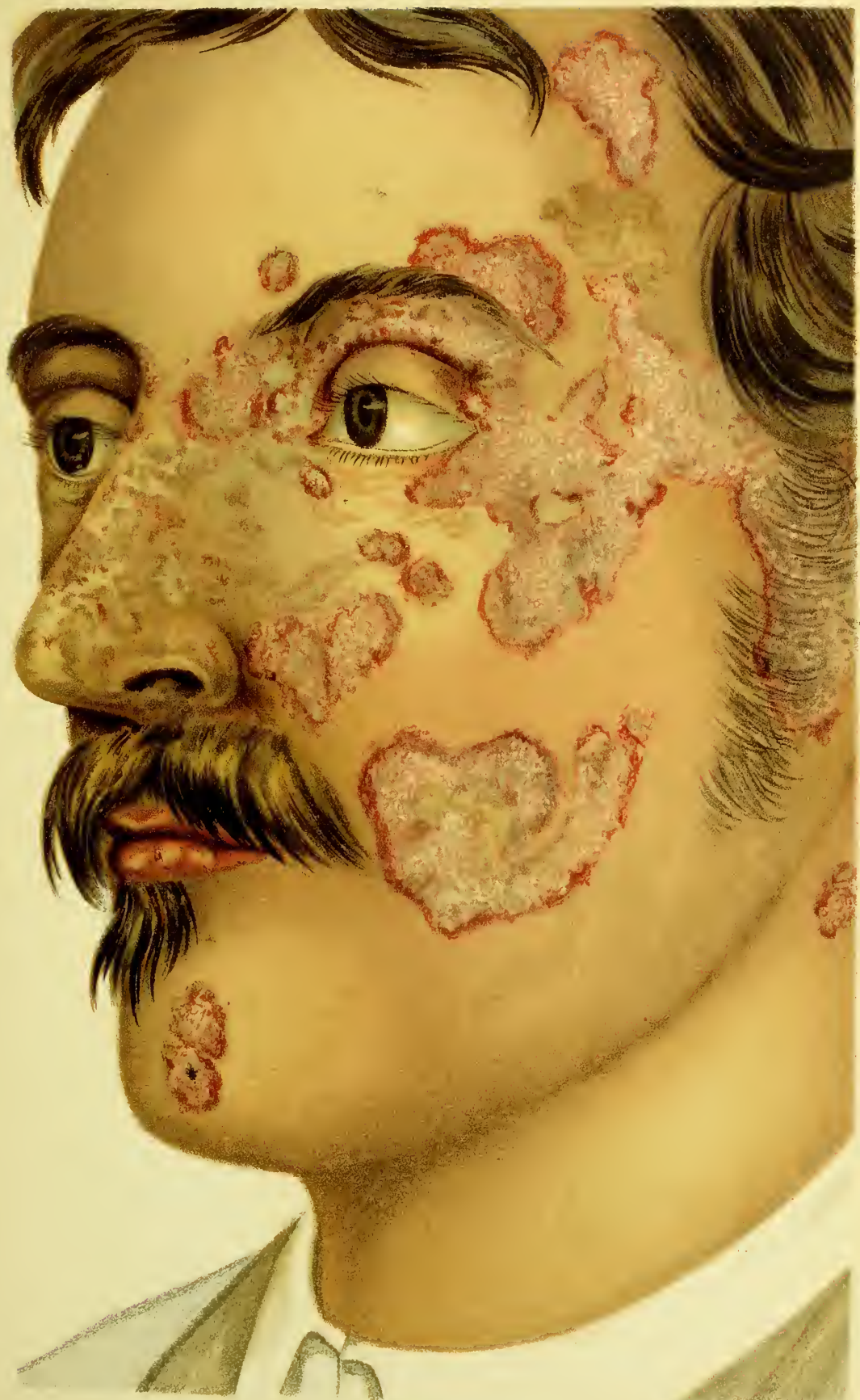



TAFEL 194.

Lupus erythematoses discoides faciei.







TAFEL 195.

**Lupus erythematosus disseminatus.**







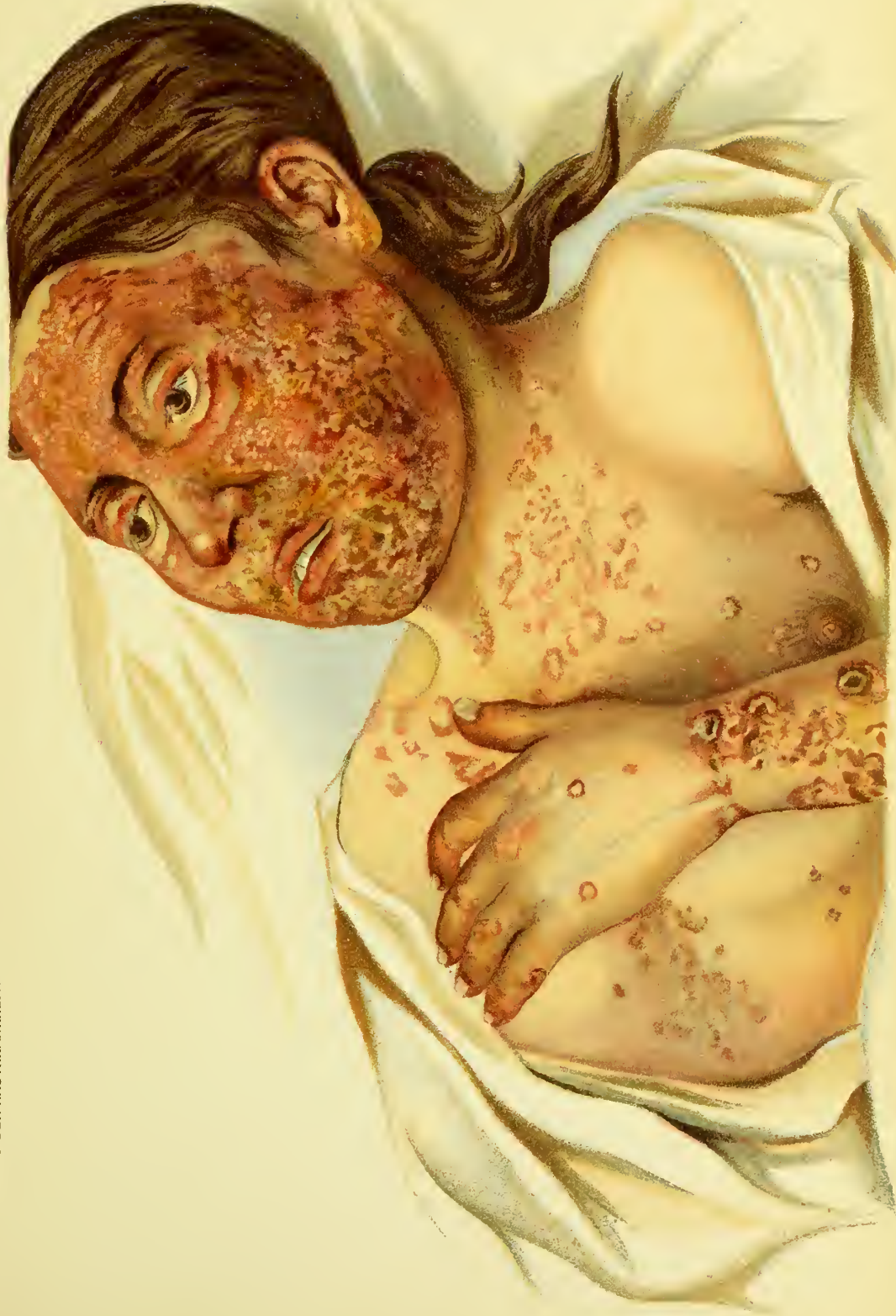



TAFEL 196.

Lupus erythematosus disseminatus acutus, bullosus,  
febrilis. Erysipelas perstans faciei — mihi.



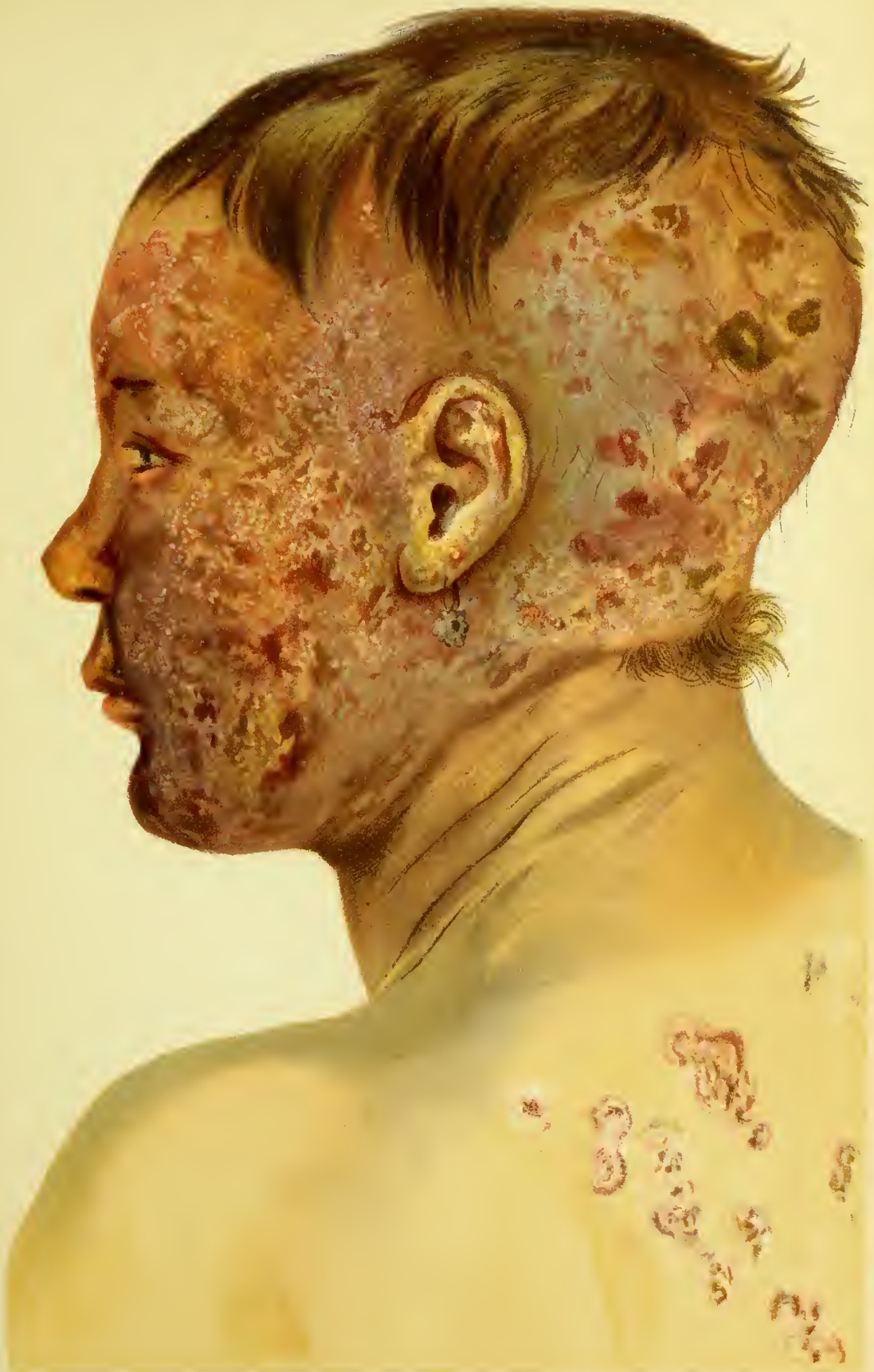



TAFEL 197.

Lupus erythematosus disseminatus et aggregatus faciei  
et trunci.





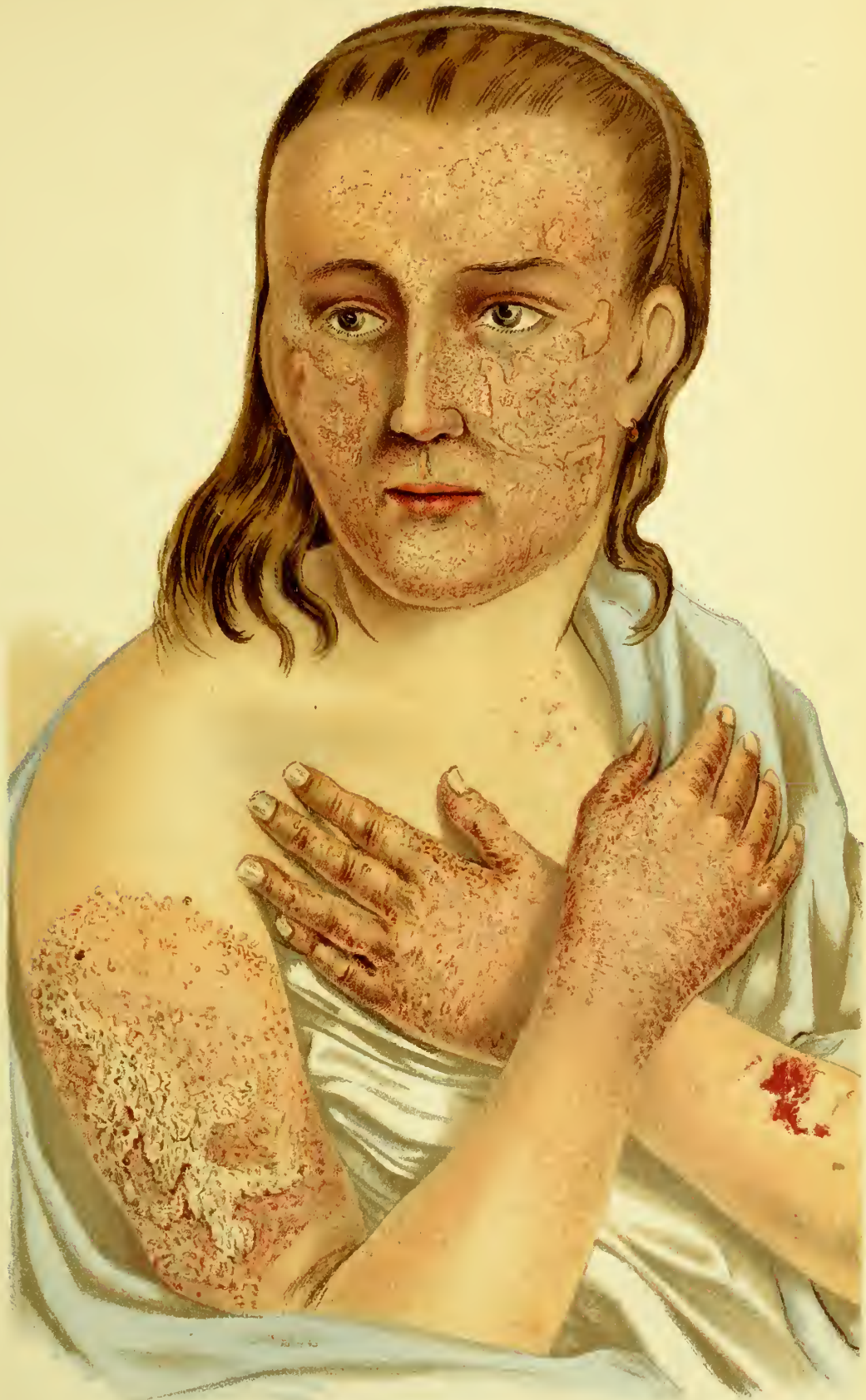



TAFEL 198.

Lupus erythematosus disseminatus Capillitii, faciei, trunci,  
extremitatum.



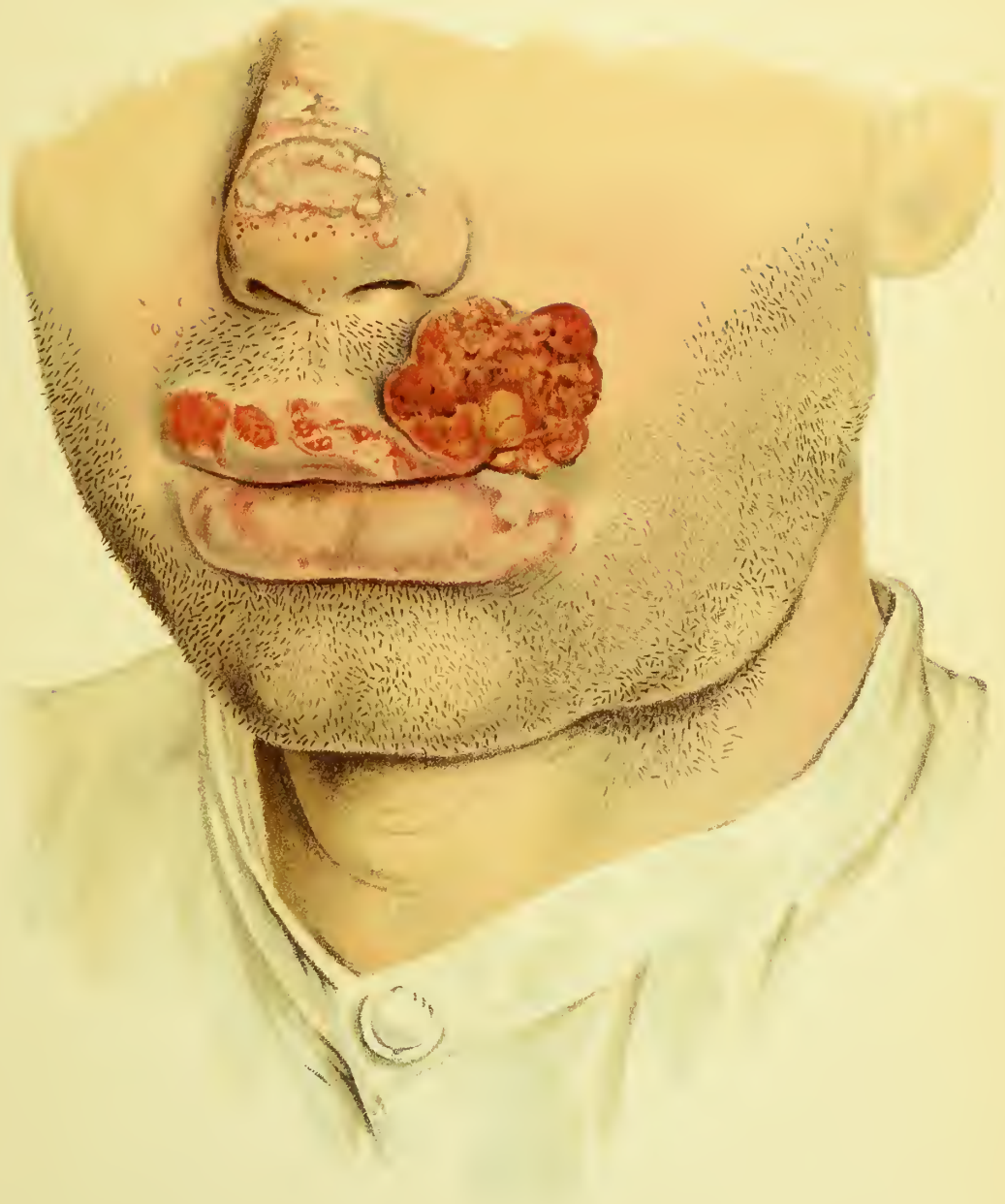




TAFEL 199.

Lupus erythematosus consequente Carcinomate epitheliali.





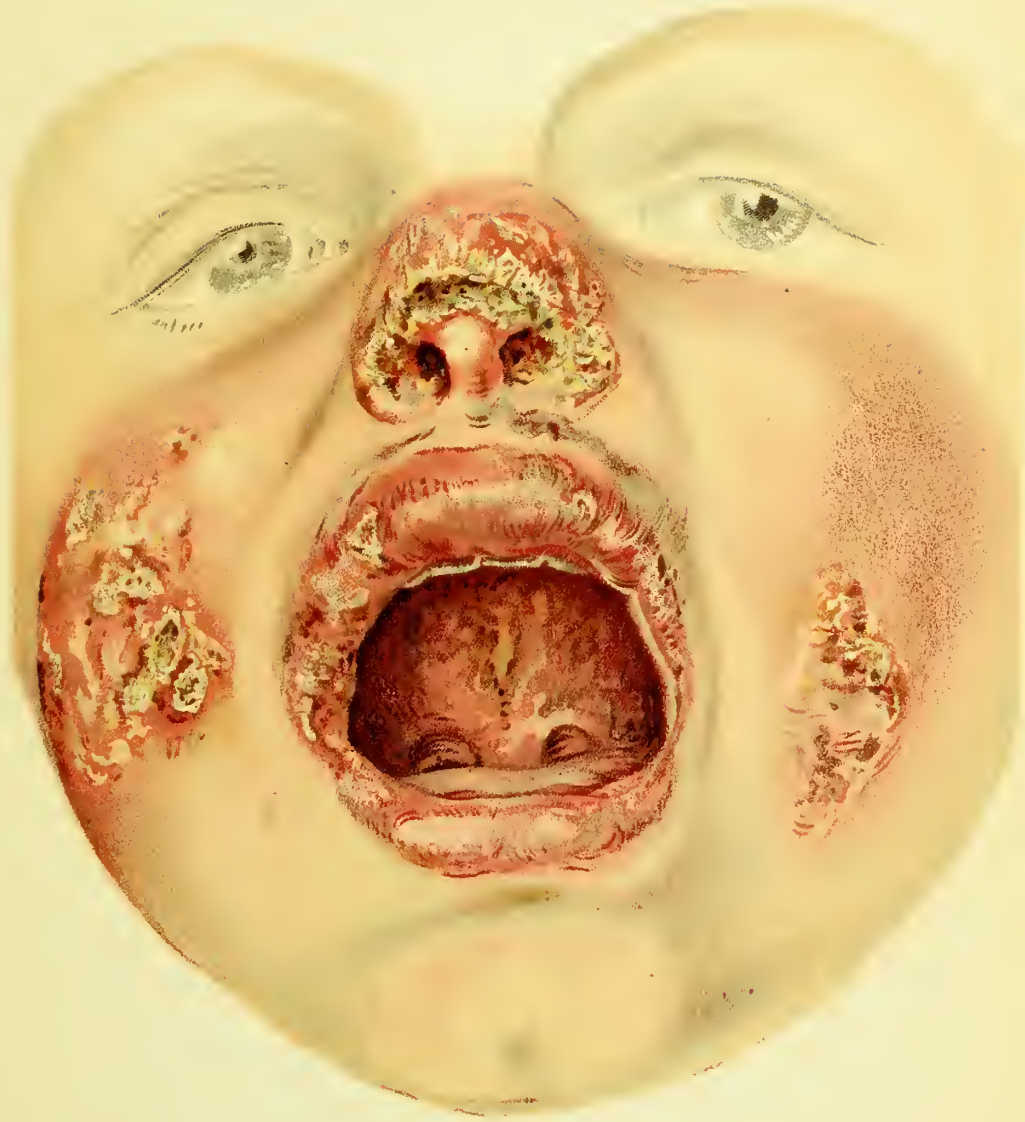



TAFEL 200.

Lupus vulgaris faciei, labii oris et palati duri.







TAFEL 201.  
Lupus vulgaris faciei.





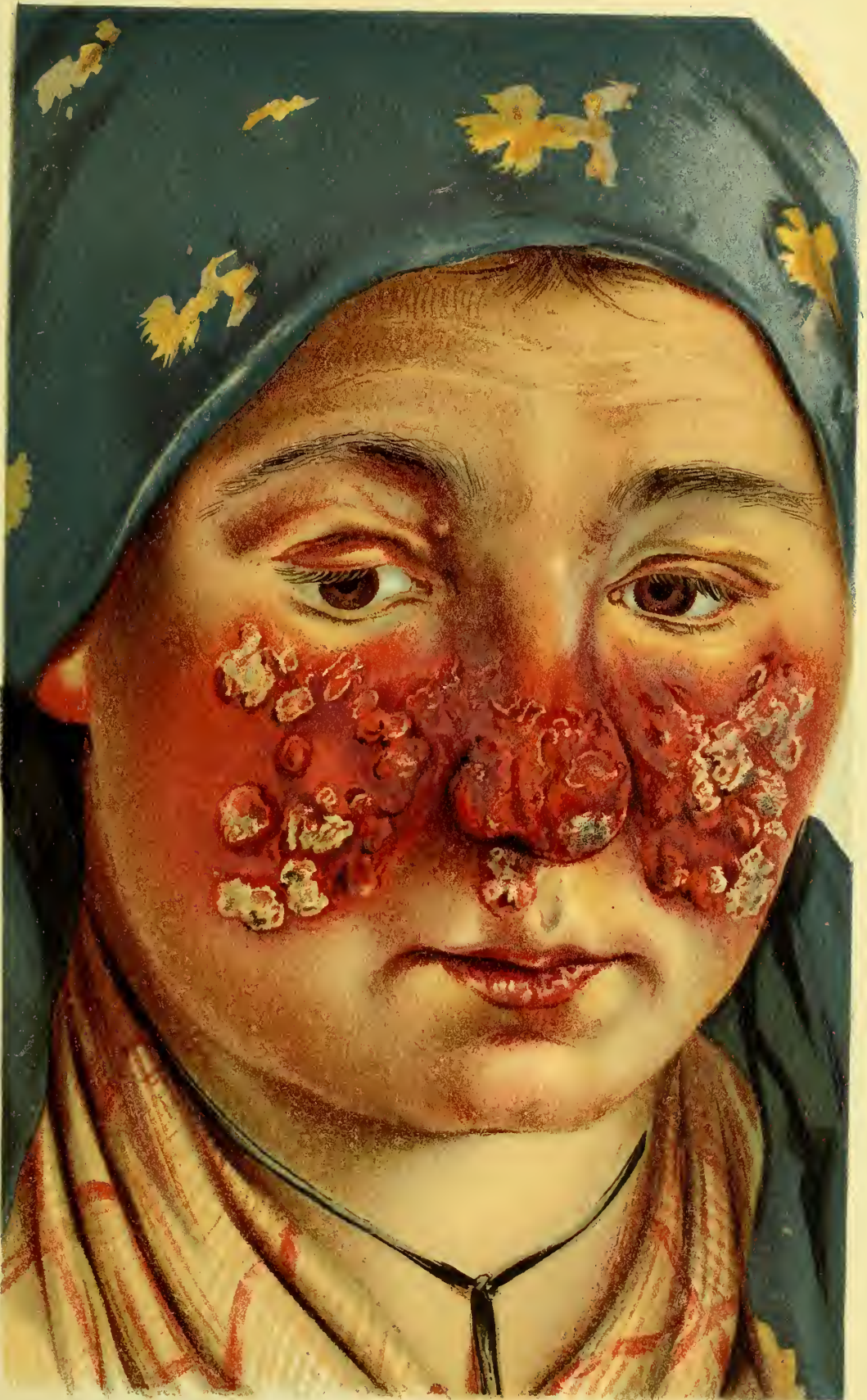



TAFEL 202.

Lupus vulgaris faciei tumidus.





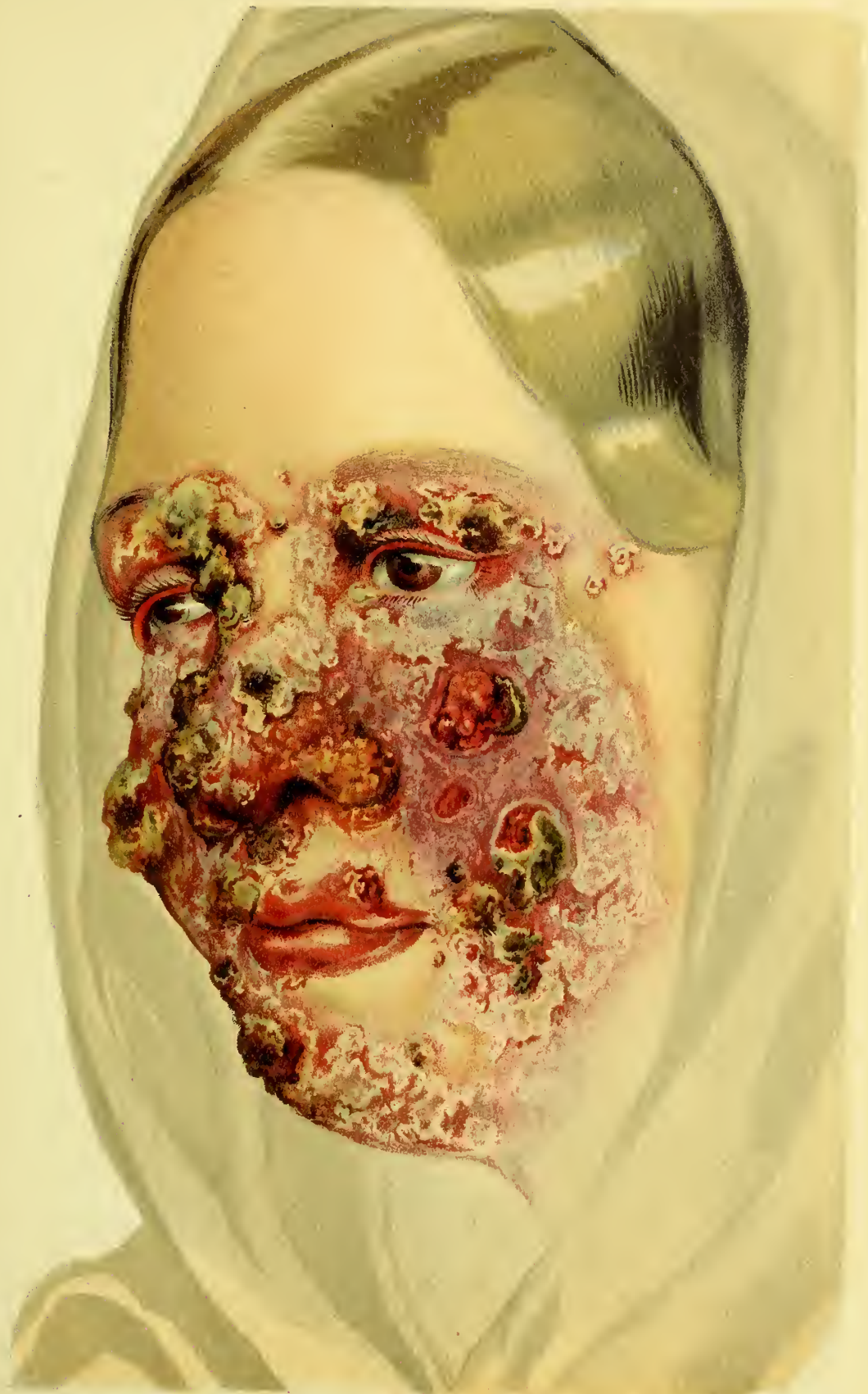

TAFEL 203.

Lupus vulgaris faciei exulcerans et papillaris.







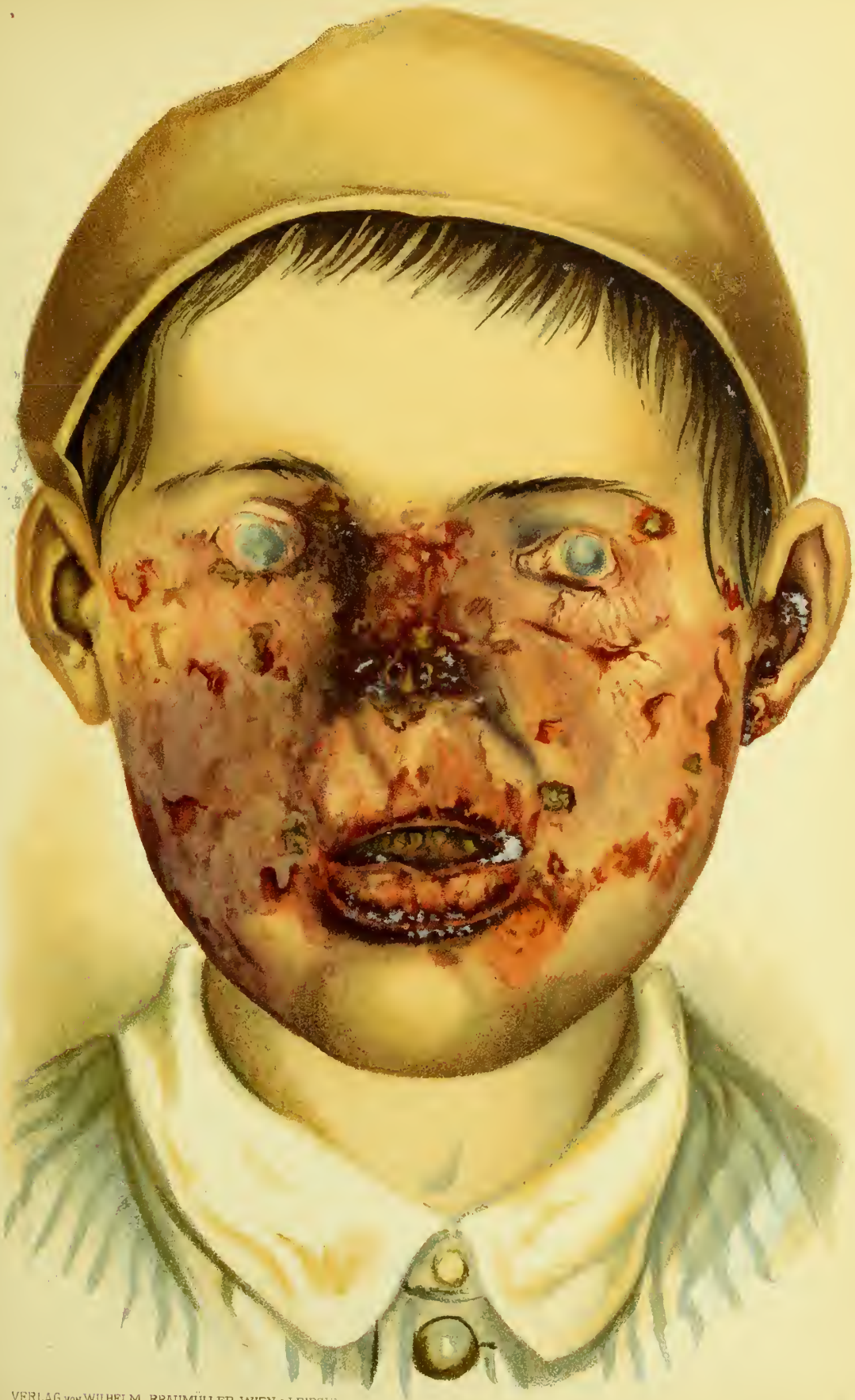



TAFEL 204.

Lupus vulgaris faciei — Consumptio nasi, utraque Cornea  
cicatricibus consumpta.





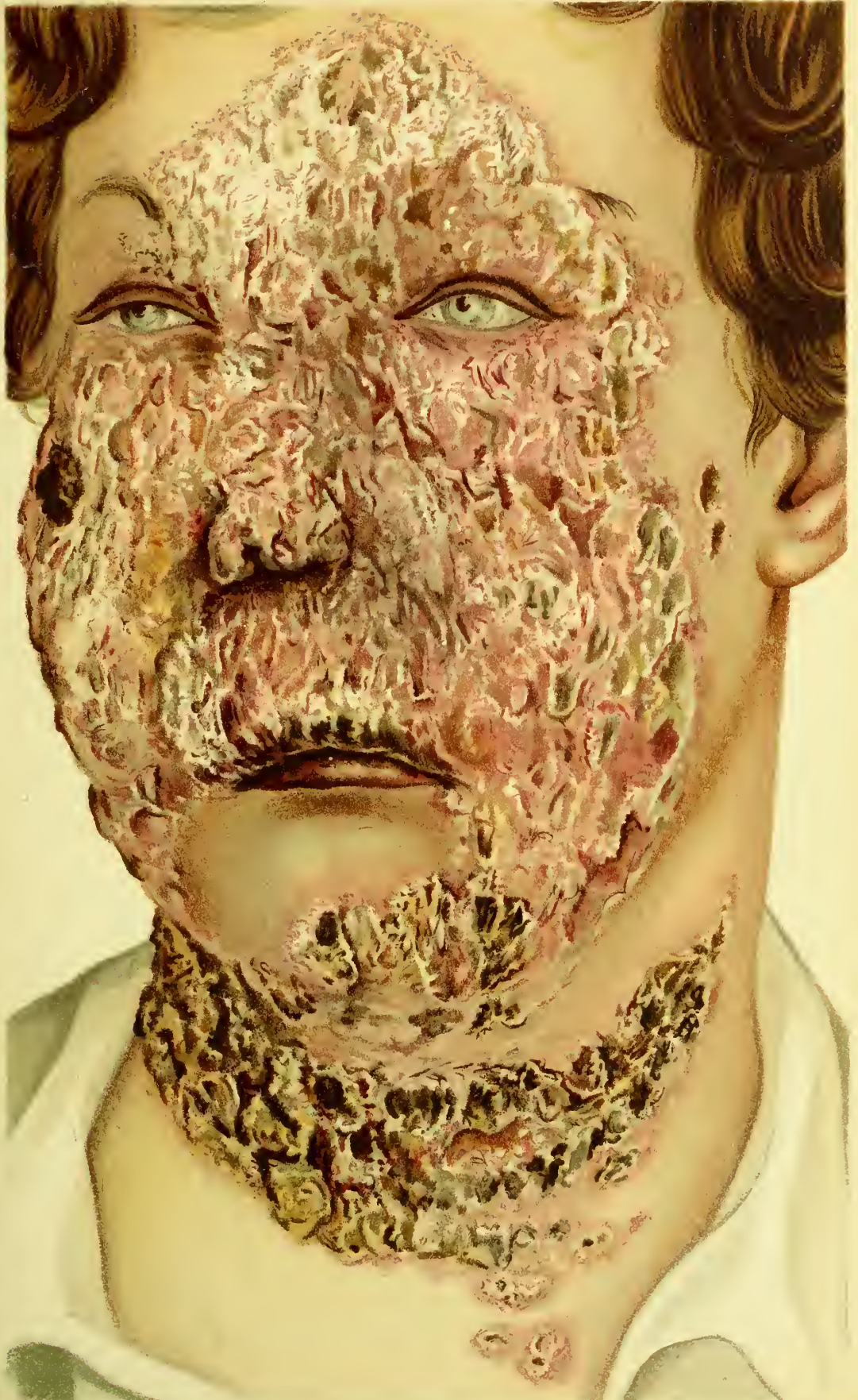

TAFEL 205.

Lupus vulgaris faciei totius et serpiginosus regionis  
cervicalis.







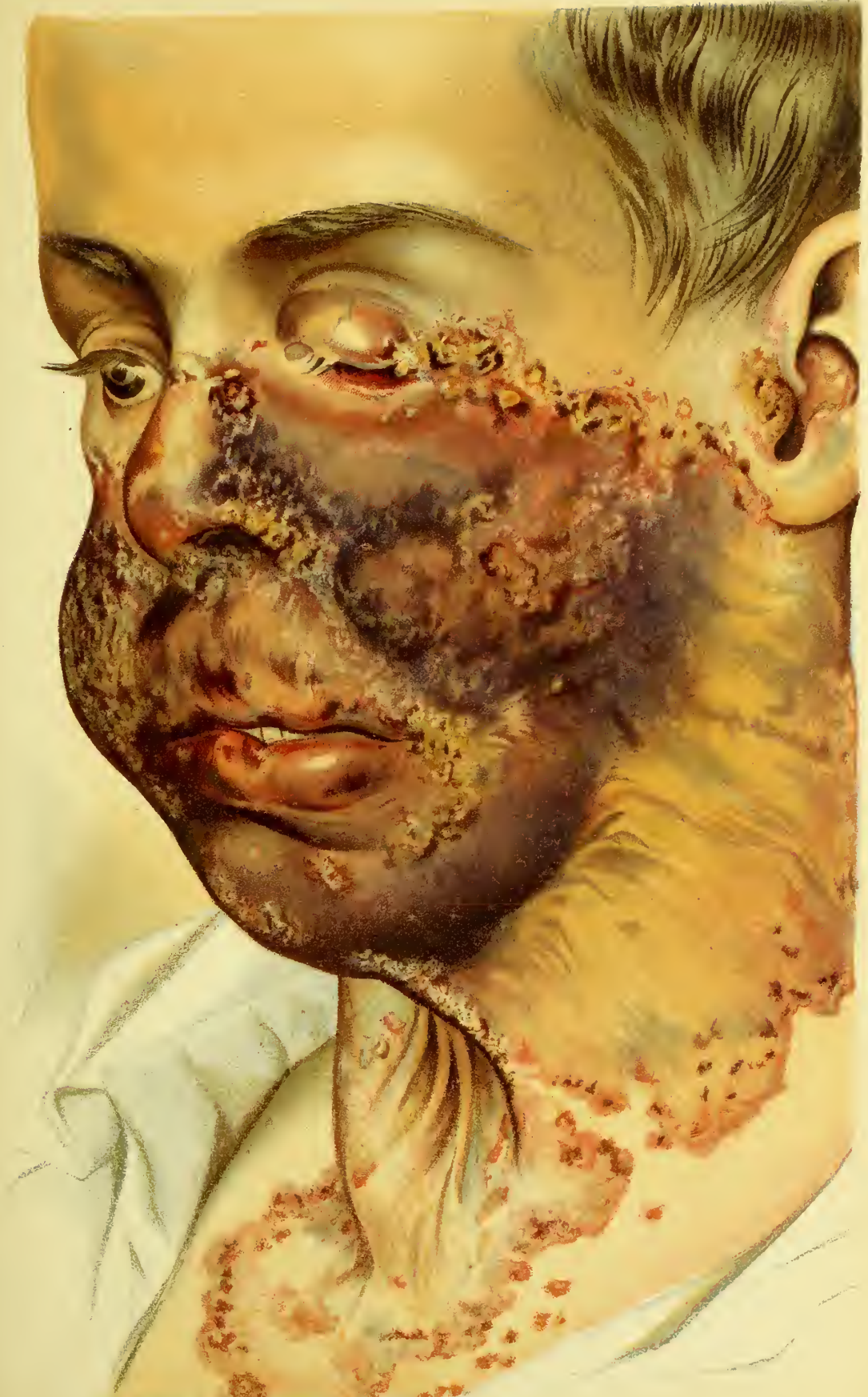



TAFEL 206.

Lupus vulgaris exulcerans faciei et serpiginosus regionis  
cervicalis et sternalis.



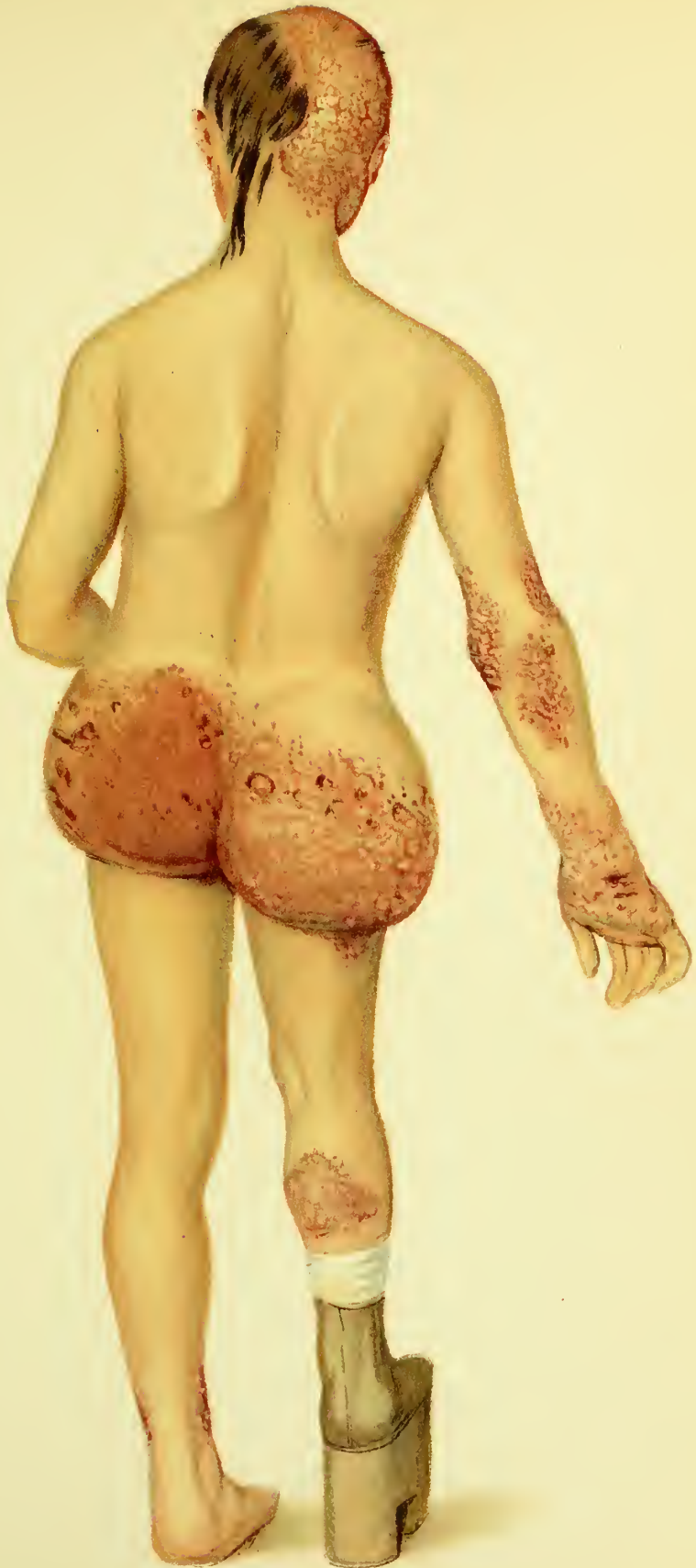



TAFEL 207.

Lupus vulgaris regionis occipitalis, extremitatum tumidus  
et deformans, ad nates c. Elephantiasi Arabum subjacente.





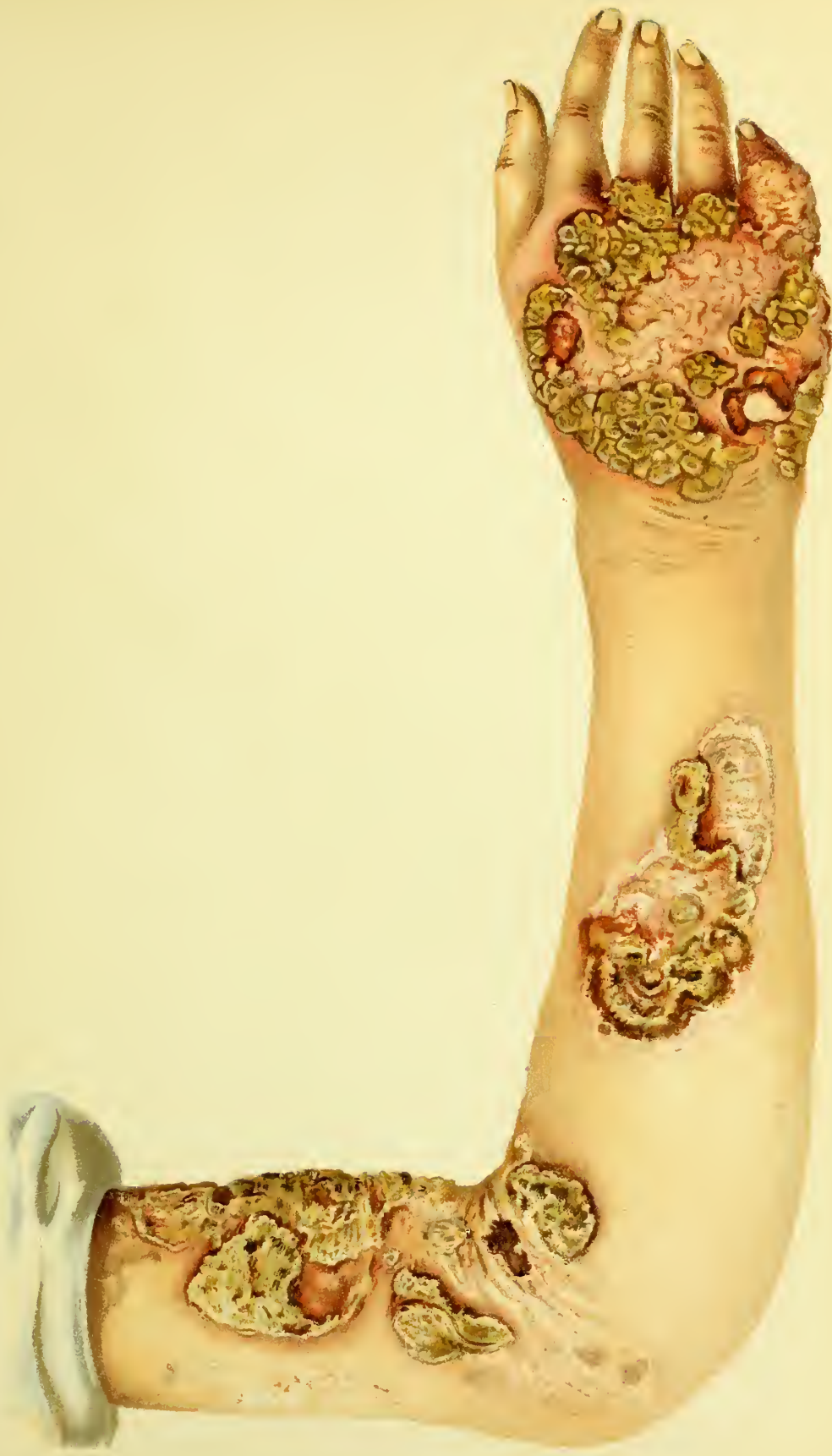



TAFEL 208.

**Lupus vulgaris brachii.**



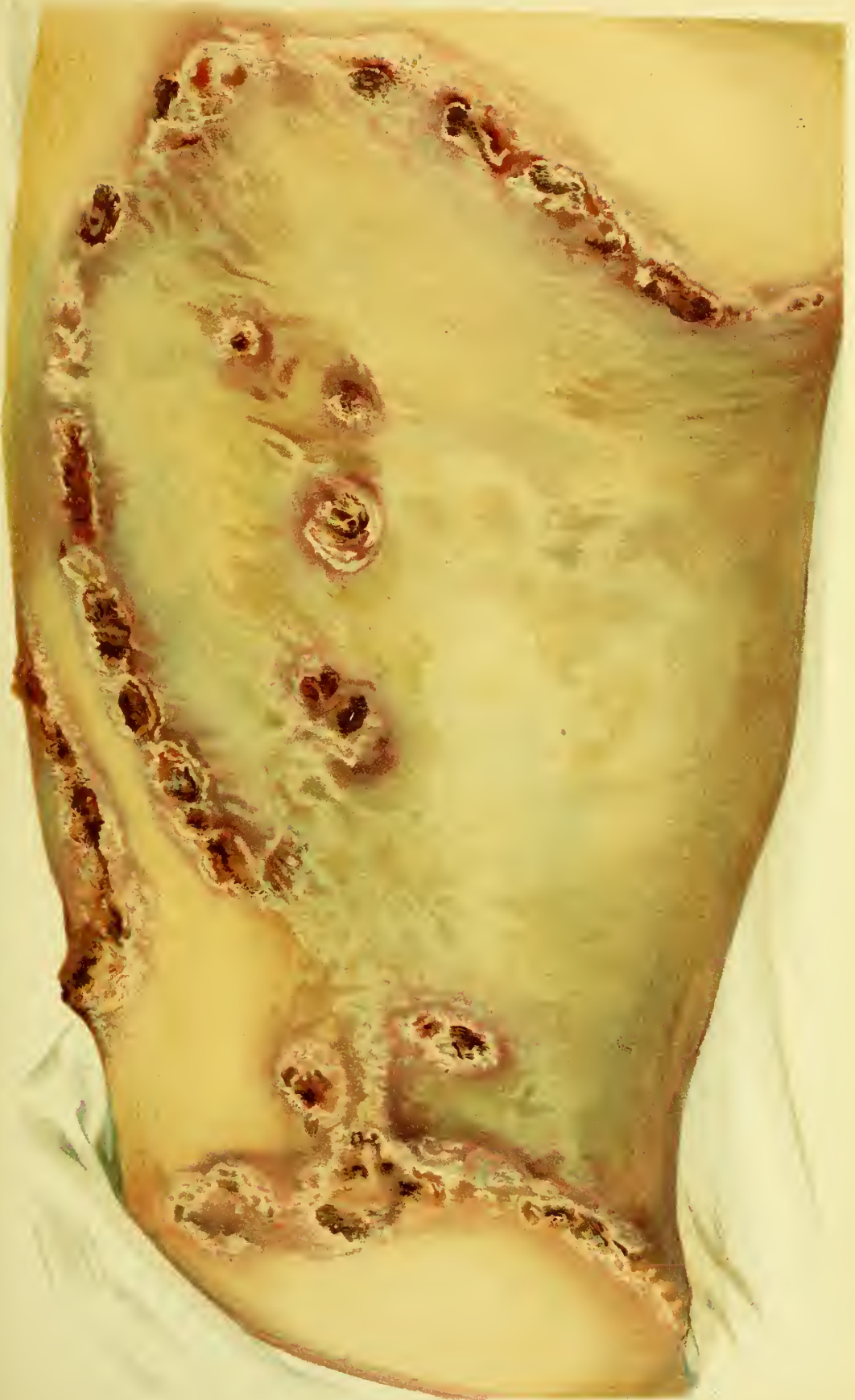



TAFEL 209.

Lupus vulgaris serpiginosus exulcerans femoris.





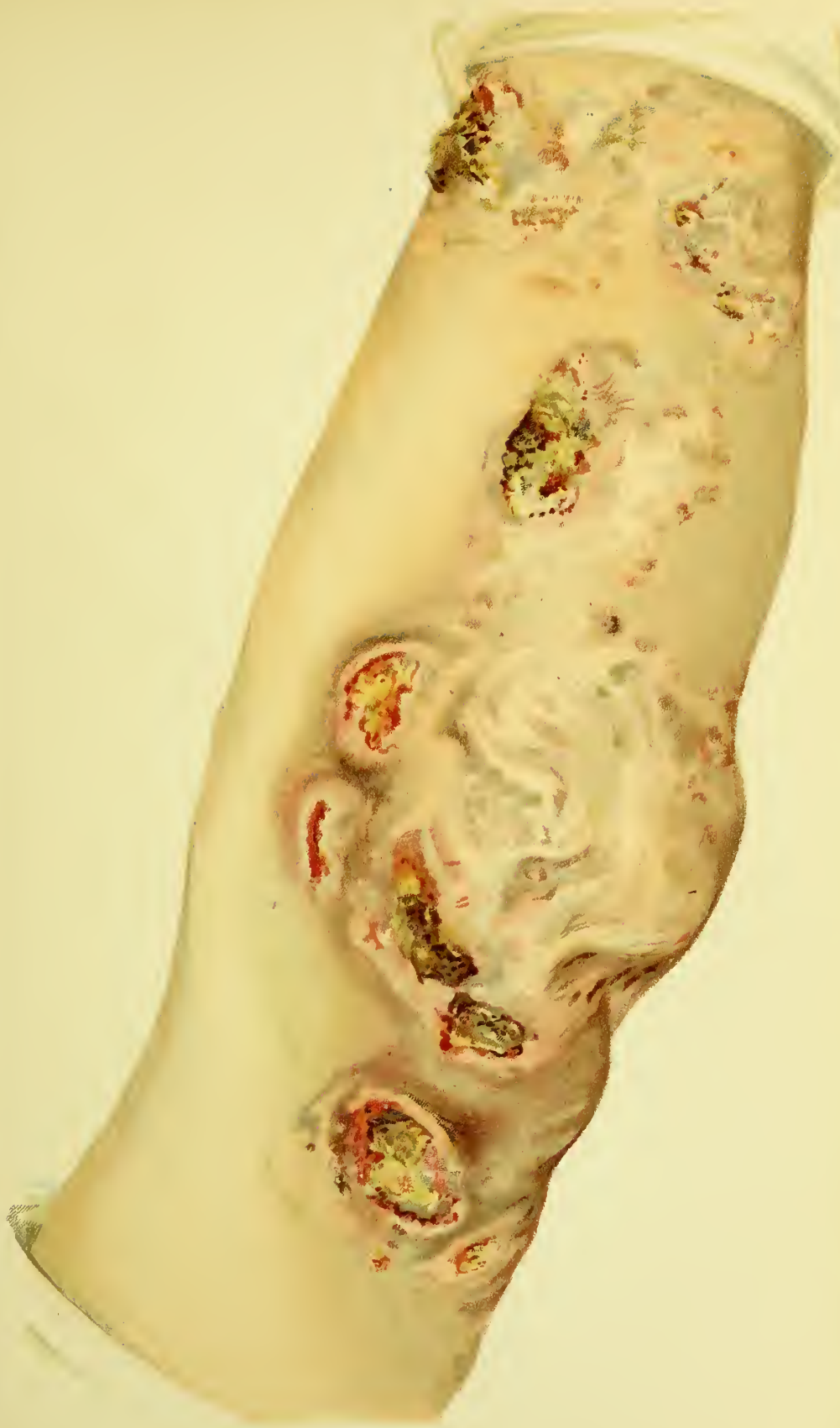




TAFEL 210.

Lupus vulgaris exulcerans et fungosus.



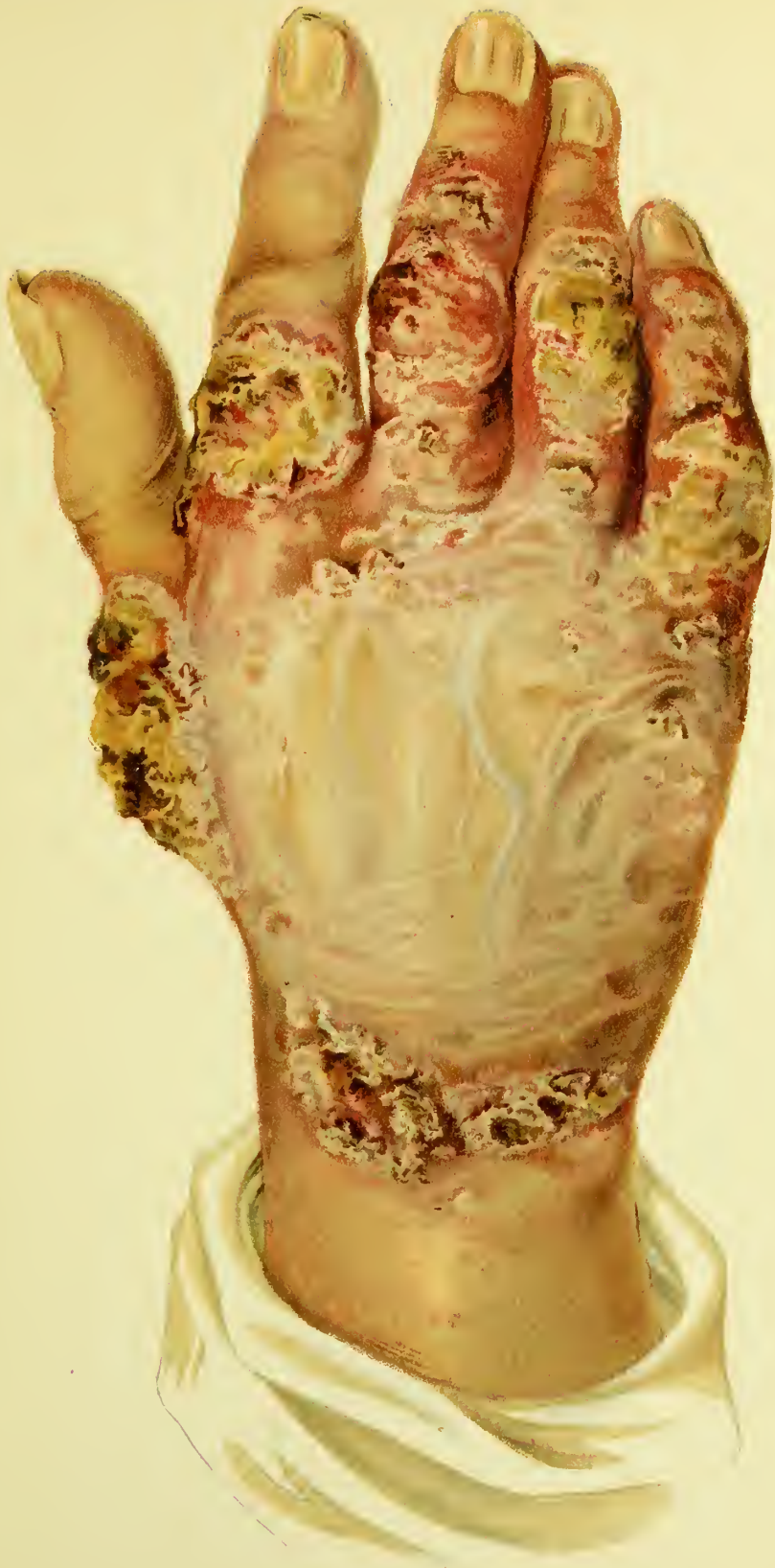



TAFEL 211.

Lupus vulgaris serpiginosus exulcerans et verrucosus  
manus.





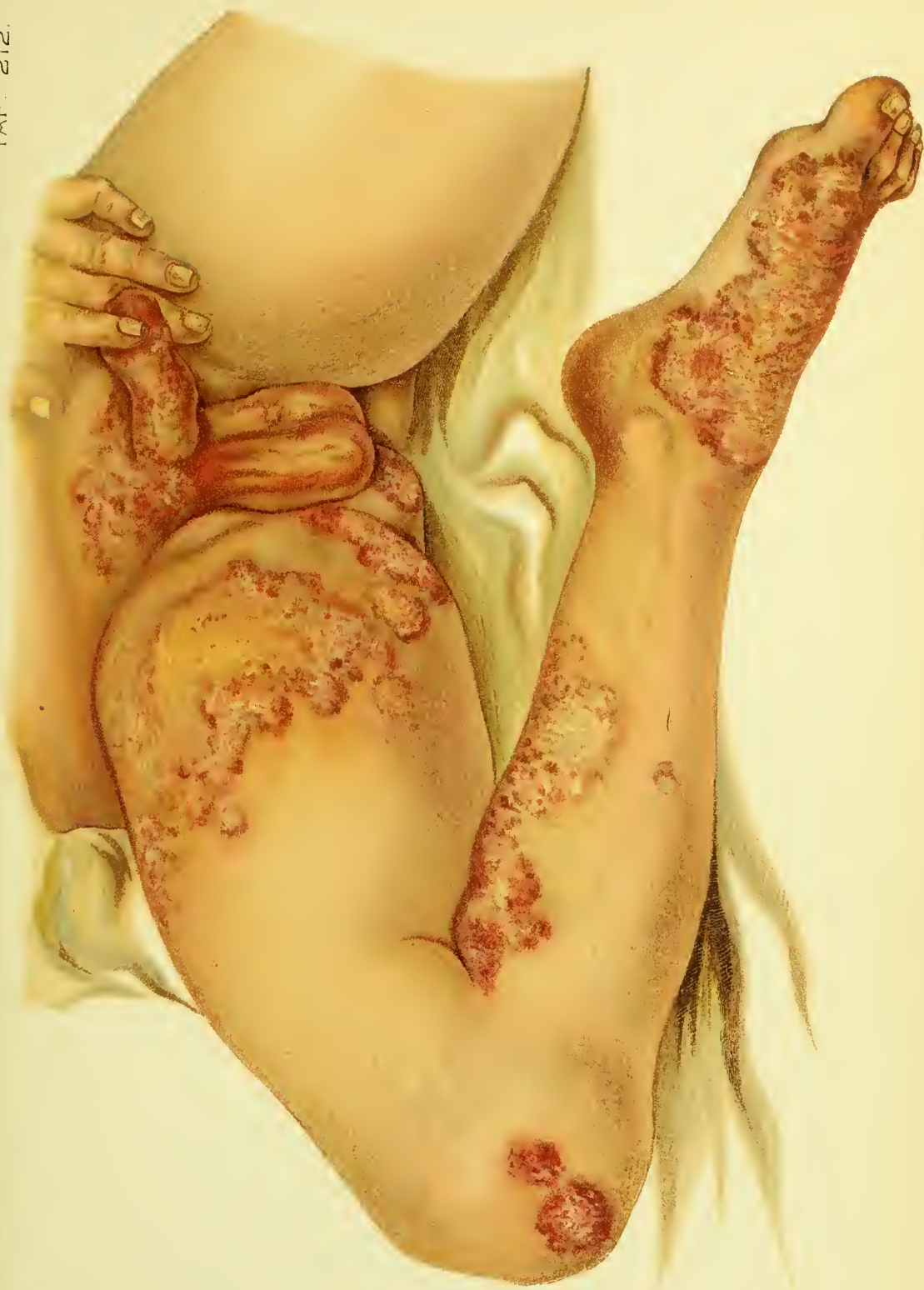



TAFEL 212.

Lupus vulgaris scroti, penis, inguinis, cruris, pedis dorsi.



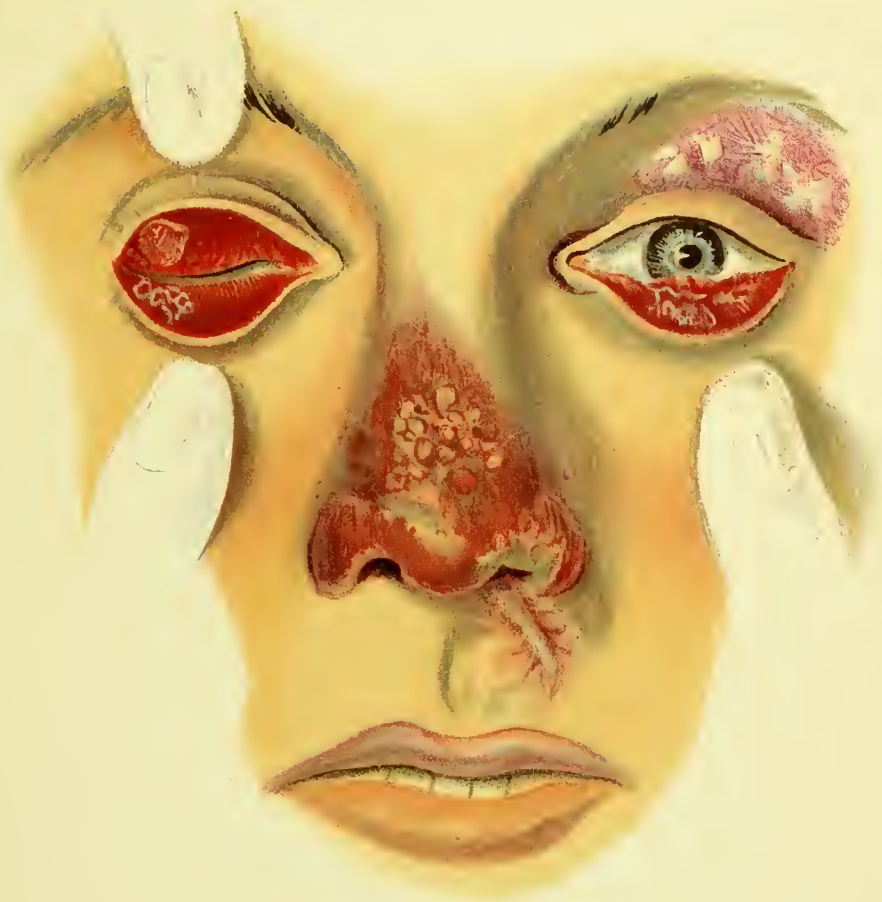



TAFEL 213.

Lupus vulgaris nasi et Conjunctivae oculi utriusque.





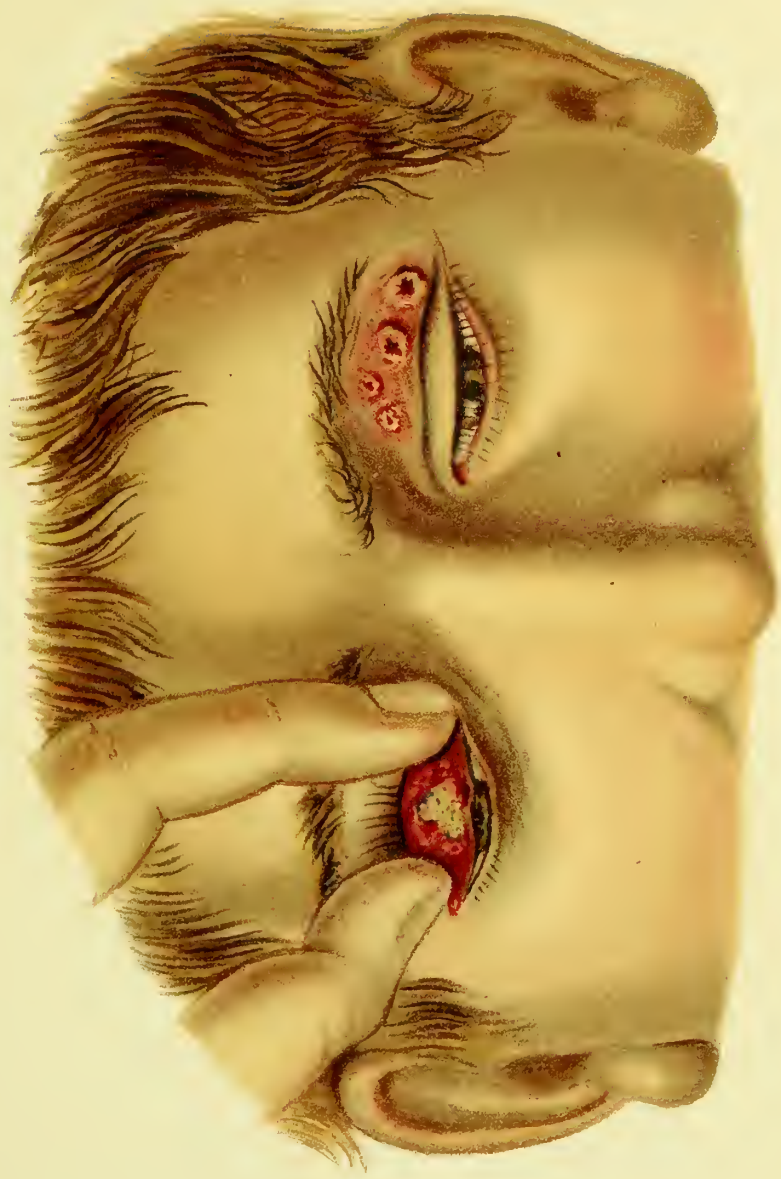



TAFEL 214.

Lupus vulgaris palpebrae et Conjunctivae palpebrae.



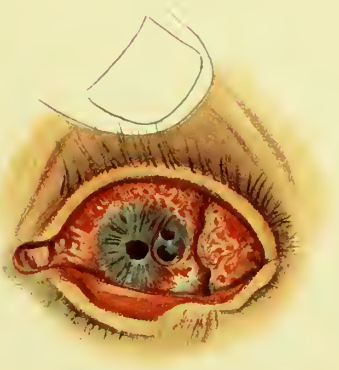
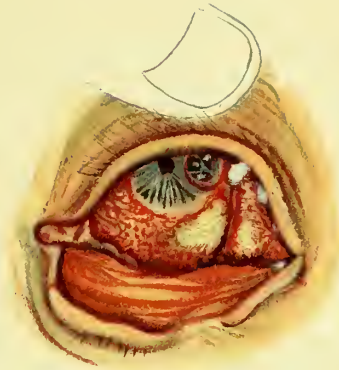



TAFEL 215.

Lupus vulgaris conjunctivae bulbi — Pannus luposus.





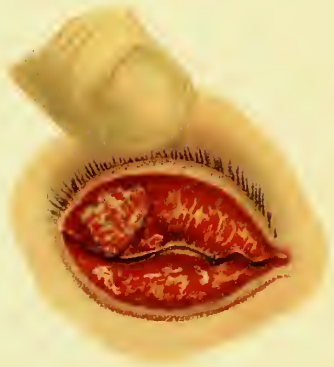
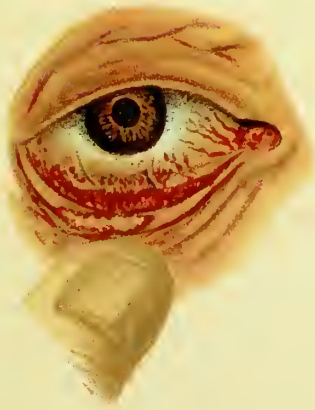
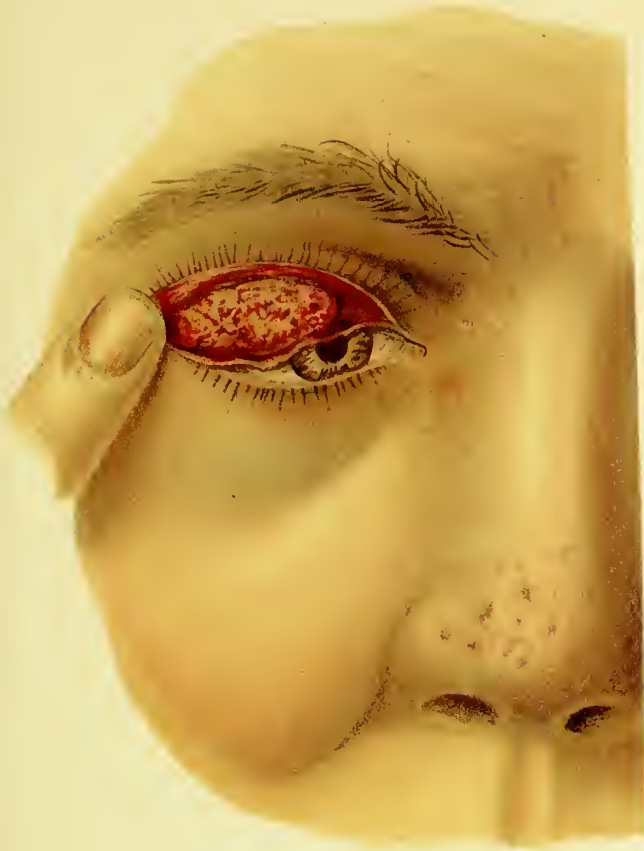

TAFEL 216.

Lupus vulgaris conjunctivae palpebrarum.



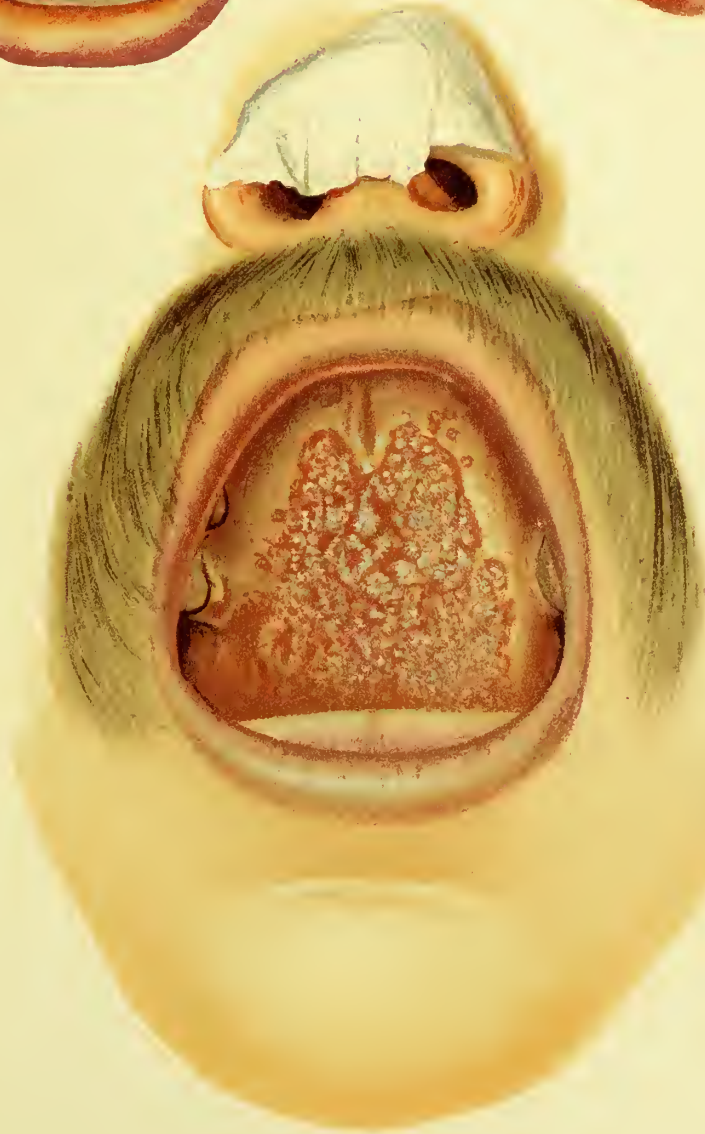
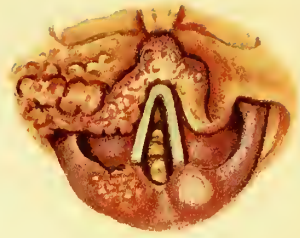
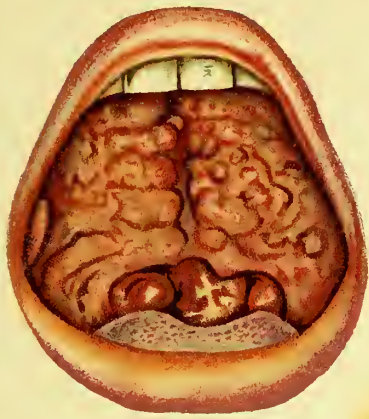

TAFEL 217.

Lupus vulgaris linguae, Epiglottidis, mucosae,  
arytaenoideae, palati duri.





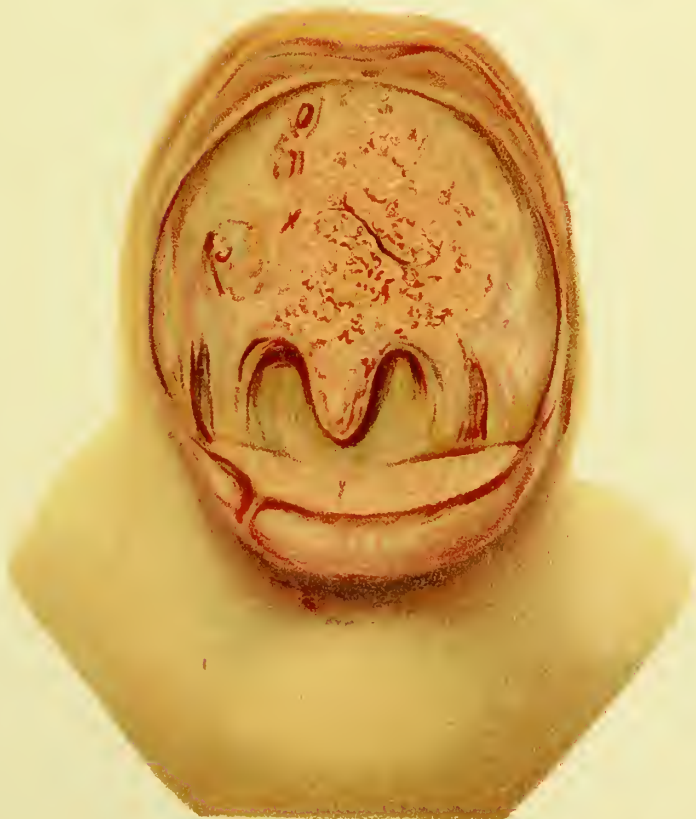
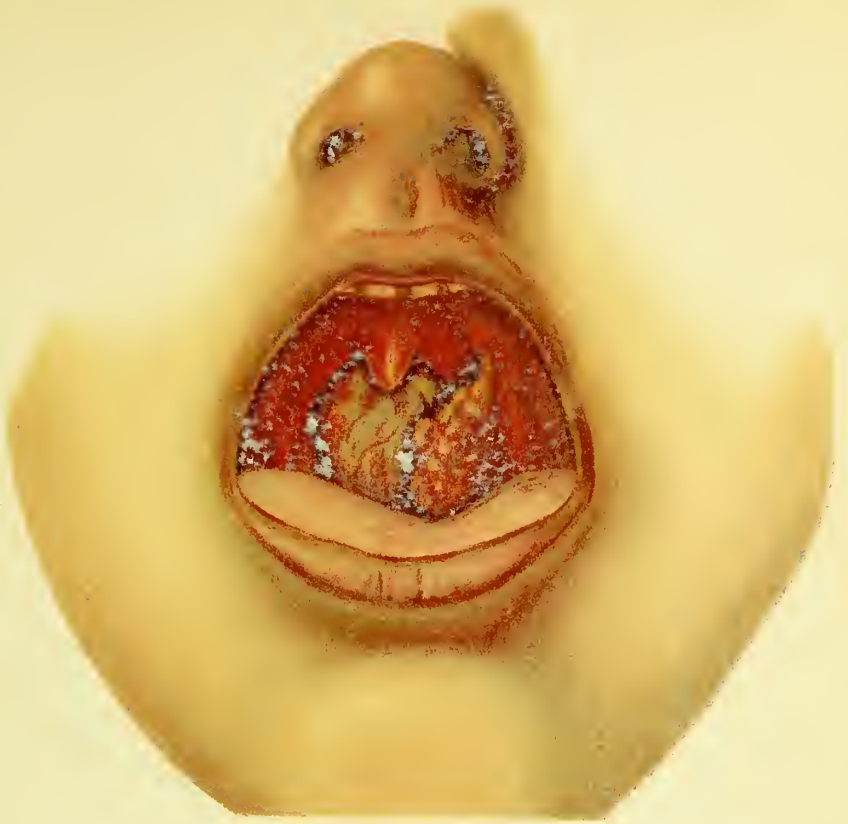


TAFEL 218.

Lupus vulgaris tonsillae mucosae, veli palati.



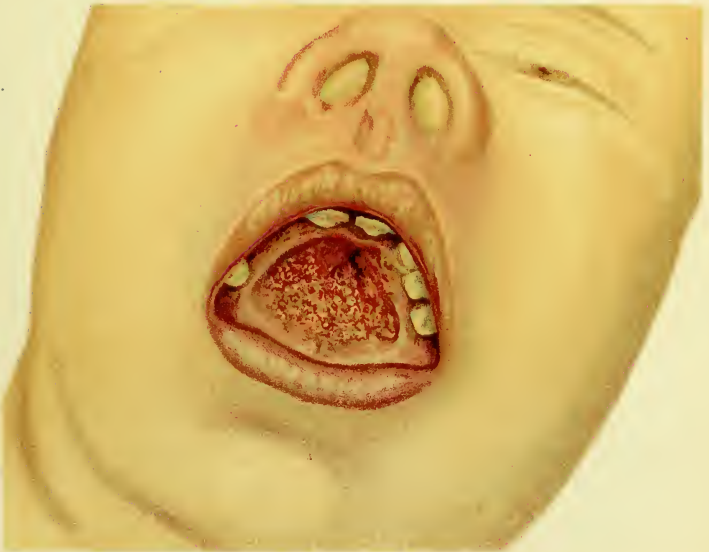
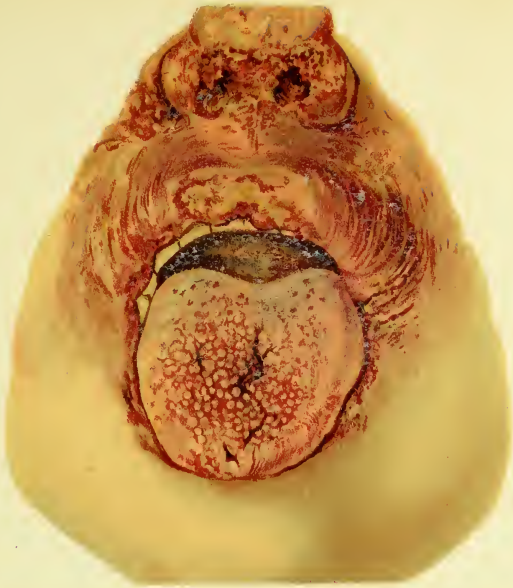


TAFEL 219.

Lupus vulgaris nasi, labii oris superioris, dorsi linguae,  
faciei inferioris linguae.









TAFEL 220.

**Melanosis Addison, Morbus Addisoni.**





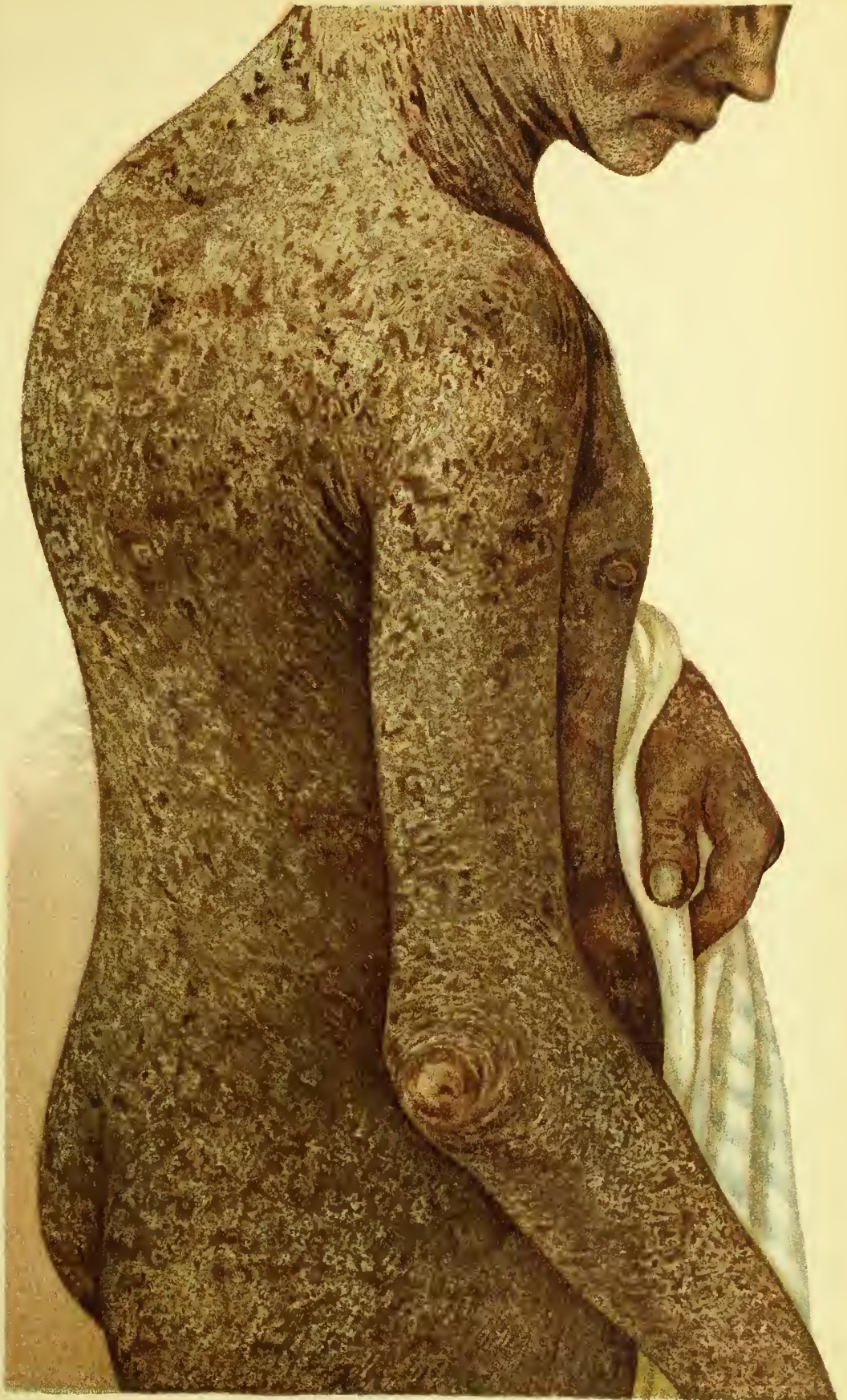

TAFEL 221.

Melanosis, Melasma e Pediculis vestimentorum (consequens  
Excoriationes e. pediculosi vestimentorum).





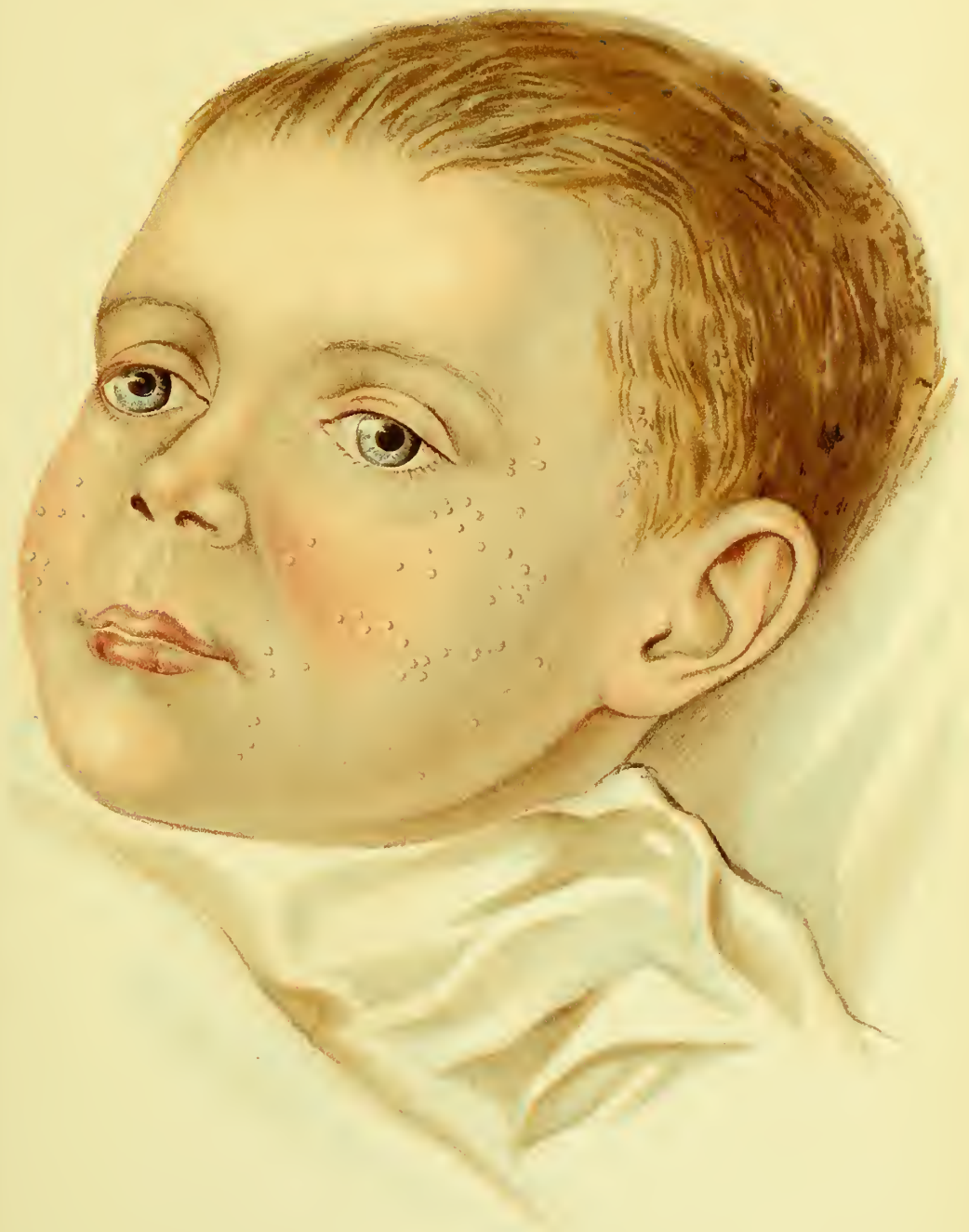





TAFEL 222.  
**Milium faciei.**



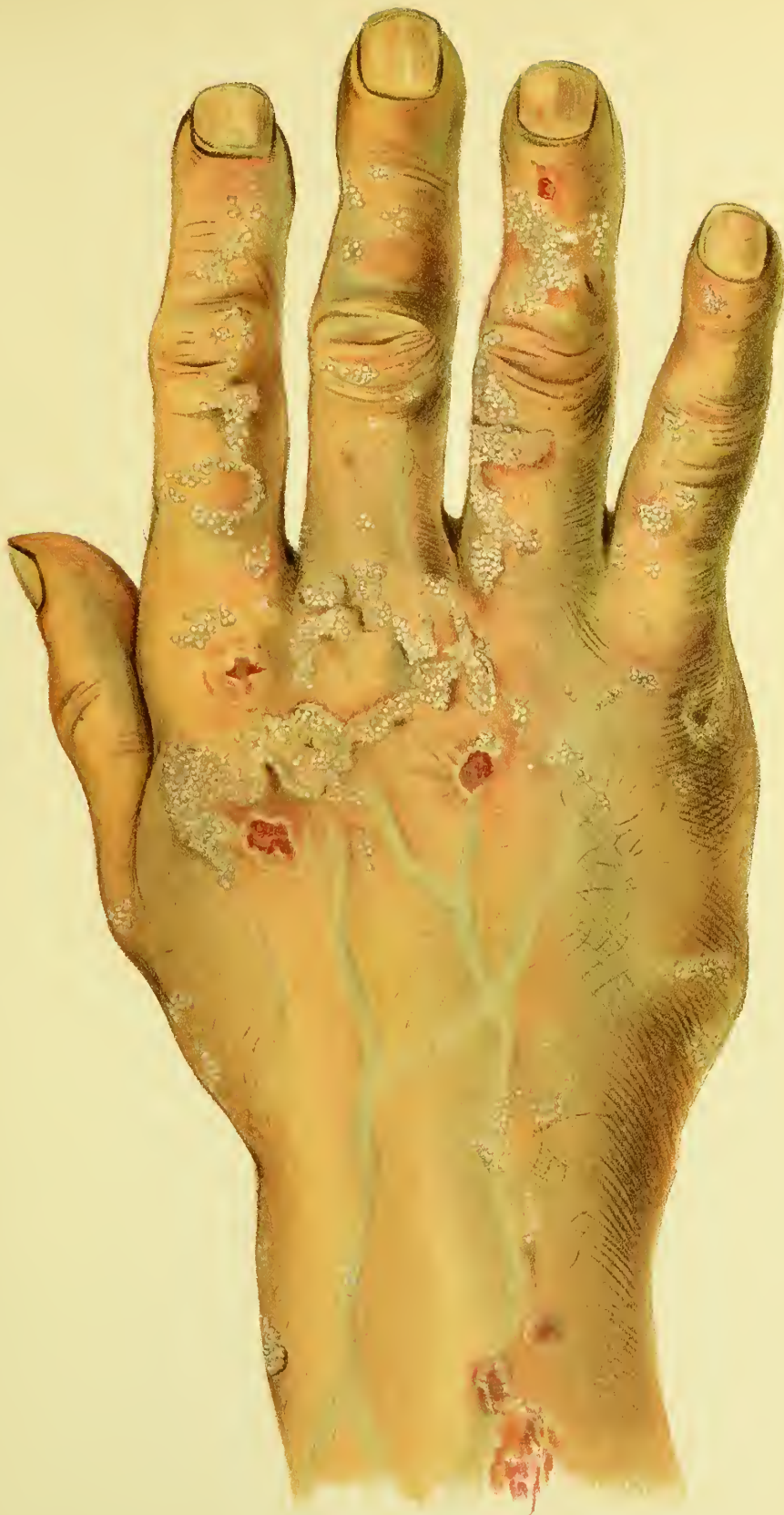



TAFEL 223.

*Milium aggregatum*, subacutum post Pemphigum.





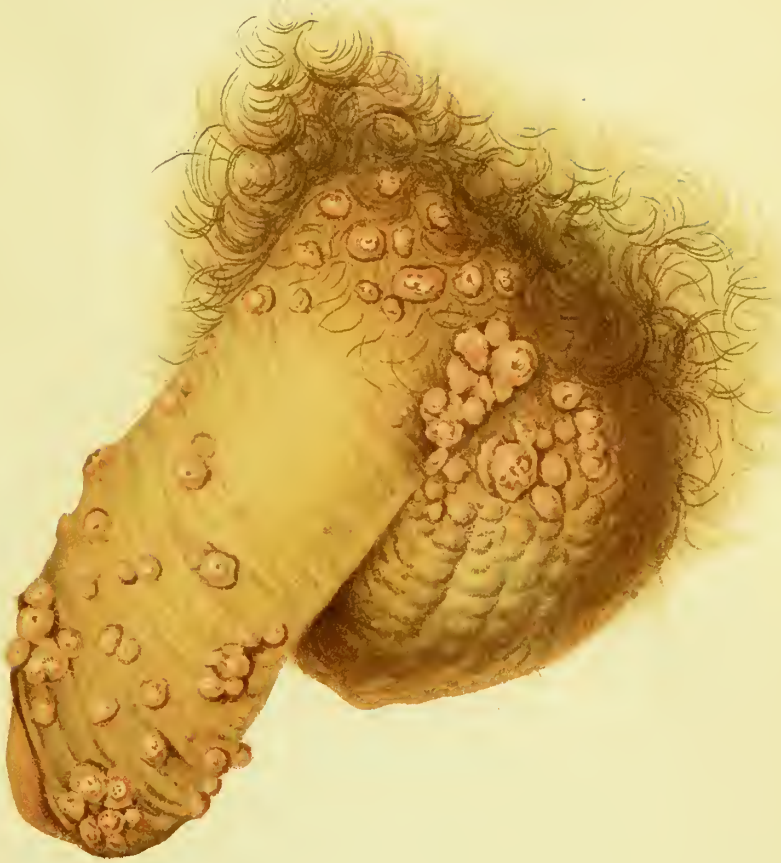



TAFEL 224.

Molluscum contagiosum penis (Moll. verrucosum — mihi).



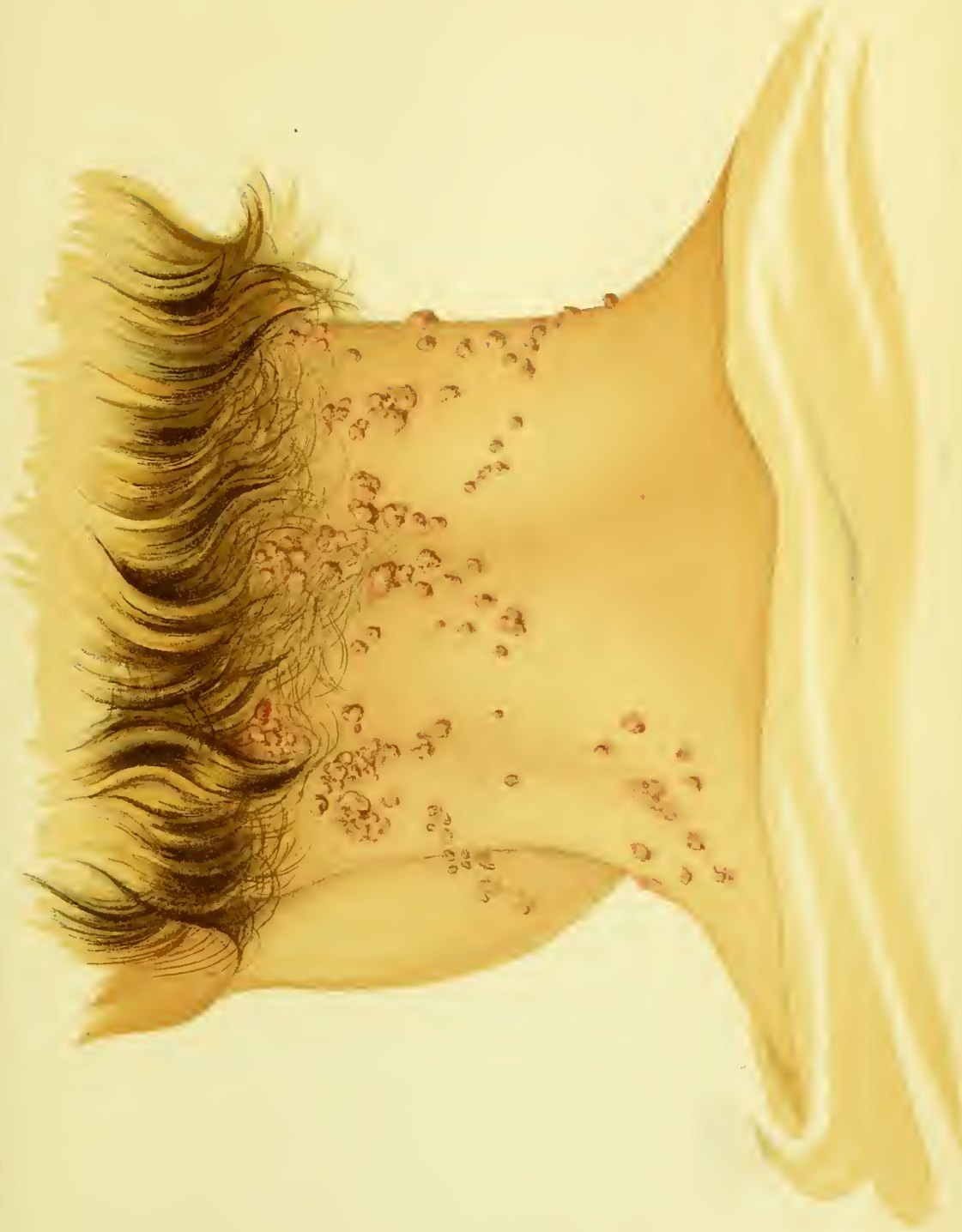



TAFEL 225.

**Molluscum contagiosum nuchae.**





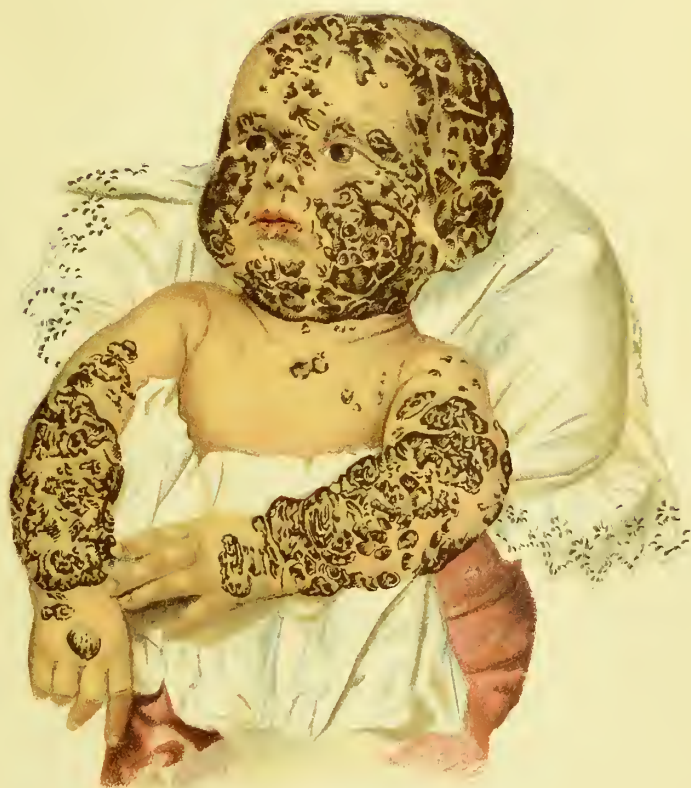



TAFEL 226.

Molluscum contagiosum giganteum — mihi — in infante.



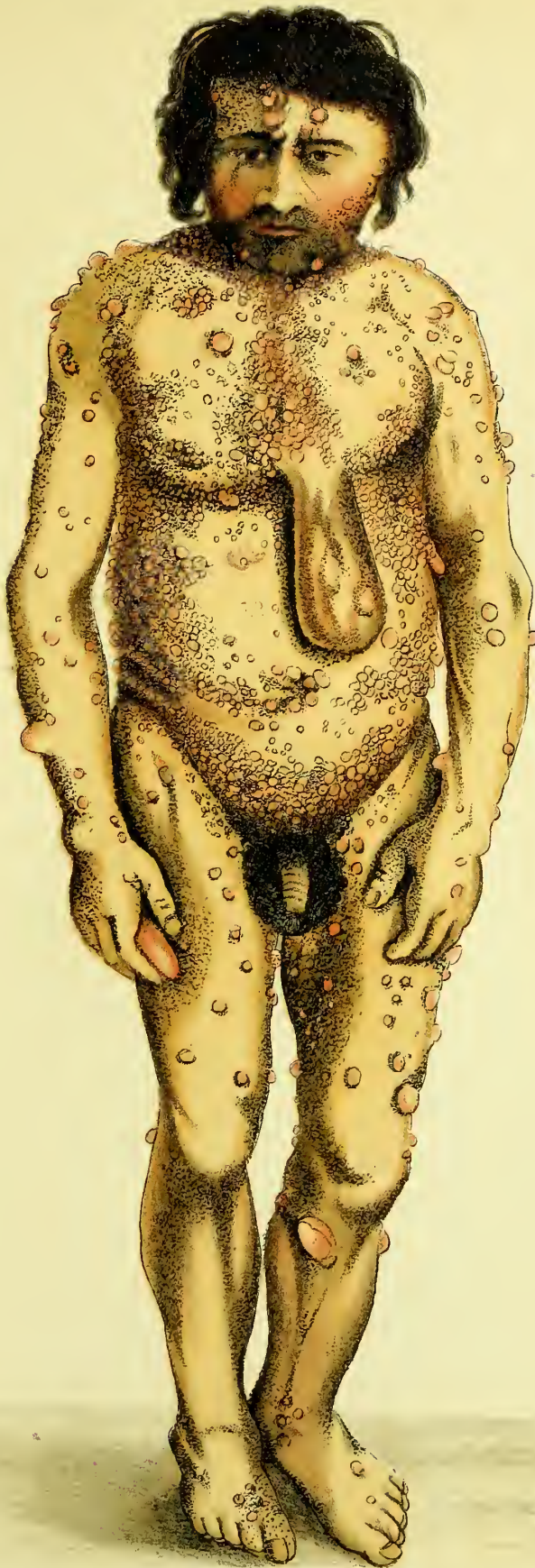




TAFEL 227.

**Molluscum fibrosum, Molluscosis.**





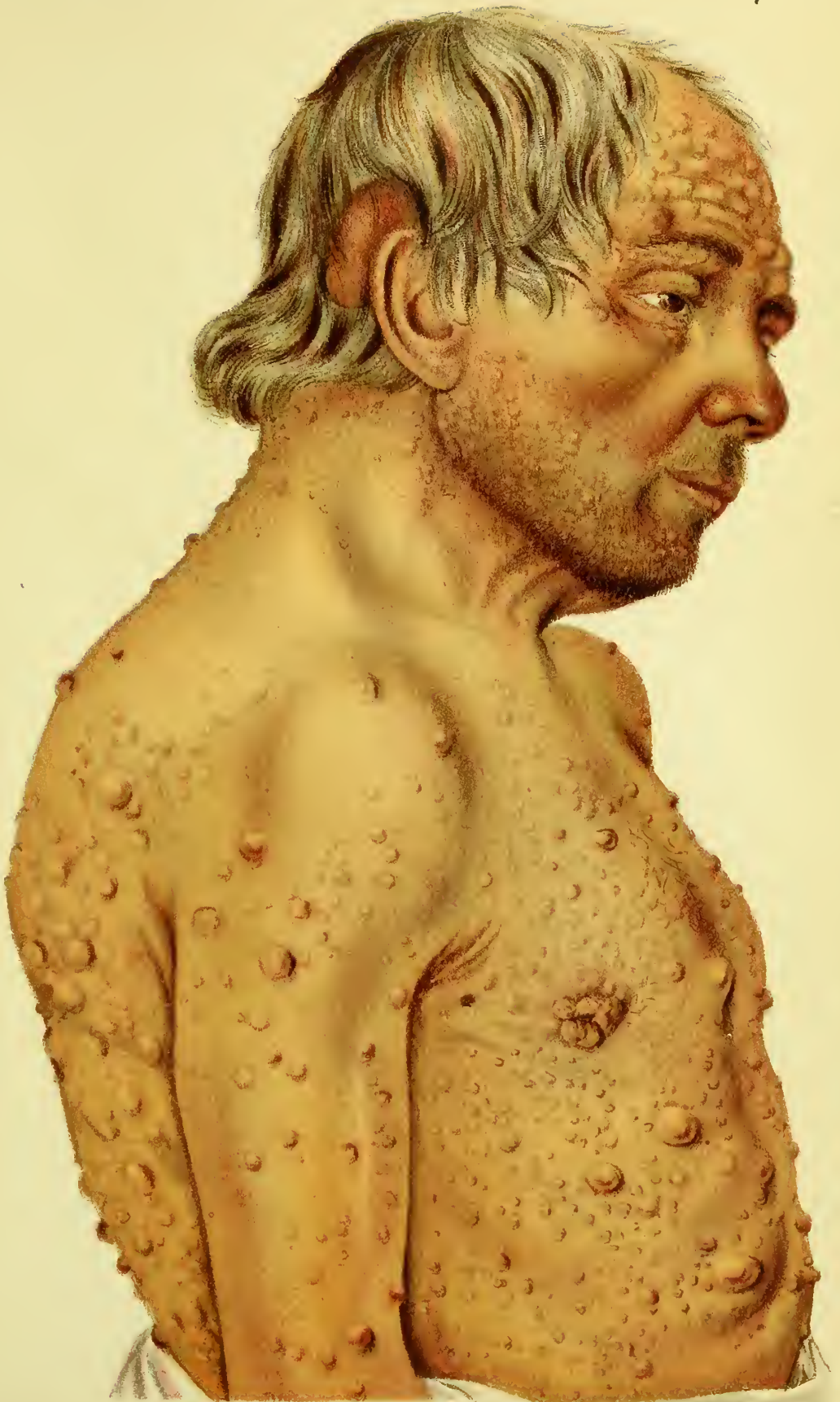



TAFEL 228.

**Molluscum fibrosum, Molluscosis.**



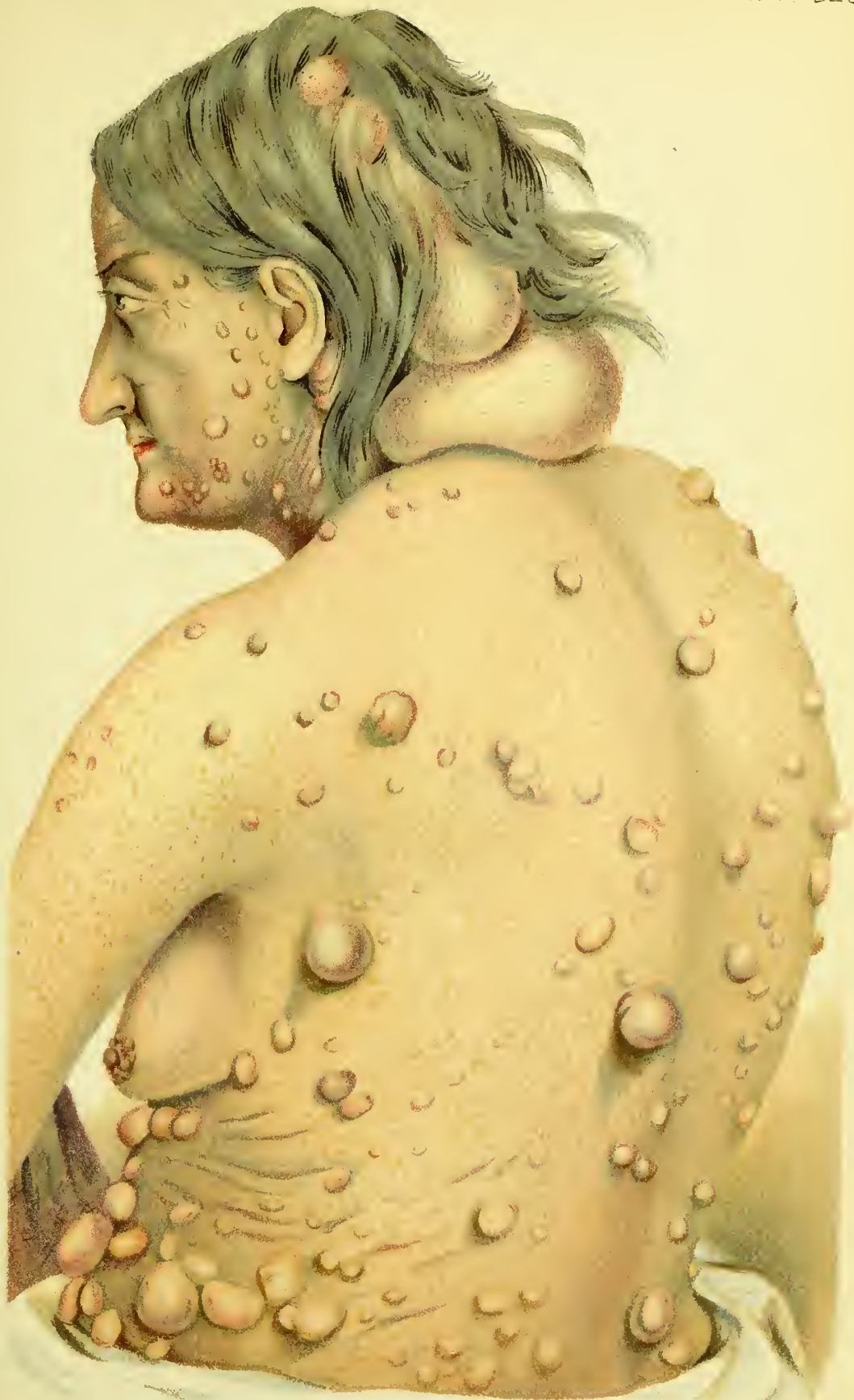



TAFEL 229.

**Molluscum fibrosum, Molluscosis.**










TAFEL 230.

Molluscum fibrosum pendulum (Lappen — Elephantiasis  
Esmarch u. Kullenkampf).





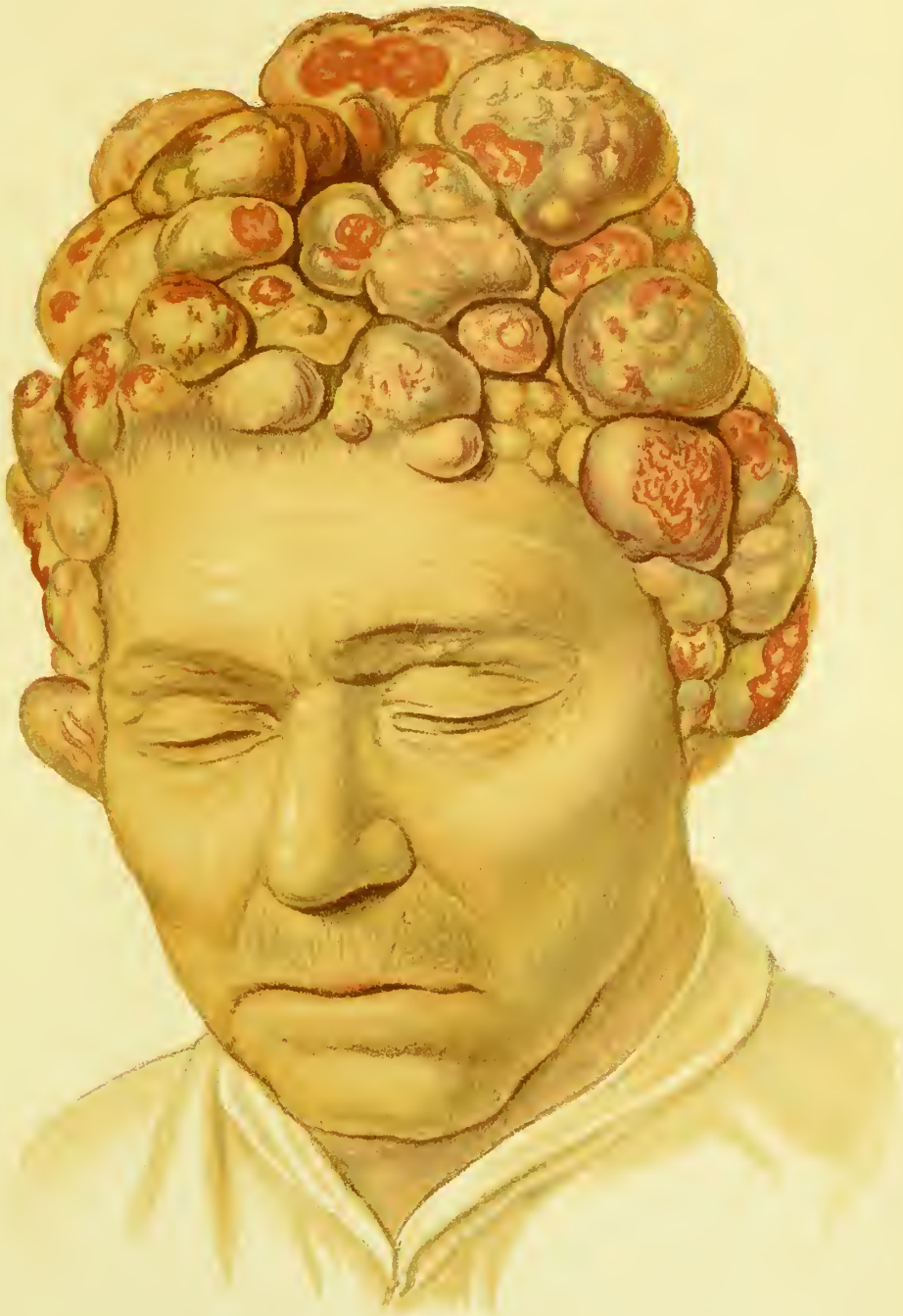



TAFEL 231.

Molluscum — Endothelioma congenitum.







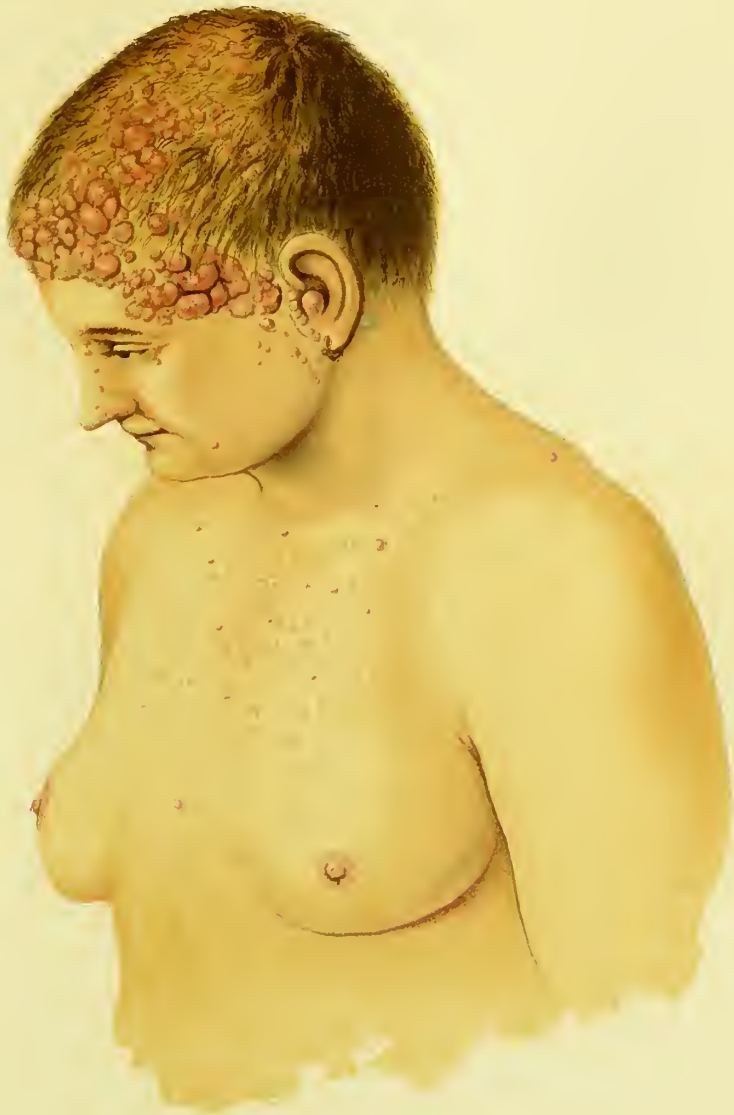

TAFEL 232.

**Molluscum — Endothelioma congenitum.**

(Tochter des Mannes Tafel 231.)



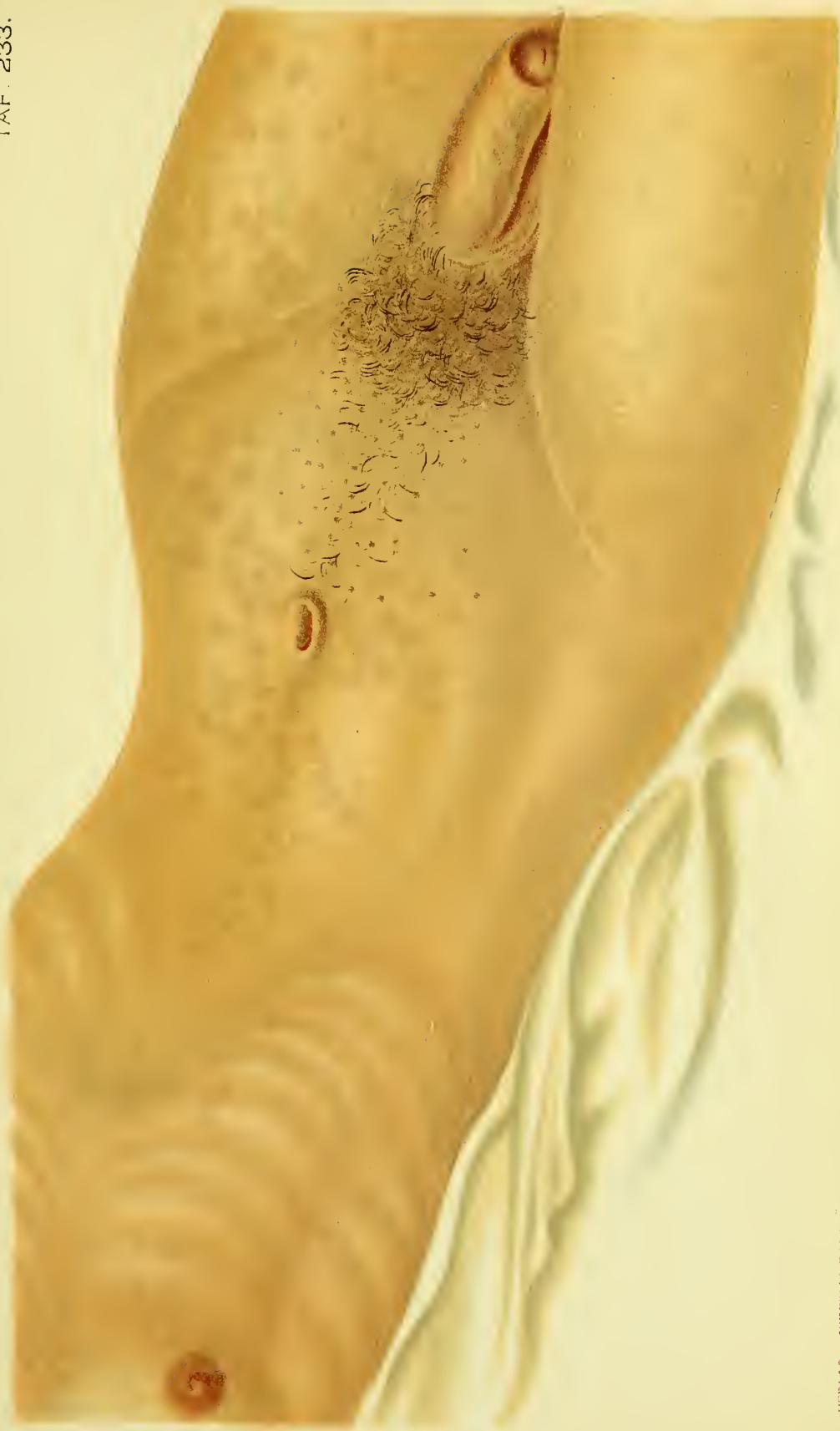



TAFEL 233.

Morpiones — Maculae coeruleae (Tâches bleues).





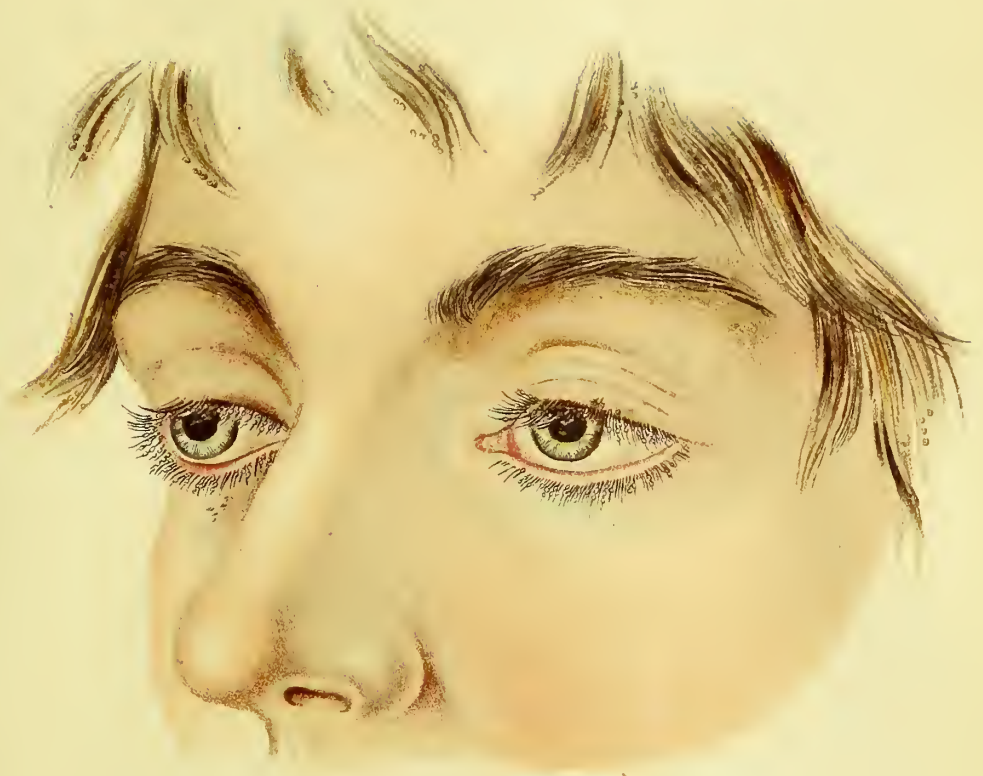



TAFEL 234.

**Morpiones ciliarum. — Phthiriasis oculi.**



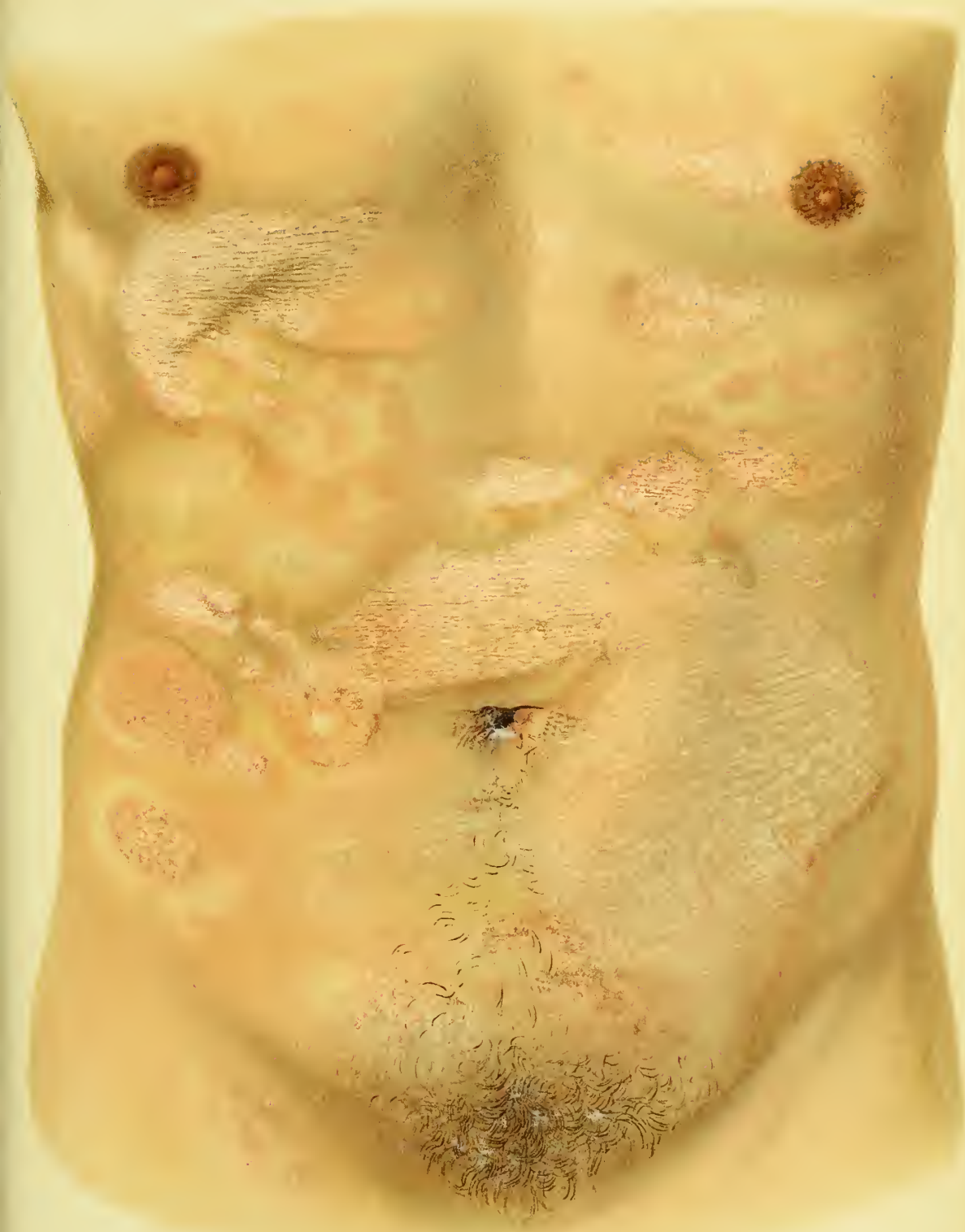



TAFEL 235.

Morphaea — Er. Wilson et mihi.





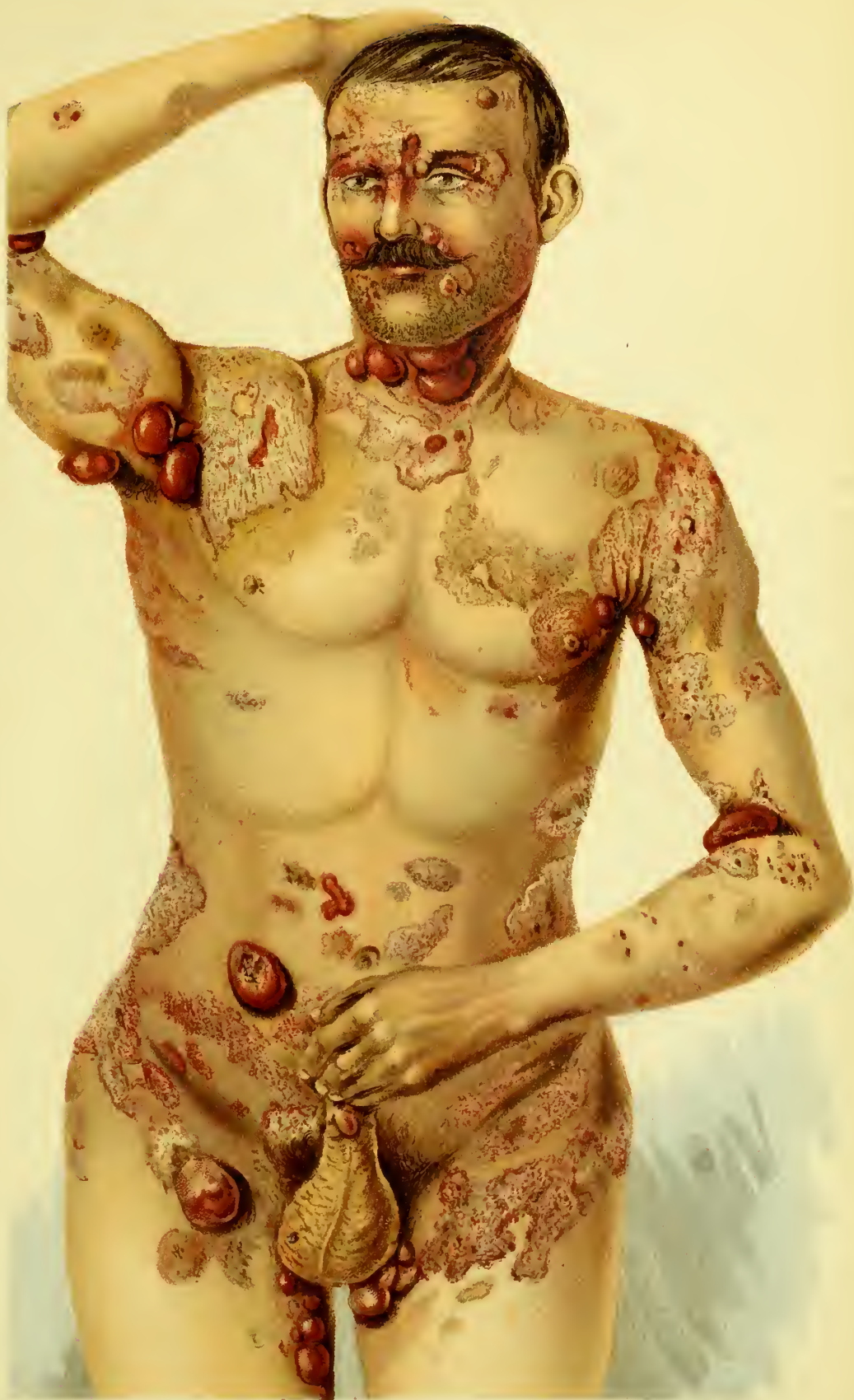



TAFEL 236.

**Mycosis fungoides, Stadium eczematosum et Stadium  
tumorum.**



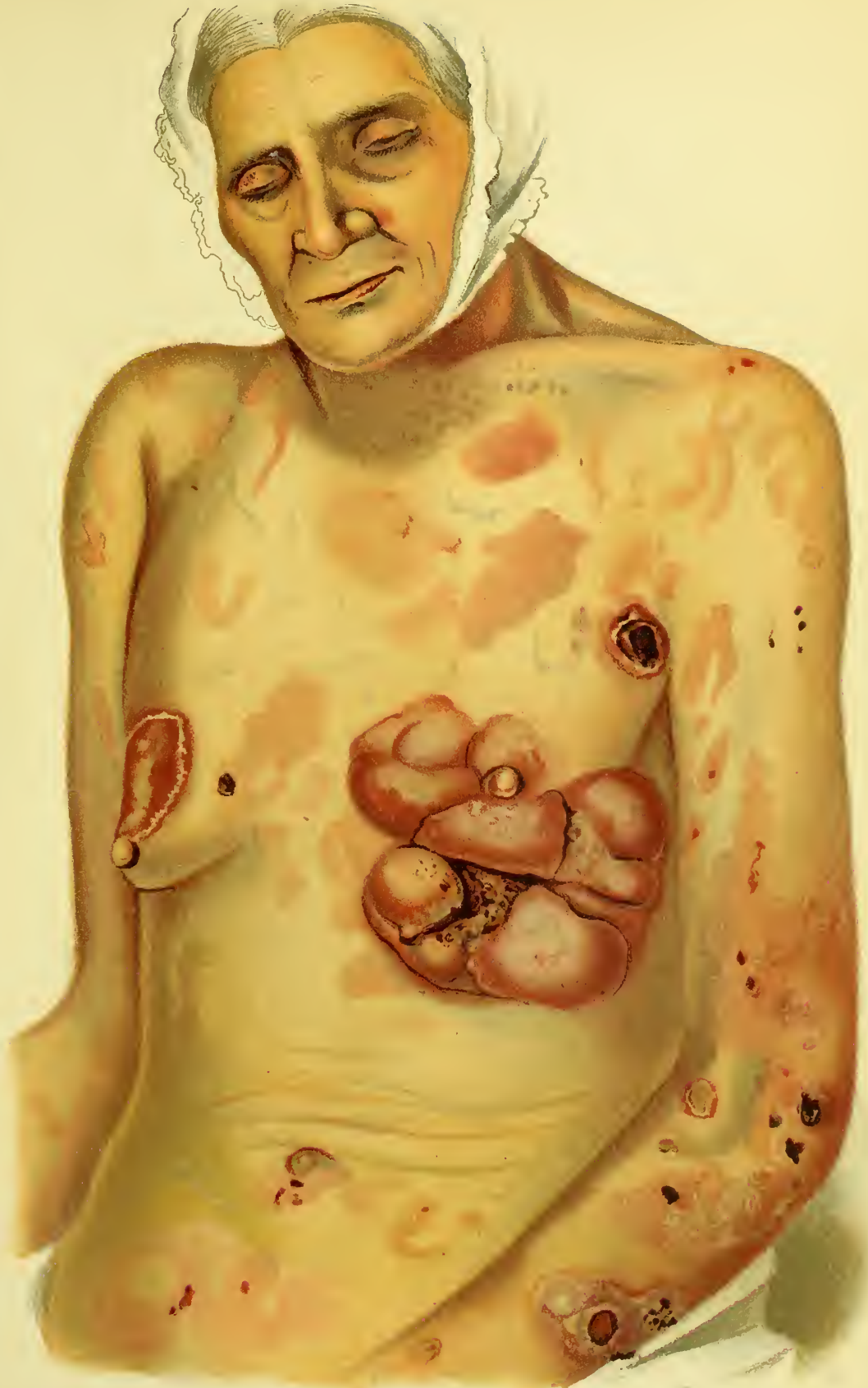



TAFEL 237.

**Mycosis fungoides, Stadium erythematosum et fungosum.**





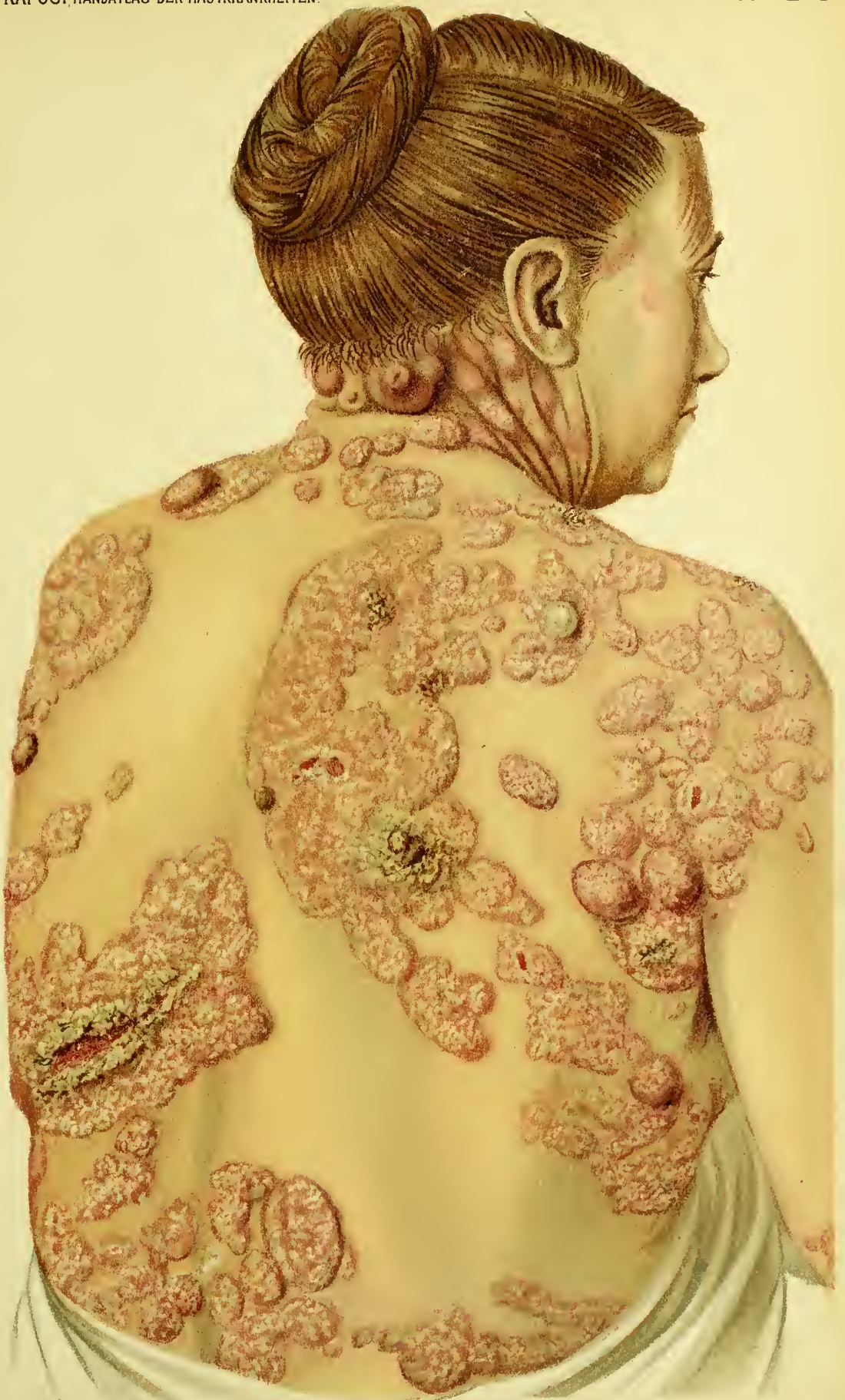



TAFEL 238.

**Mycosis fungoides, Stadium eczematosum et fungoso-  
ulcerosum.**





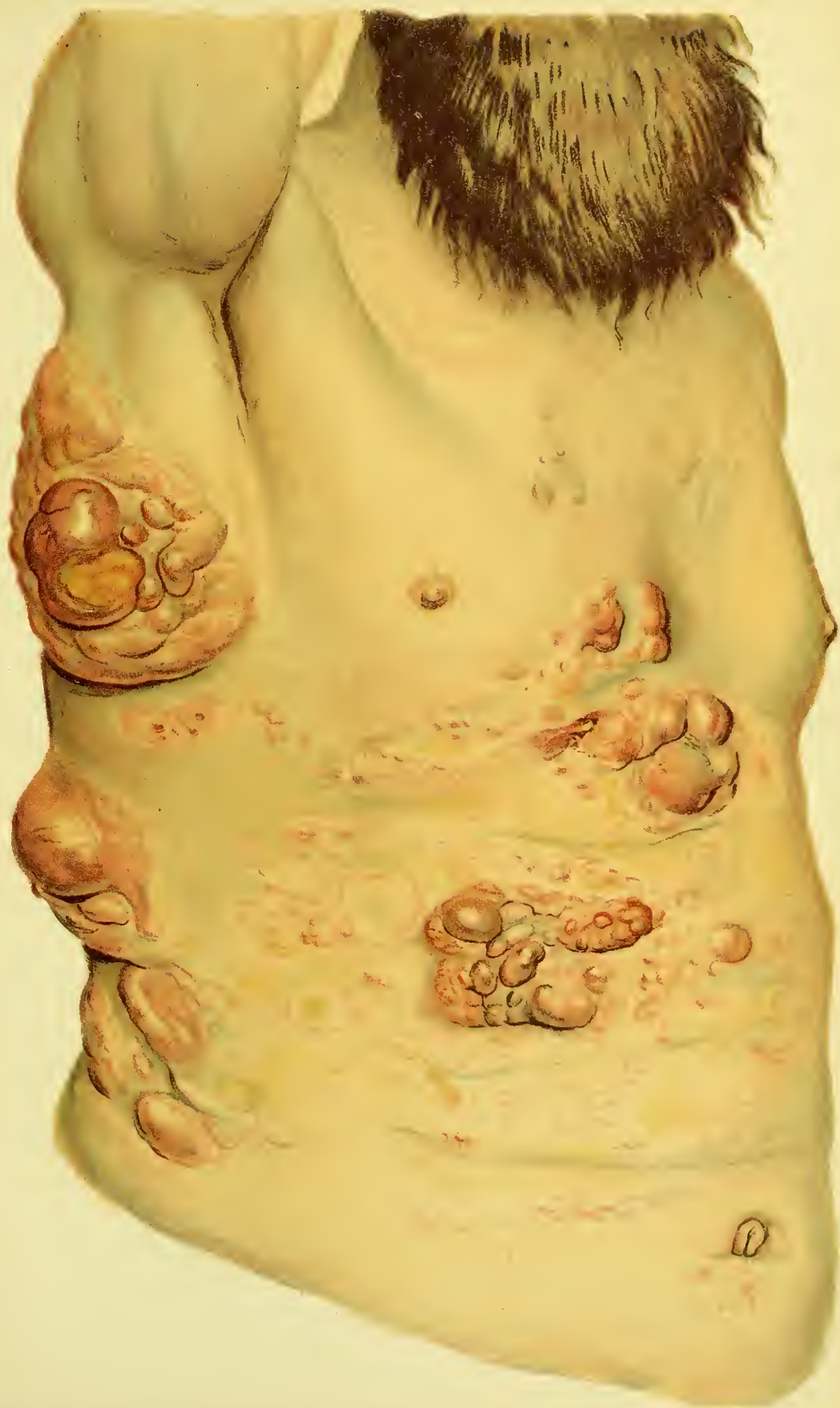

TAFEL 239.

**Mycosis fungoides — Stadium infiltrationis et fungosum.**











TAFEL 240.  
**Myomata cutis.**



















